

# Research Journal of Pharmaceutical, Biological and Chemical Sciences

## Study Of Clinical And Dermatoscopic Features Of Topical Steroid Application On Face- An Observational, Cross-Sectional Study.

Saema Nizam<sup>1</sup>, and VK Garg<sup>2\*</sup>.

<sup>1</sup>3rd year PG in Dermatology, Venereology and Leprosy, Santosh Deemed to be University, Ghaziabad, Uttar Pradesh, India.

<sup>2</sup>Professor and HOD, Dept. of Dermatology, Venereology and Leprosy, Santosh Deemed to be University, Ghaziabad, Uttar Pradesh, India.

### ABSTRACT

Topical corticosteroids (TCs) misuse on the face can lead to various adverse effects, prompting the need for effective management strategies post-withdrawal. This prospective study aimed to evaluate the clinical and dermatoscopic changes in patients following withdrawal of topical steroids over a three-month period. A total of 234 patients, predominantly females (85.04%), aged 18-60 years, were assessed for clinical symptoms and dermatoscopic features at baseline and monthly intervals post-withdrawal. Statistical analysis included Friedman tests for repeated measures. Significant reductions were observed in presenting complaints POST WITHDRAWAL such as redness (56.4% to 17.02%) and itching (55.85% to 25%) over three months ( $p < 0.001$ ). Cutaneous examination revealed decreases in erythema (86.7% to 32.4%) and hyperpigmentation (92.5% to 41%) ( $p < 0.001$ ). Dermatoscopic findings showed improvements in red diffuse areas and vascular abnormalities ( $p < 0.001$ ). Withdrawal of topical steroids resulted in noticeable clinical and dermoscopic improvements, highlighting the reversible nature of steroid-induced skin changes. Early recognition and cessation of misuse are crucial in managing and preventing prolonged adverse effects.

**Keywords:** topical corticosteroids, steroid withdrawal, dermoscopy, adverse effects

<https://doi.org/10.33887/rjpbcs/2024.15.4.42>

*\*Corresponding author*

## INTRODUCTION

The topical corticosteroids (TCs) are among the most commonly prescribed medication in an outpatient dermatology setting since they were first introduced in early 1950s. [1] The clinical effects are mediated by their anti-inflammatory, vasoconstrictive, anti-proliferative and immunosuppressive properties[2].The low-cost, easy availability (over-the-counter) and relatively fast relief acts as a driving force for the people to purchase TCs[3] .The misuse of TCs over face in India was first reported in 2006[4].The term ‘Topical Steroid Damaged Face’(TSDf) was coined in 2008 by Lahiri and was defined as “semi-permanent or permanent damage to the skin of the face precipitated by the irrational ,indiscriminate ,unsupervised or prolonged use of TCs resulting in a plethora of cutaneous signs and symptoms and psychological dependence on the drug.”

Unsupervised topical steroid application over face shows a prevalence of 90.5%.[3,5,18] Some of the cutaneous side effects of TCs are acne, telangiectasia, atrophy, hypopigmentation and hyperpigmentation, perioral dermatitis, atrophy, erythema, melasma, photosensitivity and hypertrichosis[5-7]. Dermatoscopy is an in-vivo, non-invasive imaging technique which has been recently used to visualize surface and subsurface structures and features in many dermatological conditions which are not visible to naked eyes. The dermatoscopic features of topical steroid application over face were first reported in 2018[8]. Dermatoscopy was said to help dermatologists in multitude of ways from confirming the diagnosis to differentiating from other causes of red face and predicting the approximate duration of TCs abuse [9].

## MATERIAL AND METHODS

The study was conducted at the Department of Dermatology, Santosh Medical College and Hospital, Ghaziabad, focusing on patients exhibiting clinical signs or symptoms suggestive of topical steroid abuse. From January 2023 to January 2024, a total of 234 consecutive patients aged 18 to 60 years were enrolled from the Dermatology Outpatient Department. These patients had a history of applying topical corticosteroids (TCs) to the face for more than two weeks. Prior to inclusion, all participants provided informed consent. Inclusion criteria for the study involved patients aged 18 to 60 years who had applied topical corticosteroids (TCs) to the face for more than two weeks. Participants needed to show clinical signs or symptoms suggestive of steroid abuse, such as erythema, hyperpigmentation, acneiform eruptions, or skin thinning. The patients must have visited the Dermatology Outpatient Department during the study period from January 2023 to January 2024 and provided informed consent.

Exclusion criteria included patients using TCs for medically prescribed conditions such as psoriasis or eczema, individuals with a history of systemic steroid use, or those using other topical agents concurrently. Patients with underlying skin disorders unrelated to TCs, those unwilling to consent, and those with incomplete clinical records were also excluded from the study.

Detailed demographic information was systematically collected using a predefined proforma during each patient's initial visit. A structured questionnaire was administered to gather data on the history of topical steroid use, including duration of application, specific steroid used, indication for use, source of information, and any reported adverse effects. Concurrently, cutaneous examinations were conducted to document clinical features such as erythema, telangiectasia, hyperpigmentation, hypopigmentation, atrophy, white hair, scaling, pustules, and hypertrichosis. Photographs were taken to complement these findings.

Furthermore, all enrolled patients underwent thorough dermatoscopic examinations using a 3-Gen Dermlite-4 dermatoscope, under both polarized and non-polarized light, at the time of enrolment and subsequently at monthly follow-up visits over the next three months. This comprehensive approach aimed to systematically evaluate and monitor any dermatoscopic changes associated with prolonged topical steroid use on the face.

## RESULTS

In our study out of 234 patients of topical steroid application on face, 35 (14.96%) were male and rest 199 (85.04%) were female. Age between 18-30 years comprised of largest group (52.56%) of all cases; followed by 31-40 years (31.62%), 41-60 years (15.38%).

**TABLE 1: Comparison Of Presenting Complain After Steroid Withdrawal At The Interval Of 1<sup>st</sup> Day, 1<sup>st</sup>, 2<sup>nd</sup> And 3<sup>rd</sup> Month.**

Presenting Complaint	At first day (n=188)	At 1st month (n=188)	At 2nd month (n=188)	At 3rd month (n=188)	p-value#
Redness	106 (56.4%)	58 (30.85%)	49 (26%)	32 (17.02%)	<.001
Itching	105 (55.85%)	102 (54.25%)	77 (41%)	47 (25%)	<.001
Burning	44 (23.4%)	28 (15%)	24 (12.8%)	18 (9.6%)	.31
Acne	46 (24.46%)	39 (20.74%)	31 (16.5%)	25 (13.3%)	.43
Hyperpigmentation	80 (42.5%)	76 (40.4%)	57 (30.4%)	51 (27.12%)	.052
Hypopigmentation	3 (1.6%)	3 (1.6%)	3 (1.6%)	3 (1.6%)	1
Photosensitivity	169 (89.9%)	164 (87.23%)	112 (59.6%)	93 (49.46%)	<.001

**Table 2: Comparison Of Cutaneous Examination Findings After Steroid Withdrawal At The Interval Of 1<sup>st</sup> Day, 1<sup>st</sup>, 2<sup>nd</sup> And 3<sup>rd</sup> Month Interval.**

Cutaneous Examination Feature	At first day (n=188)	At 1st month (n=188)	At 2nd month (n=188)	At 3rd month (n=188)	p-value#
Erythema	163 (86.7%)	92 (49%)	74 (39.4%)	61 (32.4%)	<.001
Hyperpigmentation	174 (92.5%)	135 (72%)	113 (60.1%)	77 (41%)	<.001
Hypopigmentation	10 (5.31%)	9 (4.78%)	9 (4.78%)	8 (4.25%)	.89
Hypertrichosis	96 (51.06%)	96 (51.06%)	96 (51.06%)	96 (51.06%)	1
Telangiectasia	155 (82.4%)	143 (76%)	97 (51.6%)	88 (46.8%)	<.001
Acne form eruptions	54 (28.7%)	33 (17.5%)	30 (16%)	25 (13.29%)	.10
Scaling	67 (35.6%)	48 (25.5%)	34 (18%)	25 (13.3%)	.005
Atrophy	49 (26.06%)	49 (26.06%)	43 (22.9%)	40 (21.27%)	.85
White hair	58 (30.85%)	58 (30.85%)	58 (30.85%)	58 (30.85%)	1

This table illustrates the findings of cutaneous examinations conducted over a period of three months following withdrawal of topical steroids in patients. Significant reductions were observed in features such as erythema, hyperpigmentation, telangiectasia, and scaling (all p-values < 0.005), indicating improvement or resolution of these cutaneous manifestations over time.

**Table 3: Comparison Of Dermatoscopic Examination Findings After Steroid Withdrawal At The Interval Of 1<sup>st</sup>, 2<sup>nd</sup> And 3<sup>rd</sup> Month Interval.**

Dermoscopic Examination Feature	At first day (n=188)	At 1st month (n=188)	At 2nd month (n=188)	At 3rd month (n=188)	p-value#
Red diffuse areas	174 (92.5%)	117 (62.23%)	101 (53.72%)	70 (37.23%)	<.001
Brown globules	177 (94.18%)	154 (81.9%)	129 (68.6%)	123 (65.4%)	<.001
Breaking of pseudo-reticular network	138 (73.4%)	102 (54.2%)	81 (43.08%)	66 (35.1%)	<.001
Hypertrichosis	125 (66.5%)	125 (66.5%)	125 (66.5%)	124 (66%)	1
Linear vessel	185 (98.4%)	139 (74%)	114 (60.6%)	99 (52.6%)	<.001
Serpentine vessel	90 (47.8%)	78 (41.5%)	65 (34.6%)	58 (30.85%)	.057
Polygonal vessel	83 (44.1%)	71 (37.7%)	60 (32%)	57 (30.3%)	.14
Y-shaped vessel	152 (80.8%)	128 (68.05%)	103 (54.8%)	87 (46.3%)	<.001
Papule/Pustules	54 (29.25%)	44 (23.4%)	38 (20.2%)	33 (17.5%)	.37
Desquamation	108 (57.44%)	80 (42.5%)	54 (28.7%)	36 (19.14%)	<.001
White Structureless Area	110 (58.5%)	95 (50.5%)	74 (39.36%)	63 (33.5%)	<.001
White hair	91 (48.4%)	91 (48.4%)	91 (48.4%)	91 (48.4%)	1

This table summarizes the findings of dermatoscopic examinations conducted over a span of three months on patients with previous topical steroid use. Significant reductions were observed in several dermatoscopic features over time, including red diffuse areas, brown globules, breaking of pseudo-reticular network, linear and Y-shaped vessels, desquamation, and white structureless areas (all p-values < 0.001), indicating improvement or resolution of these features after steroid withdrawal.

## DISCUSSION

The present study focused on the clinical and dermatoscopic manifestations observed in patients who had used topical corticosteroids (TCs) on their faces for prolonged periods, and the subsequent changes observed following withdrawal of these medications. Our findings highlight significant improvements in both cutaneous and dermatoscopic features over a three-month follow-up period.

The study included 234 patients, predominantly females (85.04%), reflecting a higher prevalence of topical steroid misuse among women. This observation is consistent with previous reports indicating a higher prevalence of cosmetic misuse of topical steroids among females in certain cultural contexts. The age distribution showed a peak in the 18-30 years group (52.56%), followed by 31-40 years (31.62%) and 41-60 years (15.38%), indicating that young adults constitute the majority affected by this issue. (10) At the onset of the study, common presenting complaints included redness (56.4%), itching (55.85%), and photosensitivity (89.9%), which are typical symptoms associated with topical steroid misuse. These symptoms significantly decreased over the three-month period post-withdrawal, underscoring the reversible nature of many steroid-induced adverse effects. For instance, redness reduced from 56.4% initially to 17.02% at three months, and itching similarly decreased from 55.85% to 25% by the end of the study period ( $p < 0.001$  for both).

Cutaneous examination revealed prominent initial features such as erythema (86.7%) and hyperpigmentation (92.5%), which also showed substantial improvement over time. Erythema decreased from 86.7% to 32.4% by the third month, and hyperpigmentation reduced from 92.5% to 41% (both  $p < 0.001$ ). This improvement suggests the skin's capacity for recovery once topical steroid use ceases, although some features like hypopigmentation and hypertrichosis showed minimal change, emphasizing their persistent nature post-withdrawal.

Dermatoscopic evaluations provided further insights, revealing significant reductions in red diffuse areas, brown globules, and vascular abnormalities (e.g., linear and Y-shaped vessels). These findings corroborate the clinical improvements observed and highlight the utility of dermatoscopy in objectively assessing steroid-induced skin changes. Notably, desquamation and white structureless areas also showed marked reductions over time, indicating gradual restoration of skin integrity ( $p < 0.001$  for all).

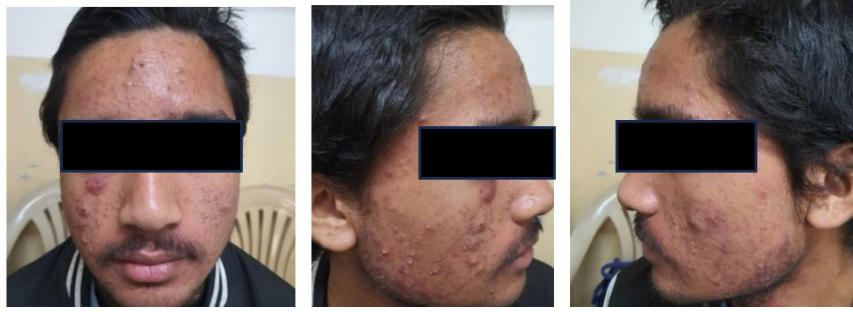The study underscores the importance of early recognition and cessation of topical steroid misuse to prevent prolonged adverse effects. Education and awareness programs targeting healthcare providers and the public are essential to mitigate the prevalence of this issue, particularly among young adults and women, who are more vulnerable.

Limitations of our study include its single-centre design and relatively short follow-up period of three months. Future studies could explore long-term outcomes beyond three months and include a broader demographic representation to validate our findings across different populations. Additionally, investigating the psychological impact and quality of life improvements post-steroid withdrawal would provide a comprehensive understanding of patient outcomes.

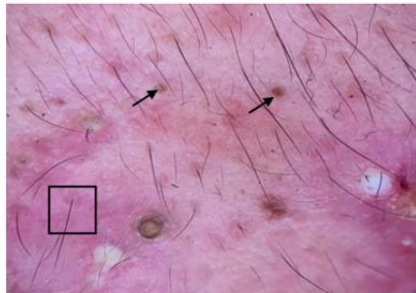
## CONCLUSION

In conclusion, our prospective study provides compelling evidence of the reversible nature of topical steroid-induced skin changes upon cessation of use. Significant improvements in clinical and dermatoscopic features underscore the importance of timely intervention and cessation of misuse. This study contributes valuable insights into the management and outcomes of topical steroid abuse, advocating for heightened awareness and early intervention strategies in clinical practice.

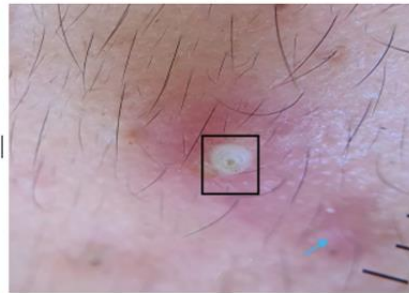



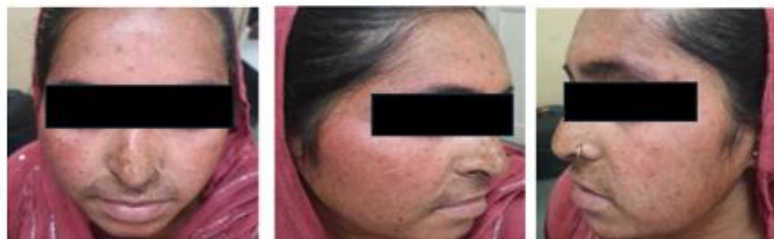**Figure 1a: Clinical findings of acne and erythema in 23 yrs old male patient using clobetasol propionate 0.05% cream for 1 month for treatment of acne.**




**Figure 1b: Dermatoscopic findings black arrows-follicular plugging (comedones); black box-red diffuse areas**



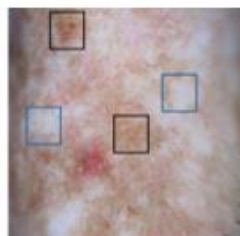**Figure 1c: Dermatoscopic findings blue arrows -papules; black box-pustules**



**Figure 2a: Clinical findings of hyperpigmentation, hypertrichosis, telangiectasias, erythema, and atrophy in 32 yrs old female patient after using betamethasone dipropionate .05% cream for 7 months**



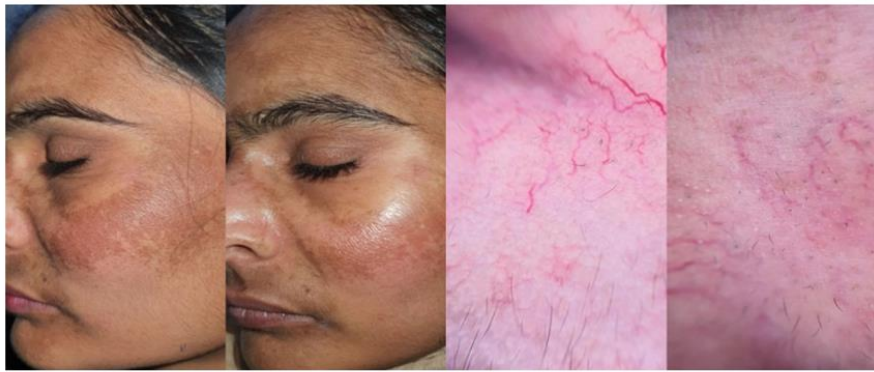**Figure 2b: Dermatoscopic findings-Blue box serpentine vessels; black box-polygonal vessels, yellow box-Y shaped vessel, white box-linear vessel**



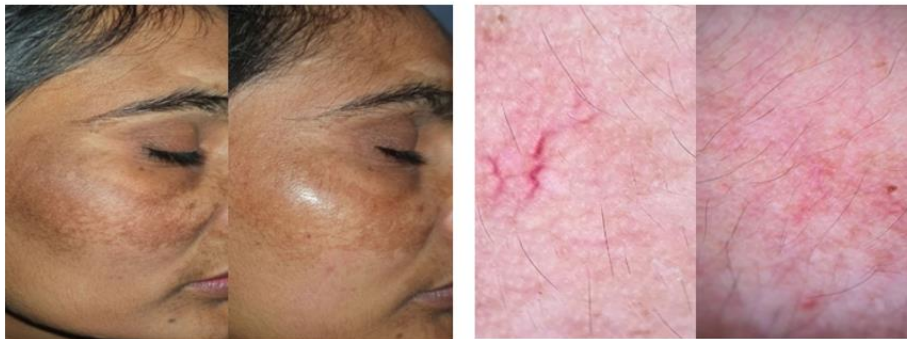**Figure 2d: Dermatoscopic findings-Blue arrow-white hair; black arrow-hypertrichosis**



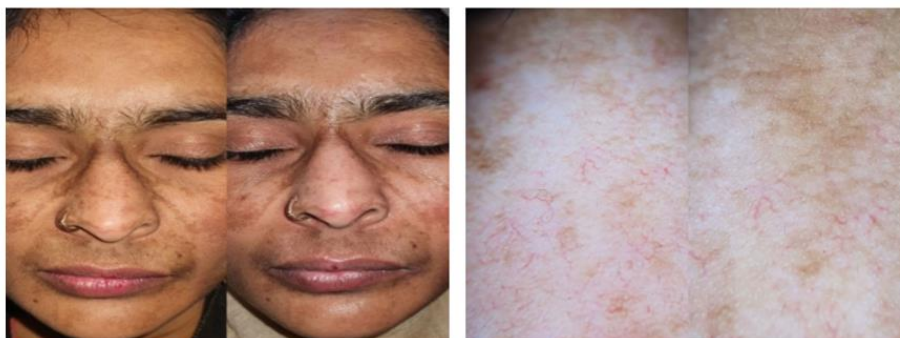**Figure 2c: Dermatoscopic findings-Blue box-white structureless areas; black box-brown globules**



**Figure 3a: Clinical and dermatoscopic images at first OPD visit (left) and 1 month follow up (right)**

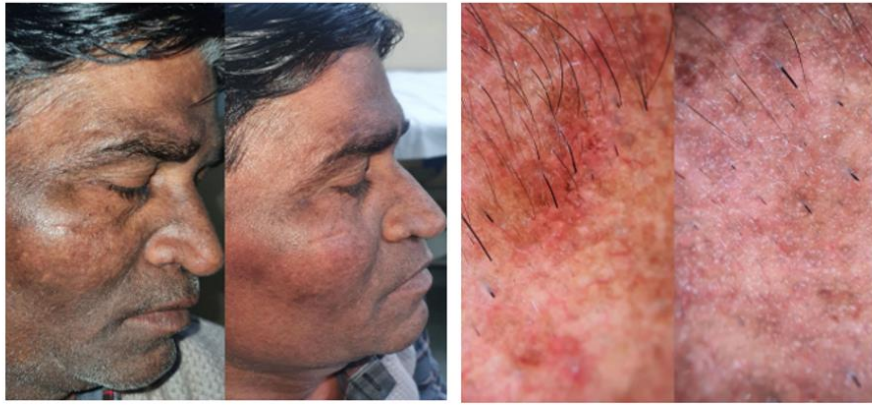

**Figure 3b: Clinical and dermatoscopic images at 1 month follow up (left) and 2 month follow up (right)**

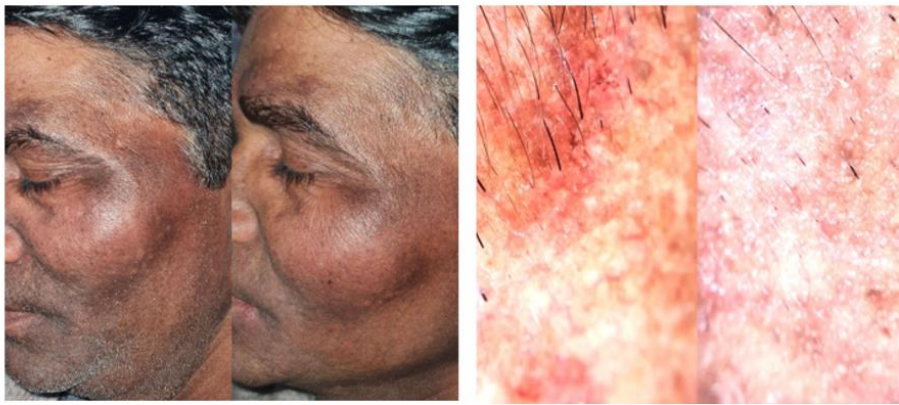

**Figure 3c: Clinical and dermatoscopic images at 2 month follow up (left) and 3 month follow up (right)**

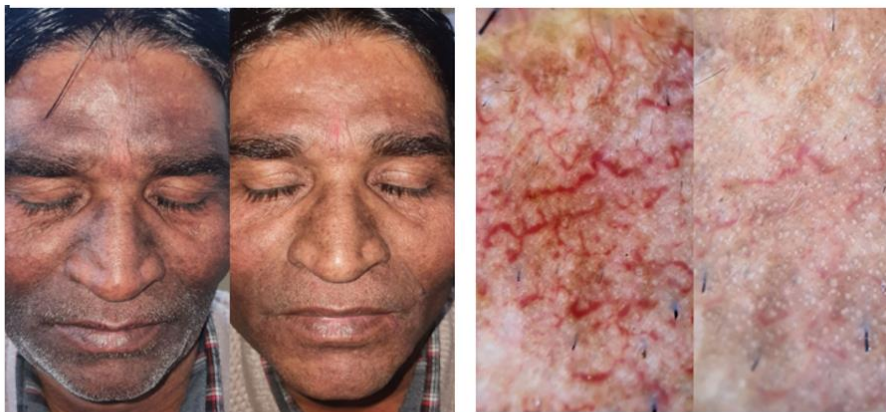



**Figure 4a: Clinical and dermatoscopic images at first OPD visit (left) and 1 month follow up (right)**



**Figure 4b: Clinical and dermatoscopic images at 1 month follow up (left) and 2 month follow up (right)**



**Figure 4c: Clinical and dermatoscopic images at 2 month follow up (left) and 3 month follow up (right)**



## REFERENCES

- [1] Sulzberger MB and Witten VH. The effect of topically applied compound F in selected dermatoses. *J Invest Dermatol* 1952; 19:101-2.
- [2] Valencia IC, Kerdel FA. Topical glucocorticoids. In: Fitzpatrick T, editor. *Dermatology in General Medicine*. 5th ed. New York: McGraw-Hill; 1999.p.27137.
- [3] Lahiri K and Coondoo A. Topical steroid damaged/dependent face (TSDF): An entity of cutaneous pharmacodependence. *Indian J Dermatol* 2016; 61:265-72.
- [4] Rathi S. Abuse of topical steroid as cosmetic cream: A social background of steroid dermatitis. *Indian J Dermatol* 2006; 51:154-5
- [5] Jindal R and Chauhan P. Dermoscopy assisted topical steroid-dependent/damaged face (TSDF) severity score (DATS Score): Reliability assessment and validation of a new scoring method. *Indian J Dermatol* 2022; 67 (2): 188-190.
- [6] Coondoo A. Topical corticosteroid misuse: The Indian scenario. *Indian J Dermatol* 2014; 59:451-5.
- [7] Feldmann RJ and Maibach HI. Percutaneous penetration of steroids in man. *J Invest Dermatol* 1969; 52: 89-94.
- [8] Sonthalia S, Jha AK and Sharma R. The role of dermoscopy in a topical steroid damaged face. *Dermatol Pract Concept* 2018; 8:166-167.
- [9] Sethi S, Chauhan P, Jindal R and Bisht YS. Dermoscopy of topical steroid-dependent or damaged face: A cross-sectional study. *Indian J Dermatol Venereol Leprol* 2021; 88:40-6.
- [10] Dhar S, Seth J, Parikh D. Systemic side-effects of topical corticosteroids. *Indian J Dermatol* 2014; 59(5):460-4.