

Research Journal of Pharmaceutical, Biological and Chemical Sciences

Placental Morphometry In Different Severity Of Hypertensive Pregnancies Compared With Normotensive.

CH Santhi^{1*}, V Subhadra Devi², and R Vijaya Ragavan³.

¹Research Scholar, Saveetha University, Chennai: Assistant professor, Department of Anatomy, Narayana Medical College, Nellore, A.P, India.

²Professor & HOD, Sri Padmavathi Women's Medical College, Tirupathi, A.P, India.

³Research Director, Saveetha University, Chennai, Tamil Nadu.

ABSTRACT

Placenta is a fetomaternal organ of pregnancy, which is vital for normal growth and development of embryo. Fetal well being depends mainly on the adequate function of placenta. Any pathological processes underlying pregnancy such as hypertension may reflect on placenta in a significant way. Hence the present study was undertaken to evaluate the morphometrical changes in different severity of hypertensive pregnancies. 140 placentas from newborns of mothers (Control-G1: 35, GH-G2: 35, PE-M-G3: 35, PE-S-G4: 35) were obtained for placental morphometry i.e placental weight, diameter, thickness, volume, circumference and statistically analyzed. The mean placental weight was found to be 424.86 ± 75.005 gms in G1, 384.29 ± 75.269 gms in G2 and 375.71 ± 78.000 gms in G3, 228.57 ± 102.387 gms in G4. The mean placental diameter was 19.08 ± 1.87 cm in G1, 17.37 ± 1.27 cm in G2, 15.47 ± 2.40 in G3, 13.18 ± 2.52 cm in G4. The mean placental thickness was observed 2.46 ± 0.56 cm in G1, 2.34 ± 0.48 cm in G2, 2.11 ± 0.40 in G3, 2.04 ± 0.39 cm in G4. The mean placental volume was 363.00 ± 87.04 ml in G1, 310.57 ± 70.99 ml in G2, 288.71 ± 86.44 in G3, 191.43 ± 91.59 ml in G4. The mean placental circumference 58.40 ± 4.78 cm in G1, 54.86 ± 5.673 cm in G2, 51.49 ± 7.540 cm in G3, 41.23 ± 8.958 in G4. All the hypertensive groups have shown a significant marked variation in placental parameters than normotensive pregnancies. Among the hypertensive group, morphometrical changes were more predictive in severe preeclampsia.

Keywords: Human placenta, morphometry, hypertension

**Corresponding author*

INTRODUCTION

In recent years no doubts hypertension is a matter of interest for researchers because of its adverse effect on perinatal outcome. It is the most common medical complication that affects the pregnancy and accounts for a great degree of maternal and fetal mortality and morbidity [1].

The studies have proven that the women with hypertensive disorders are at increased risk of perinatal death compared with non hypertensive women. Among the hypertensive group preeclampsia and eclampsia were more likely to be linked with the maternal and perinatal death. As per the estimations of the World Health Organization (WHO) in every seven minutes at least one woman dies because of hypertensive disorders during pregnancy. Worldwide around ten million women develop preeclampsia each year, of which 76,000 women die due to preeclampsia and its related complications [2, 3]

Even though numerous studies conducted on HDP, the exact mechanisms responsible for the pathogenesis have not been illuminated yet well. Literature over the past decade, supported few hypothesis that accountable for the pathogenesis of hypertension. An initiating event in hypertension is to be reduced placental perfusion that leads to maternal vascular endothelial dysfunction. Many of the studies suggested that reduced placental perfusion during pregnancy causes fetal hypoxia, which adversely affect the perinatal outcome [4, 5 and 6]

Pregnancy complicated by hypertension is commonly associated with placental abruption, intrauterine growth restriction (IUGR), preterm birth, perinatal death, small for gestational age (SGA), antepartum hemorrhage, postpartum hemorrhage and maternal death [7,8].

The placenta is a key organ in pregnancy for the intrauterine development and well-being of the fetus. It is a key structure that transport all anabolites come from the mother, which needed for development of the fetus and carried back all catabolites from the fetus into maternal circulation [9] Due to its unique function in development it commonly shares the uterine environment along with the umbilical cord [10]. During development, continuous changes occur in placental weight, shape, structure and function [11] hence the careful postnatal examination of the placenta delivers the most valuable prenatal status of the fetus and the mother [12]. Hence the present study was undertaken to explore the placental morphometric changes in hypertensive pregnancies with that of normotensive.

MATERIAL AND METHODS

This study was conducted in the Narayana Medical College and general hospital, Nellore, Andhra Pradesh, India, after taking institutional ethical committee approval and written informed consent from each participant.

140 human placentas were collected and grouped into 4, of which each group contains 35 specimens.

Control (G1): Included placentas from mother with uncomplicated pregnancy.

GH (G2): Included gestational hypertension with blood pressure 140/90 without proteinuria.

PE-M (G3): comprises mild preeclampsia with blood pressure 140/90 and proteinuria +1 dipstick in urine analysis.

PE-S (G4): Women who had blood pressure 160/110 with proteinuria +2 dipstick in urine analysis included this group.

The criteria adopted for grouping of these cases were defined according to the National High Blood Pressure education program of USA (NHBPEP) followed by the American College of Obstetrics and Gynecologists [13,14]

Immediately after delivery, the placentas were collected and the membranes were trimmed and washed under running tap water to clean the blood from both maternal and fetal surface of the placenta. Morphometric dimensions of the placentas [Figure 1] such as weight [15], diameter [16], central thickness [17], volume and circumference [18]. The volume of placentas was measured by water displacement method [19].




Figure1: Showing the placental morphometry: PW-Placental weight (gm), PDL- Placental diameter longitudinal (cm), PDT- Placental diameter transverse (cm), PT- Placental thickness (cm), PVOL- Placental volume (c.c), PC- Placental circumference (cm)

The obtained values from the study were spread in Microsoft Excel 2010. The statistical significance of the difference between the four groups was evaluated using one - way analysis of variance (ANOVA) with SPSS version 20.0. The P - Value of less than 0.005 was taken as statistical significance. Dunnett’s test was performed for multiple comparisons.

RESULTS

In the present study the range (minimum to maximum) of placental weight, diameter, thickness, volume and placental circumference were significantly decreased in G2, G3, G4 compared to G1 [Table 1].

Table 1: Ranges of placental parameters in control with hypertensive groups.

Parameters	Control(G1) (N=35) Range (Mini-Maxi)	GH(G2) (N =35) Range (Mini-Maxi)	PE-M(G3) (N=35) Range (Mini-Maxi)	PE-S(G4) (N=35) Range (Mini-Maxi)
Placental weight(gm)	300-600	250-500	200-500	100-400
Placental diameter(cm)	14.50-22.00	15.75-21.00	10.25-21.75	9.25-17.75
Placental central thickness(cm)	2.00-4.00	2.00-3.00	2.00-4.00	1.00-3.00
Placental volume(c .c)	200-600	170-420	110-540	80-350
Placental circumference(cm)	49-66	46-68	37-62	26-56

Showing range (mini-max) of placental parameters: Gm: Grams, Cm: Centimeters, C.C: Cubic Centimeter

The data in the present study suggest that all the observed parameters, i.e. the placental weight, diameter, central thickness, volume and circumference were significantly decreased in G2, G3, and G4 as

compared with the G1. The difference is statistically significant p - value ≤ 0.0005 . [Table 2]. Among the study group, the mean difference was found to be more in G4 compared with the G1.

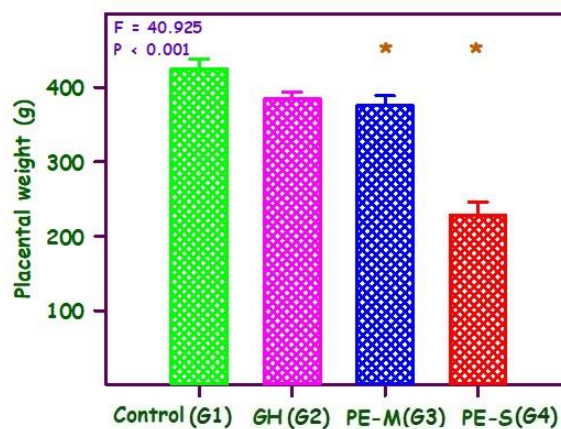
Table 2: One way ANOVA observations of placental morphometry in control and hypertensive groups.

Parameters	Groups	Number	Mean \pm SD	F Value	P Value
Placental weight (gm)	1	35	424.86 \pm 75.005	40.925	<0.0001 VHS
	2	35	384.29 \pm 55.269		
	3	35	375.71 \pm 78.000		
	4	35	228.57 \pm 102.387		
Placental diameter (cm)	1	35	19.08 \pm 1.87	52.122	<0.0001 VHS
	2	35	17.37 \pm 1.27		
	3	35	15.47 \pm 2.40		
	4	35	13.18 \pm 2.52		
Placental central thickness (cm)	1	35	2.46 \pm 0.56	6.148	.001 S
	2	35	2.34 \pm 0.48		
	3	35	2.11 \pm 0.40		
	4	35	2.04 \pm 0.39		
Placental volume (c .c)	1	35	363.00 \pm 87.04	25.334	<0.0001 VHS
	2	35	310.57 \pm 70.99		
	3	35	288.71 \pm 86.44		
	4	35	191.43 \pm 91.59		
Placental circumference (cm)	1	35	58.40 \pm 4.785	39.92	<0.0001 VHS
	2	35	54.86 \pm 5.673		
	3	35	51.49 \pm 7.540		
	4	35	41.23 \pm 8.958		

Values are presented as mean \pm Sd. Gm: Grams, Cm: Centimeters, C.C: Cubic Centimeter. VHS: Very highly significant, S: Significant

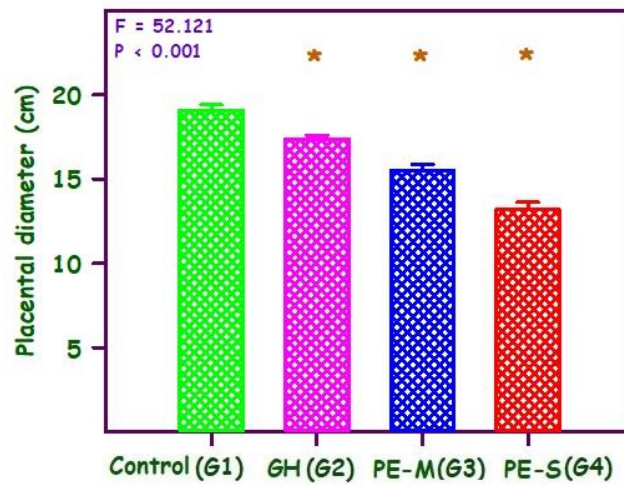
Graphs 1-5: Showing dunnett's test observations of the placental parameters in control and hypertensive groups.

Graph 1: Bar diagram showing the placental weight in grams in relation to control (G1) and hypertensive groups (G2, G3, and G4)



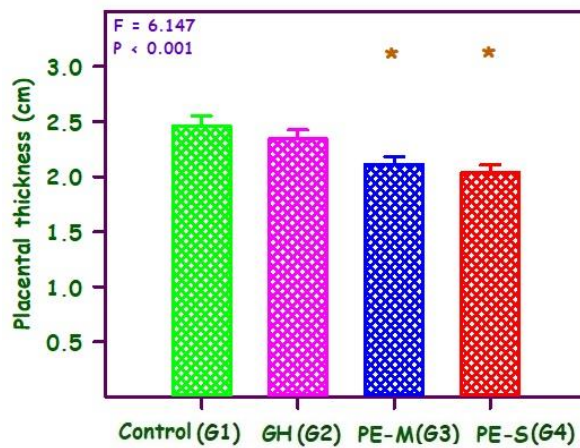
* Significantly different from G1

Graph 2: Bar diagram showing the placental diameter in centimeters in relation to control (G1) and hypertensive groups (G2, G3, and G4)



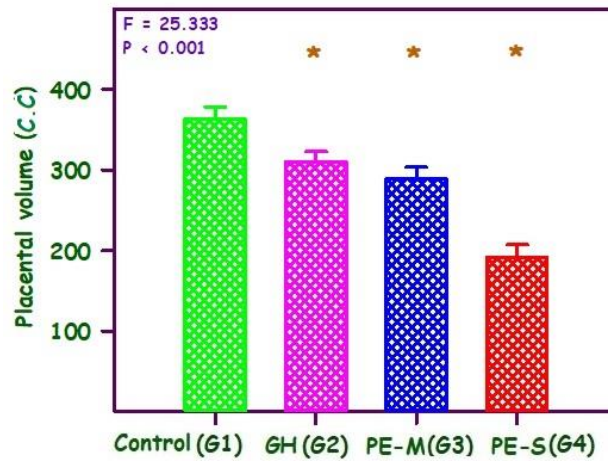
* Significantly different from G1

Graph 3: Bar diagram showing the placental thickness in centimeters in relation to control (G1) and hypertensive groups (G2, G3, and G4)



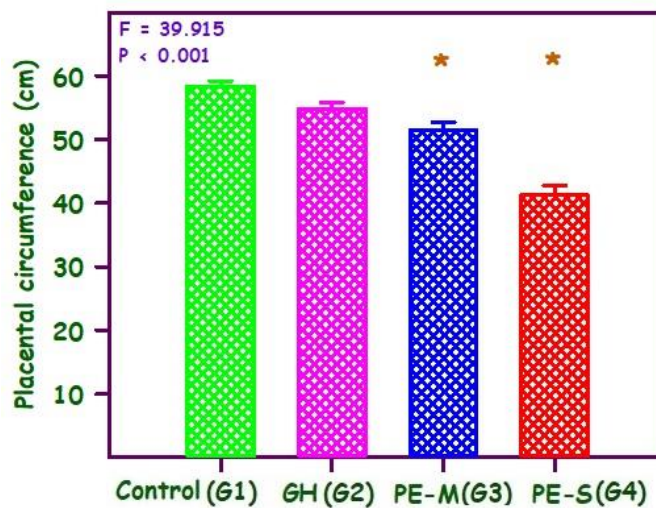
* significantly different from G1

Graph 4: Bar diagram showing the placental volume in cubic centimeter in control (G1) and hypertensive groups (G2, G3, and G4)



* Significantly different from G1

Graph 5: Bar diagram showing the placental circumference in centimeters in relation to control (G1) and hypertensive groups (G2, G, and G4)



* Significantly different from G1

DISCUSSION

In the present study, the mean difference of placental weight revealed a significant negative correlation between placental weight and degree of pathology. This is in accordance with other studies in which, the placental weight was significantly reduced with increasing severity of hypertension [20, 21, and 22]. As the degree of hypertension increases, the incidence of intrauterine growth retardation increases due to decreased placental weight. In our study, the decreased placental weight in the hypertensive group may be due to uteroplacental vascular insufficiency, which fails to provide adequate oxygen and nutrients to the developing fetus resulting in stillbirths and prematurity [23]. Several studies have demonstrated pregnancies associated with low birth weight babies or preterm deliveries are at increased risk of cardiovascular diseases and mortality [24, 25].

We noticed that there is a significant decrease in mean placental diameter and thickness in the hypertensive group as compared to control in this study, Findings were similar to those of the previous studies [26, 27]. Reduced parenchymal components are such as intervillous space, trophoblast mass of peripheral

villous tissue, capillaries [28] and reduced placental villous and vascular morphology [29] in preeclamptic pregnancies. These pathological changes could contribute to reduced placental dimensions.

In this study mean placental volume was statistically significant. The mean difference was found to be increased in G4 compared with the G1. This is in agreement with the findings of other authors who observed a significant reduction of placental volume in hypertensive pregnancies [30, 31]. Arakaki et al [32] reported small or low placental volume during the first trimester play a significant role in the development of early PIH. Low placental volume was associated with low uterine arterial perfusion because of the defective trophoblastic invasion.

A Significant difference was found in the mean placental circumference of the present study between the control and hypertensive groups and was correlated well with the other studies [33]. This reduced placental circumference may be due to small size placenta indicating an underlying pathology which influences the growth of the placenta [34]. Nag U et al [35] demonstrated about 70% of the fetal deaths in hypertensive women were due to small placental size.

CONCLUSION

In conclusion, the placental morphometric parameters such as weight, diameter, thickness, circumference and volume were found to be significantly increased between the control and hypertensive groups. Placenta, being a key structure in pregnancy the understanding and monitoring of placental biology, function and pathology may help to identify the pregnancies are at increased risk to intrauterine growth retardation, stillbirths, and premature babies. Thus the study of the placental morphometric changes in hypertensive pregnancies may help us to understand pathophysiological mechanisms and design preventive and therapeutic interventions for improved maternal and fetal outcome.

CONFLICT OF INTEREST: The authors declare that there is no conflict of interests regarding the publication of this paper

ACKNOWLEDGMENT

The authors would like to thank all the participants involved in the study for their cooperation.

REFERENCES

- [1] Koech A, Ndungu B, Gichangi P. Structural changes in umbilical vessels in pregnancy induced hypertension. *Placenta*. 2008; 29:210-214.
- [2] Mehul T Pamar, Harsha M Solanki, Vibha V Gosalia. Study of risk factors of perinatal death in pregnancy induced hypertension (PIH). *National Journal of Community Medicine*. 2012; 3 (4): 703-707.
- [3] Elena V. Kulkani , Carma Ayala, William M. Callaghan: Hypertensive disorder and severe obstetric morbidity in the united states *obstet gynecol*. Wolters Kluwer. 2009; 113: 1299-306.
- [4] Saftlas AF, Olson DR, Franks AL. Atrash HK, Pokras R. Epidemiology of preeclampsia and eclampsia in the united states, 1979-1986. *Am J Obstet Gynecol*. 1990; 163:460-465.
- [5] August P, Lindhimer MD. Pathophysiology of preeclampsia. *Hypertension*. 1995; 142:2407-2426.
- [6] Browne JCM, Veall N. The maternal placental blood flow in normotensive and hypertensive women. *J Obstet Gynaecol Br Emp*. 1953; 141-147.
- [7] Page EW, Christianson R. Influence of blood pressure changes with and without proteinuria upon outcome of pregnancy. *Am J Obstet Gynecol*. 1976; 126:821-833.
- [8] Brown MA, Hague WM, Higgins J. The detection, investigation and management of hypertension in pregnancy: Full consensus statement. *Aust N Z J ObstetGynecol*. 2000; 139-55.
- [9] Udainia A, Bhagwat SS, Mehta CD. Relation between placental surface area, infarction and fetal distress in pregnancy induced hypertension with its clinical relevance. *J. Anat. Soc. India*. 2004; 53 (1): 27-30.
- [10] Udainia A, Jain M. L. Morphological study of placenta in pregnancy induced hypertension with its clinical relevance. *J. Anat. Soc. India*. 2001; 50 (1): 24-27
- [11] Teasdale F. Gestational changes in the functional structure of the human placenta in relation to fetal growth: a morphometric study. *Am J Obstet Gynecol*. 1980; 137:560-563.

- [12] Majumdar S, Dasgupta H, Bhattacharya K, Battacharya A. A study of placenta in normal and hypertensive pregnancies. *J Anat Soc Ind.* 2005; 54(2):34-38.
- [13] National high blood pressure education program working group report on high blood pressure in pregnancy. *Am J Obstet Gynecol.* 1990; 163: 1691-1712.
- [14] The American college of obstetricians and gynecologists, ACOG practice bulletin. Diagnosis and management of preeclampsia and eclampsia. Number 33, January 2002. American college of obstetricians and gynecologists, *Int. J Gynaecol. Obstet.* 2002;77:67e75.
- [15] Yibeltal Wubale, Amenu Tolera. Gross morphological study of placenta in preeclampsia. *Anatomy Journal of Africa.* 2017; 6 (2): 977-981.
- [16] Parth R Goswami, Shaila N Shah. Placenta in normal and pregnancy induced hypertension in relation to its clinical significance: A gross study. *International journal of scientific study.* 2016; 4 (7): 58-61.
- [17] Zahra Haider Bokhari, Mah Jabeen Muneera, SM samee. Gross morphology of placenta in preeclampsia. *Gross. ANNALS.* 2017; 23 (3): 360-365.
- [18] Segupta Kishwara, Shamim Ara, Khandaker Abu Rayhan, Mahamuda Begum. Morphological changes of placenta in preeclampsia. *Bangladesh Journal of Anatomy.* 2009; 7 (1): 49-54.
- [19] Kailash Balkund, Uddhav Mane, Vijay Nayak, Mahesh Taru. Morphometric study of placenta in cases pregnancy induced hypertension and normal pregnancy. *International journal of recent trends in science and technology.* 2014; 11 (3): 425-42.
- [20] Shital Patel, Rajat N. Kumar, Jai Contractor, Vaniya V.H. Morphological changes of placenta in pregnancy induced hypertension. *Int J Res Med.* 2016;5(1):95-98
- [21] Suchithra A Shetty, Ashwini Kolor. Placenta in normal pregnancy vs placenta in pregnancy induced hypertension: A morphological and histopathological study. *J of Evidence Based Med & Healthcare.* 2015; 2 (45): 8142-8145.
- [22] Dr. Neelam Sinha, Dr. Sanjay Kumar Sinha, Dr. Ramji Prasad Singh. A study of placental weight and fetal outcome in different grades of pregnancy induced hypertension. *International Journal of Medical and health research.* 2017; 3 (2): 160-162.
- [23] Karen J. Gibbins, Robert M. Silver, Halit Pinar, Uma M Reddy, Cortete B. Parker, Vanessa Thorsten et al. Stillbirth hypertensive disorders of pregnancy and placental pathology. *Placenta.* 2016; 43: 61-68.
- [24] Clifton V.L, Stark M. J, Osei –Kumah A. Hodyl N.A. The feto-placental unit, pregnancy pathology and impact on long term maternal health: Review. *Placenta 33, supplement A, Trophoblast research 2012;* 26: S37-S41.
- [25] Jacob.A.Lykke, Jens Langhoff-Roos, Baha M.Sibai, Edmund F.Funai, Elizabeth W.Triche, Michael J.Paidas. Hypertensive pregnancy disorders and subsequent cardiovascular morbidity and type 2 diabetes mellitus in the mother. *Hypertension.* June 2009.
- [26] SaurjyaRanjan Das, Pradeep Kar, Sahadev Sahoo, Sitansu Kumar Panda, Sutandro Choudhury, Sarthak Ranjan Nayak et al. Morphological study of placenta in pregnancy with hypertension in western Odisha. *Int. J. Pharm. Sci. Rev. July - August 2015;* 33 (1): 74-78.
- [27] Maimoona Ahmed, Rekha G.Daver. Study of placental changes in pregnancy induced hypertension. *Int J Contracept Obstet Gynecol.* 2013; 2(4):524-527.
- [28] Teasdale F. Histomorphometry of the human placenta in preeclampsia, associated with severe intrauterine growth retardation. *Placenta.* 1987; 8:119-28.
- [29] Egbor. M, Ansari. T, Morris. N, Green C.J and Sibbons P. D. Preeclampsia and fetal growth restriction: how morphometrically different is the placenta? *Placenta.* 2006; Vol 27, no. 6-7:727-734.
- [30] Pradeep S Londhe, Abhay B Mane. Morphometric study of placenta and its correlation in normal and hypertensive pregnancies. *International journal of pharma and biosciences.* 2011; 2 (4): B-429-B-437.
- [31] Vijayalakshmi B, Sunita kittali. Morphological changes of preeclampsia and perinatal outcome. *International Journal of Scientific study.* 2015; 3 (5): 137-142.
- [32] Arakaki T, Hasegawa J, Nakamura M, Hamada S, Muramoto M, Takita H et al. Prediction of early –and late onset pregnancy –induced hypertension using placental volume on three dimensional ultrasound and uterine Doppler. *Ultrasound Obstet Gynecol.* 2015;45:539-543.
- [33] Dr. Sandhya Mehra, Dr. Shiv Prakash Rathore. Morphology and morphometric study of placenta in pregnancy induced hypertension and its comparison with that of normal pregnancies. *International Journal of Current Research.* 2016; 8 (7): 34714-34716.
- [34] Ciblis LA. The placenta and newborn infant with hypertension conditions. *Am J Obstet Gynecol.* 1974; 118 (2): 256-70.
- [35] Nag U, Chakravarthy VK, Rao DR. Morphological changes in placenta of hypertensive pregnant women. *IJRRMS* 2013; 3 (2): 1-4.