

# Research Journal of Pharmaceutical, Biological and Chemical Sciences

## The Ultrastructure of the Tegument of *Ornithobilharzia turkestanicum* in Maysan / Southern Iraq.

Hanaa N Abdullah<sup>1</sup>, Ismael W Ismael <sup>1</sup>, and Suzan A Al-Azizz<sup>2\*</sup>.

<sup>1</sup>Research Unit / College of Health and Medical Technology\ Middle Technical University/ Baghdad

<sup>2</sup>Department of Veterinary Microbiology and Parasitology\ College of Veterinary Medicine\ University of Basrah

### ABSTRACT

The current study focused on ultrastructure of the tegument of *Ornithobilharzia turkestanicum* by an examination of the adult worms (males and females) under transmission electron microscope, the result showed that tegument of *O. turkestanicum* as an subtegumental layer, surface layer, outer tegumental surface with numerous membrane bound vacuoles with residual bodies, compact muscle layer, canal coming from a tegumental cells, longitudinal muscle and tegumental cells.

**Keywords:** *Ornithobilharzia turkestanicum*, Maysan, transmission Electron Microscope, tegument, Iraqi Strain.

*\*Corresponding author*

## INTRODUCTION

Schistosomiasis was considered as the oldest diseases known with parasitic infections that described along the history; it affects about more than two hundred million people around the world with an average 85%, these cases are settlers to African continent [1]. The disease which is called Bilharziasis, referred to as German scientist Theodor Bilharz who has the firstly described disease at 1851 [2]. Schistosomiasis is the most important parasitic disease after malaria at the world for public health [3].

Schistosomiasis found in human, birds and animals and may get infection when they contact with infected waters with cercaria, and the infection occur when cercaria of the parasite is perforate the infected snails (intermediate host) and penetrate the skin of the human, birds or animals as final host [4].

The genus *Ornithobilharzia* was originally called *Schistosoma*, and then re-named to *Ornithobilharzia* by [5] which classified according to the number of their testes. However, the species epithet was 'turkestanica', not turkestanicum [6]. *O. turkestanicum* has been reported from different parts of Asia [7]. In Iran the parasite is of great economic importance because of the losses in sheep meat and wool production and intestine processing by its damages [8].

The previous studies on Ornithobilharziasis have been concentrated on the life history [9, 10], pathology [8, 11], morphology [12], immunity [13, 14] and epidemiology [15]. While, little studies have been done in the classification, molecular phylogenetic studies of *Ornithobilharzia* spp. [16, 17, 18] and electron microscope [19].

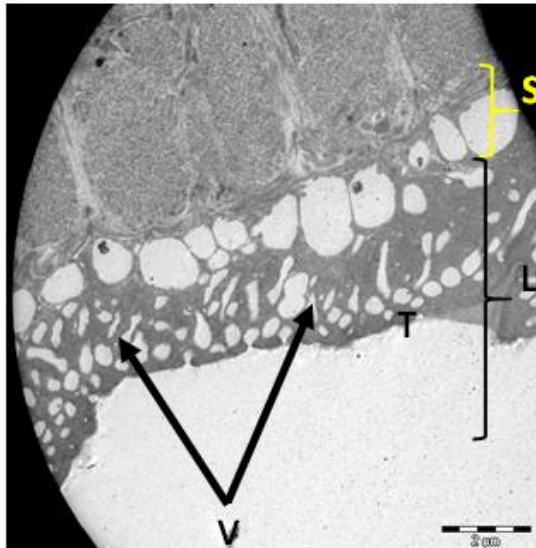
The aim of this study was focusing on *O. turkestanicum* by transmission electron microscopy.

## MATERIALS AND METHODS

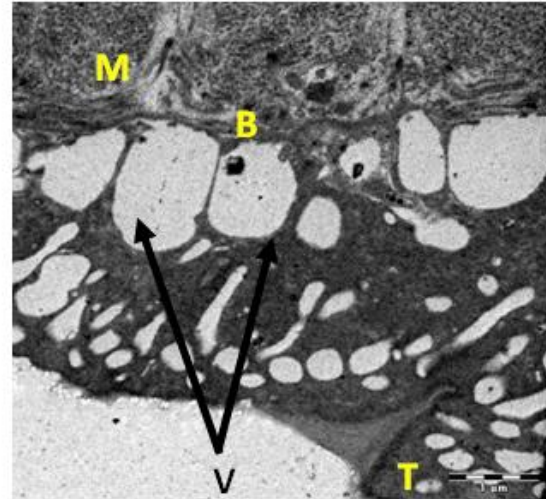
A three different provinces were examined their slaughtered animals from slaughterhouse under the present study (Baghdad, Maysan and Basrah), but the adults flukes of *O. turkestanicum* were found only in Maysan slaughter house called (Almajidya slaughter house), so, collected worms from slaughtered sheep in the local slaughter house in Almajidya in Maysan province. Flukes were collected from the mesenteric veins (intestinal veins) of an infected sheep for the period from July 2015 till December 2015 by using special illustration device designed to facilitate the observation of adult *O. turkestanicum* inside the mesenteric veins, identified based on white color, and the isolated worms were fixed for used in transmission electron microscope to detect the morphology of the worm (in addition to routine microscopic examination) and to detect any exchanges will appear on the worm as a normal according to the method of [20].

## RESULTS

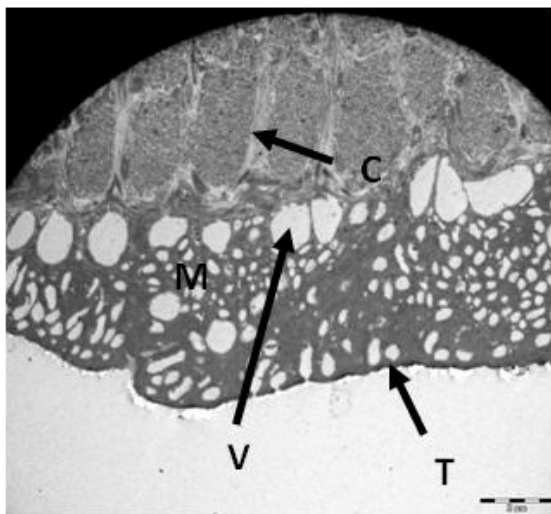
Examination by transmission electron microscope showed many of differentiations includes: tegument of adult *O. turkestanicum*, Sub tegumental layer, Surface layer, outer tegumental surface with numerous membrane bound vacuoles with residual bodies and compact muscle layer (Photomicrograph, 1), tegument of *O. turkestanicum*, outer tegumental surface with numerous membrane bound vacuoles with residual bodies, compact muscle layer and Basal membrane (Photomicrograph, 2), tegument of *O. turkestanicum*, outer tegumental surface with numerous membrane bound vacuoles, compact muscle layer and canal coming from a tegumental cells (Photomicrographs, 3), tegument of *O. turkestanicum*, outer tegumental surface with numerous membrane bound vacuoles, compact muscle layer, longitudinal muscle and tegumental cells (Photomicrographs, 4). While in Photomicrographs ( 5-7) showed tegument of *O. turkestanicum*, outer tegumental surface with numerous membrane bound vacuoles, compact muscle layer.



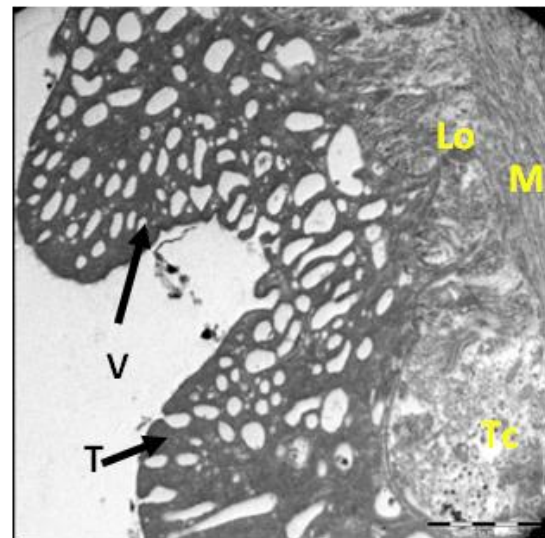
Photomicrograph (1): Tegument of *Ornithobilharzia turkestanicum*, Sub tegumental layer (S), Surface layer (L) outer tegumental surface (T) with numerous membrane bound vacuoles (V) with residual bodies, compact muscle layer (M), (2µm).



Photomicrograph (2): Tegument of *Ornithobilharzia turkestanicum*, outer tegumental surface (T) with numerous membrane bound vacuoles (V) with residual bodies, compact muscle layer (M), Basal membrane (B), scale bar (1µm).

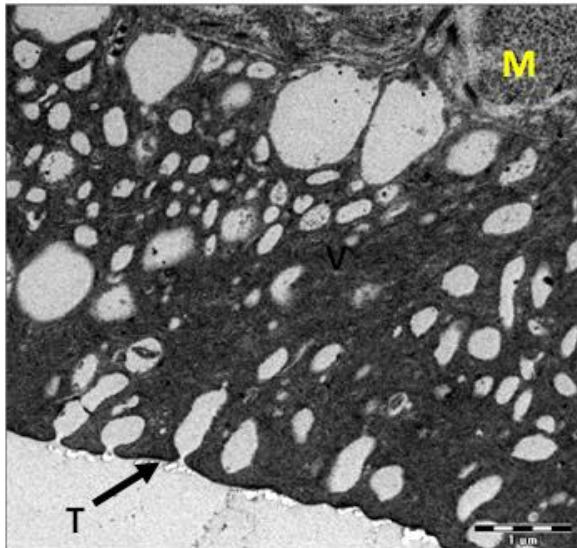


Photomicrograph (3): Tegument of *Ornithobilharzia turkestanicum*, outer tegumental surface (T) with numerous membrane bound vacuoles (V), compact muscle layer (M), canal (C) coming from a tegumental cell, scale bar (2µm).

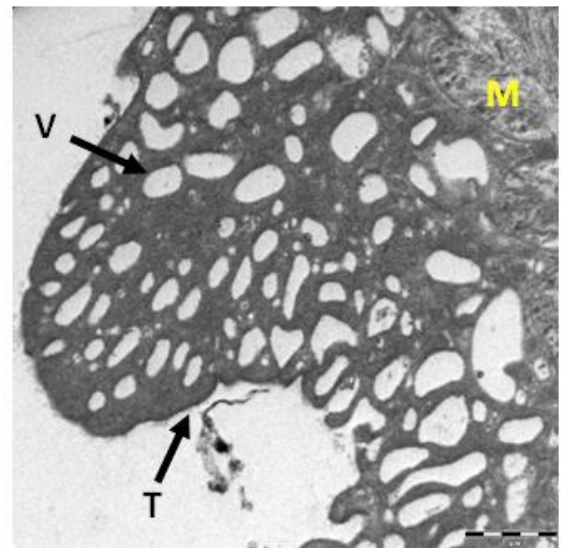


Photomicrograph (4): Tegument of *Ornithobilharzia turkestanicum*, outer tegumental surface (T) with numerous membrane bound vacuoles (V), circular muscle (M), longitudinal muscle (Lo), tegumental cell (Tc), scale bar (2µm).

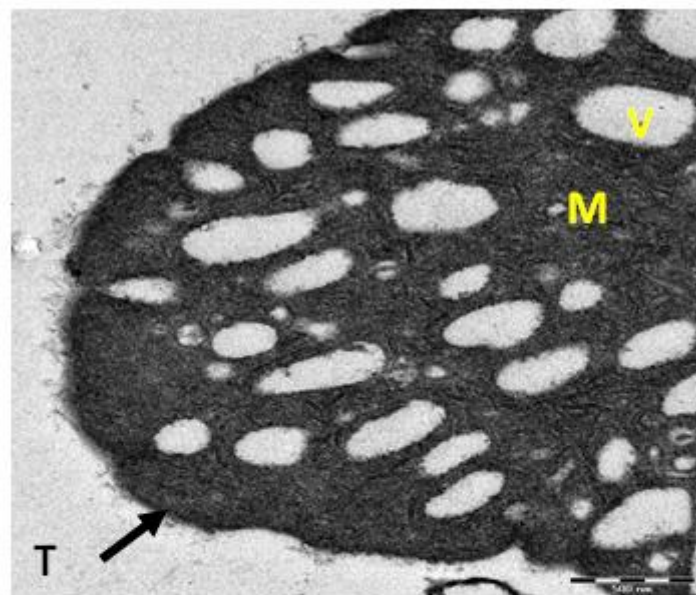




Photomicrograph (5): Tegument of *Ornithobilharzia turkestanicum*, outer tegumental surface (T) with numerous membrane bound vacuoles (V), compact muscle layer (M), scale bar (1μm).



Photomicrograph (6): Tegument of *Ornithobilharzia turkestanicum*, outer tegumental surface (T) with numerous membrane bound vacuoles (V), compact muscle layer (M), scale bar (1μm).



Photomicrograph (7): Tegument of *Ornithobilharzia turkestanicum*, outer tegumental surface (T) with numerous membrane bound vacuoles (V), compact muscle layer (M), scale bar (500 μm).

## DISCUSSION

The transmission electron microscope showed outer tegumental surface of *O. turkestanicum* with numerous membrane bound vacuoles with residual bodies and compact muscle layer, tegumental cell, canal

coming from a tegumental cell and tegumental surface with numerous membrane bound vacuoles without residual bodies.

The present study agreement with [21] who study ultrastructure of the tegument of adult *S. mansoni*, recorded *S. mansoni* is like that of all other described trematodes, connected by cytoplasmic tubes to nucleated "tegumental cells" lying in the parenchyma, and the surface of the cuticle is elaborately folded and many cuticular channels penetrate the matrix, the mitochondria also present in the cuticle or in the tegumental cells. [22] recorded some of the features differ from the reported features of *S. japonicum* and other *Schistosoma* species, structural differences on the adult *S. japonicum* are noted between both sexes, with different area of the adult flukes and between sides along the length of the parasite. The differences included variations in the size, number and ultrastructure tegumental bodies and mitochondria within the matrix, and differences in the relative area of the apical surface of the tegument.

In conclusion it can be say that transmittion electron microscope showed a good diagnostic tool for distinguish the tegument of *O. turkestanicum* as an Iraqi strain.

## REFERENCES

- [1] Kali A. Schistosome Infections: An Indian Perspective. Mahatma Gandhi Medical College & Research Institute, Pondicherry, India (2015). 9(2): 1-4.
- [2] Sörén K. Experimental *Schistosoma bovis* Infections in Goats. Acta Universitatis Agriculturae Sueciae, Uppsala, Sweden. (Doctoral Thesis). (2009).
- [3] Steinmann P, Keiser J, Bos R, Tanner M, and Utzinger J. Schistosomiasis and water resources development: systematic review, meta-analysis, and estimates of people at risk, The Lancet Infectious Diseases, (2006). 6(7): 411–425.
- [4] Malek EA. Snail-Transmitted Parasitic Diseases. CRC Press Inc., Boca Raton, FL, (1980). pp.179–307.
- [5] Price EW. A synopsis of the trematode family Schistosomatidae with descriptions of new genera and species. Proc. U. S. Nat. Mus., (1929). (75): 1–39. (Cited by Wang *et al.* 2009a)
- [6] Yamaguti S. A synoptical review of the histories of digenetic trematodes of vertebrates. Keigaku Publishing Co., Kyoto., (1975). pp. 384.
- [7] Kumar F, and De Burbure G. Schistosomes of animals and man in Asia. Helminthol., (1986). (55):469–80.
- [8] Ezzi A, Karimi GH and Gholami MR. Experimental Pathology of *Ornithobilharzia turkestanicum* in Sheep. Arch Razi Ins., (2004). (57):127-32.
- [9] Dutt SC, and Srivastava HD. Studies on the life history of *Orientobilharzia tukestanicum* (Skrjabin, 1913) Sutt and Srivastava, 1955(Preliminary report). Curr Sci., (1964). (33):752–753.
- [10] Al-To'mma MAM. A study of some pathological effects of *Orientobilharzia turkestanicum* on fresh water snail *Lymnaea auricularia*, M.Sc. thesis, University of Basrah, (1997). 1-51.
- [11] Al-To'mma ZAM. The liver cirrhosis caused by *Orientobilharzia turkestanicum* in Basra governorate, J. of College of Education, Thi-Qar University, (2011). 5(1): 81-87.
- [12] Majorosa G, Dan A, and Erdelyi K. A natural focus of the blood fluke *Orientobilharzia turkestanicum* (Skrjabin, 1913) (Trematoda: Schistosomatidae) in red deer(*Cervus elaphus*) in Hungary. Vet. Par. Int. Sci. j., (2010). (170): 218–223.
- [13] Massound J, and Nelson GS. Studies on heterologous immunity in Schistosomiasis. 6. Observations on cross-immunity to *Ornithobilharzia turkestanicum*, *Schistosoma bovis*, *S. mansoni*, and *S. haematobium* in mice, sheep, and cattle in Iran. Bull. WHO, (1972). (47):591-600.
- [14] Karimi Gh R, Abdigoudarzi M, Valizadeh M, and Miranzadeh H. Comparison of Excretory-Secretory and Somatic Antigens of *Ornithobilharzia turkestanicum* in Agar Gel Diffusion Test, Iranian J Parasitol., (2008). 3(4):19-22
- [15] Wang CR, Chen J, Zhao JP, Chen AH, and Zhai YQ. *Orientobilharzia* species: neglected parasitic zoonotic agents. Acta Trop., (2009a). (109): 171–175.
- [16] Wang CR, Li L, and Ni HB. *Orientobilharzia turkestanicum* is a member of *Schistosoma* genus based on phylogenetic analysis using ribosomal DNA sequences. Exp. Parasitol., (2009b). 121(2): 193–7.
- [17] Wang CR, Xu MJ, Fu JH, Nisbet AJ, and Chang QC. Characterization of Micro RNAs from *Orientobilharzia turkestanicum*, a Neglected Blood Fluke of Human and Animal Health Significance. PLoS ONE, (2012). 7(10): e47001.

- [18] Yakhchali M, Mirraji SY, and Malekzadeh-Viayeh R. Detection of Infection with Larval Stages of *Ornithobilharzia turkestanicum* using PCR in Field-Collected Snails of *Lymnaea gedrosiana* from Northwestern Iran. *Iranian J. Parasitol.*, (2013). 8(4): 627-633.
- [19] Tang CT, Cui G W, Qian Y C, and He YX. Scanning electron microscopy of the integumental surface of *Orientobilharzia turkestanicum*, *Acta Zoologica Sinica.*, (1983a). 29(2): 159-162.
- [20] Hayat MA. *Basic Techniques for Transmission Electron Microscopy* . Academic Press , New York. (1986).
- [21] Morris GP. and Threadgold LT. Ultrastructure of the tegument of adult *Schistosoma mansoni*. *J. Parasitol.*, (1968). (54): 15-27.
- [22] Goberta GN, Stenzelb DJ, McManusa DP and Jonesa M K. The ultrastructural architecture of the adult *Schistosoma japonicum* tegument, *Inter. J. Parasitol.*, (2003). 33(14): 1561–157