

Research Journal of Pharmaceutical, Biological and Chemical Sciences

Clinicopathological Changes in Sera of Broiler Chicken Given Antibacterial and Or Prebiotics.

¹Khaled Mohamed ELbayoumi*, ¹ Zeinab MS Amin Girh, ²Aziza M Amer, ¹Eman R Hassan, and ³MM Amer.

¹Dept of Poultry. Diseases, Vet. Res. Division, NRC, P.O. Code 12311 Dokki, Giza, Egypt

²Dept of Pharmacology, Faculty Vete. Med., Cairo University, P.O. Code 12211 Giza, Egypt

³Dept of Poult. Dis., Faculty Vete. Med., Cairo University, P.O. Code 12211 Giza, Egypt

ABSTRACT

Aim of this study to investigate effect of colistin and or tylosin in presence or absence of prebiotics on liver and kidney function. A total number of 320, 1- day old broiler chicks were divided into 8 equal groups ,40 chicks in each. Tylosin and colistin were used 3 times at the 1st 5, 2nd from days 10-15 and 3rd from days 20-25 of age while lysozyme was used start from day 5 till day 25 of age. Blood samples collected from each group for liver and kidney function test together with liver and kidney tissue samples for histopathological examination at 15 and 30 days of life. Results of liver function The recorded liver function test at the 30th day of life the lowest serum Glutamate pyruvate transaminase (GPT) was 2.22 ± 0.67 in lysozyme , followed by 2.50 ± 0.84 , 2.67 ± 0.82 and 3.33 ± 0.82 in groups given lysosyme with colistin, tylosin and Tylosin -colistin ; respectively. Groups given drugs only tylosin, colistin, tylosin[and Tylosin -colistin showed 3.95 ± 0.88 , 4.00 ± 2.28 and 4.10 ± 1.27 ; respectively. Nearly Same battern was seen in both of serum albumin and creatinine levels. Results of histopathology proved that groups given lyszyme showed milder liver and kidney lesions than those given drugs only. Birds given combined drugs show more sever lesions than those given separate drug. Tylosin exert more adverse effective on liver, while colistin showed to be more adverse effect on kidney. Administration of lysosime improve the adverse effect of drug on tested tissue sections. It could be concluded that birds given combined drugs show more sever lesions than those given separate drug. Tylosin was more effective on liver, while colistin showed to be more effect on kidney. Administration of lysozyme improve the adverse effect of drug on tested tissue sections. Therefore, we advice to administer the used drugs in the recommended dose with prebiotic to get better results.

Keywords: kidney and liver, function test , histopathology, colistin , tylosin, lysosyme

**Corresponding author*

INTRODUCTION

Antibiotic is a compound or substance that kills or inhibit bacterial growth. Antibiotics are broadly classified based on their structure, mechanism of action and or range of mechanism of action, in which most of them work on arresting bacterial growth and finally their death [1]. Massive use of medications in poultry industry is crucial which could affect vital organs specially under continues exposure during short period of time, one of those widely used in Egyptian market was antibiotics such as tylosin and colistin. Tylosin is used extensively in therapeutic treatment of infectious disease such as *Mycoplasma galisepticum* the causative agent of chronic respiratory disease in poultry [2] and clostridial disease infection [3] while Colistin sulfate is a chemical that is very effective in treating bacterial infections, especially those caused by multiple-drug resistant gram-negative bacteria [4]. Colistin sulphate was used in treatment of enteric bacterial disease [5] and is effective in control of *E. coli* that is main complicating bacteria in complicated chronic respiratory disease CCRD [6].

Unfortunately hazard use of this antibiotics either due to miss diagnosis or continues exposure due to bacterial challenge together with bad biosecurity could affect vital organs such as liver and kidneys as it was found that colistin antibiotic extensive use could affect liver and kidneys seriously causing elevation of creatinine which is a marker of kidney function and its health [7], moreover other reported nephrotoxicity of Polymyxins that resulting in acute tubular kidney necrosis [8] other researchers found that parenteral use of colistin results in elevation of liver and kidneys parameters in growing broilers [9].

While tylosin antibiotic extensive prolonged use in higher dose results in slightly manifested and fully reversible dystrophic changes in the liver and kidneys together with a rise of urea level and activity of blood transaminases as well as to moderate destructive changes in the liver and kidneys [10]. Moreover hazard use of antibiotics include antibiotic resistant- pathogens together with antibiotic residues in poultry which directly affecting human health [11] and [12] on the other hand prebiotics such as lysozyme is now extensively used in poultry industries due to its beneficial effects, as Lysozyme is widely used in modern poultry production as antibiotic alternative [13], also it was found that lysozyme dietary supplementation resulting in increase plasma antioxidant activities of enzymes together with total antioxidant capacity [14], other researcher reported that lysozymes inclusion in poultry ration resulting in enhancing immunoglobulin A (IgA) secretion, macrophage activation [15]. The possible adverse effect of antibiotics on liver and kidneys functions were followed by testing liver and kidneys serum biomarkers such as Glutamate oxido transaminase (GOT), Glutamate pyruvate transaminase (GPT), acid phosphatase (ACPase), alkaline phosphatase (ALKPase), total protein and albumin [16].

Our study was designated in order to study the effect of regular used antibiotic medication (tylosin and or colistin) in poultry production on biochemical parameter in broiler sera represented by liver and kidney function test in presence or absence of lysozyme as a prebiotic.

MATERIAL AND METHODS

Experimental Chicks:

A total number of 320 broilers Cobb chicks were divided into 8 equal groups; 40 chicks in each. The used chicken groups were kept in clean disinfected pens and given open ration and water.

Ration

Commercial starter and grower broiler chicken ration were given till 21 and 32 days of age, respectively. The used commercial balanced ration based on yellow corn or soyabean that met the National Research Council (NRC) (1984) broiler chicken requirements. The starter ration contained crude protein-not less than 21%, crude fat-not less than 2.94%, crude fibers-not less than 2.35%, metabolizing energy-not less than 3054 Kcal/kg ration and used for the first 3 weeks of age. The grower ration contained crude protein-not less than 17.15%, crude fat-not less than 2.5%, metabolizing energy-not less than 3020 Kcal/kg ration and used for the remaining of the experimental period. The ration contained coccidiostat (Semiduramicin) while no antibiotics were added to it

Prebiotic:

Lysozyme10%: produced by Nanchang lifeng Industry and Trading Co.,Ltd., Batch no. 20131030 , exp. date : October 2016 . Dosage 0.5 gm/L drinking water.

Antibiotics:

- * **Colistin sulphate 6 MIU:** each gm contains 6000.000 IU colistin sulphate. Lot No. 150415 . Jordan Vet. and Agr. Med. Ind. Co – Amman – Jordan.
- * **Tylox® :** tylosin water soluble powder 100gm - Lot. No. 150118. Jordan Vet. and Agr. Med. Ind. Co – Amman – Jordan.

Vaccination program:

Live vaccines applied Hitchner B₁ against Newcastle disease (ND) at 5 days of age by eye drops instillation methods while against Infectious Broncheitis (IB) disease using live H 120 strain at one day old by coarse spray and against Infectious Bursal Disease (IBD) using live intermediate plus strain (Bursine plus®) at 14 days of age by eye drops instillation while inactivated vaccine against Avian Influenza (AI-ND) disease CEVA® at 7 days old of age through s.c route at the back of the neck.

Serum samples:

Blood samples for serum collection for liver and kidney function test were collected weekly. Serum was stored at -20°C until used.

Histopathological Studies:

Tissue specimens from liver and Kidney of experimental birds of each group chicks were fixed in 10% neutral formalin solution and the specimens were routinely processed in paraffin embedding method ,sectioned and stained with Haematoxylin and Eosin (H&E) for light microscopic examination according to [17].

Liver and Kidney function test:

Kits used for estimation of liver and kidney function test were obtained as commercial.

- Serum aspartate aminotransferase **ALT** Glutamic pyruvic transaminase (**GPT**) kits produced by Diasys Co.; used according to [18].
- Creatinine kits produced by Diasys Co.: Determination of serum creatinine as described by [19].
- Serum albumin measurements were done in a semiautomatic analyzer (TP Analyzer Plus; Thermoplate - China), using commercial kits (Labtest Diagnóstica S.A.- Lagoa Santa - MG - Brazil). All tests were carried out in duplicates.

Experimental design:

A total number of 320 one day old broiler chicks divided into 8 equal groups ,40 chicks in each. Groups 2, 4, 5 and 7 treated with tylosin , group 3,4,6 and 8 treated with colistin sulphate , groups 5 - 8 received lysozyme while Birds of groups 1 were kept as negative control. Tylosin and colistin were used three times 1st from day 1 till day 5 of age , 2nd from days 10-15 of age and 3rd from days 20-25 of age while lysozyme was used start from day 5 till day 25 of age. Blood samples collected from each group for kidney (creatinine and albumin) and liver function (GPT) test at day 15th and 30th of age together with liver and kidney samples for histopathological examination for each group at start, during and by the end of the experiment. Results of chicken's liver and kidneys function are shown in tables (2 and 3) as well as figures (1, 2 and 3).

RESULT AND DISCUSSION

Antibiotics are widely used in developing countries including Egyptian poultry field but with no restrictions and could be used in higher than recommended dose and for excessive periods of time regardless withdrawal periods for antibiotics residues control in broiler meat or egg from laying hens, that's causing toxicity in poultry and public health importance in human beings.

The recorded liver function test (Table 2) at the 30th day of life the lowest serum GPT was 2.00 control negative (gr 1) followed by 2.22±0.67 in lysozyme (gr 8) , followed by 2.50±0.84 in (gr 6) received colistin- lysozyme, followed by 2.67±0.82 in tylosin-lysozyme (gr 5) , followed by group (7) received Tylosin-colistin - lysozyme which was 3.33±0.82, followed by group (2) received tylosin which was 3.95±0.88, followed by 4.00±2.28 in group (3) received colistin, and finally the highest was group (4) received tylosin-colistin which was 4.10±1.27. Result of serum albumin level revealed that the lowest was group (7) received tylosin-colistin - lysozyme which was 1.65±0.35, followed by group (8) which received lysozyme which was 1.70±0.22, and 1.70±0.40 in control negative group (1), followed by group (6) which received colistin - lysozyme which was 1.80±0.18, then group (5) which received tylosin -lysozyme which was 1.83±0.28, followed by group (2) which received tylosin which was 1.85±0.12, followed by 2.68±0.67 in colistin group (3) , then finally group (4) received tylosin -colistin which showing highest serum albumin level which was 2.78±0.25.

Serum creatinine levels (Table 3) showing that the lowest was group (7) received tylosin -colistin - lysozyme which was 0.18±0.01 followed by group (1) control negative group which was 0.20±0.02, followed by group (8) received lysozyme which was 0.21±0.06, followed by group (6) received colistin - lysozyme which 0.21±0.08, followed by group (5) received tylosin-lysozyme which was 0.22±0.06, followed by group (2) received tylosin which was 0.23±0.03, followed by group (4) received tylosin -colistin which was 0.44±0.09 and finally the highest was group (3) received colistin which was 0.48± 0.07.

Table 1: Chicken groups and used drugs and or prebiotic.

Group	Type of treatment
1	Control -ve
2	Tylosin
3	colistin
4	tylosin+ colistin
5	tylosin+ lysozyme
6	colistin + lysosime
7	tylosin+ colistin + lysosime
8	lysosime

Table 2: Liver function test in chicken group received antibiotic and/or prebiotic at serum samples collected at 15 and 30 days of age.

Group Number	Treatment	Sample at days of age	GPT		Albumin	
			Range	Mean ± SD	Range	Mean ± SD
Normal value		-	3.5-3.7		1.6-1.8	
1	Control negative	15	2	2.00 0.00	1.17- 2.32	1.55 0.37
		30	2	2.00 0.00	1.18- 2.12	1.70 0.40
2	Tylosin	15	2-4	2.95 0.00	1.28- 2.69	1.70 0.28
		30	2- 5	3.95 0.88	1.30- 2.26	1.84 0.12
3	Colitin	15	2- 12	4.20 4.38	2.38- 2.90	2.50 0.23
		30	2- 7	4.00 2.28	1.88- 3.56	2.68 0.67
4	Tylosin-Colitin	15	3-4	3.5 0.55	1.69- 2.51	2.04 0.35
		30	2- 5	4.10 1.27	2.49- 3.13	2.78 0.25

5	Tylosin-lysozyme	15	2	2.00 0.00	1.87- 2.43	2.18 0.19
		30	2- 4	2.67 0.82	1.74- 2.85	1.85 0.28
6	Colitin - lysozyme	15	2- 3	2.5 0.55	1.51- 2.33	1.92 0.15
		30	2-4	2.50 0.84	1.49- 2.21	1.80 0.18
7	Tylosin-Colitin-lysozyme	15	2	2.00 0.14	1.15-2.13	1.61 0.23
		30	2- 4	3.33 0.82	1.17- 2.10	1.65 0.35
8	lysozyme	15	2- 3	2.17 0.41	1.19-2.35	1.72 0.26
		30	2- 3	2.22 0.67	1.18- 2.29	1.70 0.22

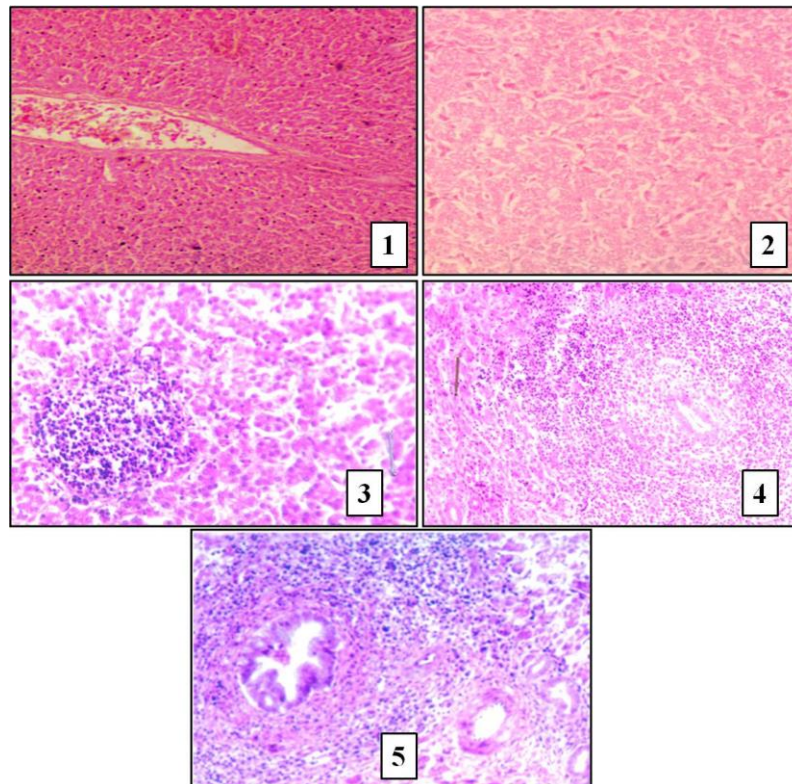
Table 3: Kidney function test in chicken group received antibiotic and/or prebiotic at serum samples collected at 15 and 30 days of age.

Group Number	Treatment	Sample at days of age	CREATININE	
			Range	Mean \pm SD
1	Control negative	15	0.04 -0.27	0.16 0.08
		30	0.19 - 0.24	0.20 0.02
2	Tylosin	15	0.11- 0.24	0.18 0.03
		30	0.19 - 0.26	0.23 0.03
3	Colistin	15	0.12- 0.38	0.28 0.14
		30	0.41 - 0.58	0.48 0.07
4	Tylosin-Colistin	15	0.19 - 0.50	0.35 0.13
		30	0.36 - 0.60	0.44 0.09
5	Tylosin-Lysozyme	15	0.21 - 0.24	0.22 0.02
		30	0.23 - 0.41	0.22 0.06
6	Colistin-Lysozyme	15	0.18-0.20	0.20 0.01
		30	0.09 - 0.27	0.21 0.08
7	Tylosin-Colistin-Lysozyme	15	0.08 - 0.21	0.16 0.05
		30	0.11 - 0.20	0.18 0.01
8	Lysozyme	15	0.14 - 0.31	0.20 0.07
		30	0.16 - 0.30	0.21 0.06

Results of both kidney and liver function tests revealed that control group was within normal value and lysozyme has the lowest serum biochemical test values compared with control group and within normal value while those received antibiotic colistin showing highest serum biochemical test level over normal value when compared with control group moreover results showing that lysozyme dilute harmful effect induced by used antibiotics when compared with using those antibiotic alone, this results was matched with results found by [20] who stated that prebiotic (betaine) exert antifibrotic effect on liver induced by chemical toxicity together with inhibition of lipid peroxidation, hepatic inflammation cytokine and transforming growth factor - β 1 expression levels, moreover results found by [13] who ensure prebiotic (betaine) antioxidant activity on vital organs due to its effect on metabolism of sulphur containing amino acid by increasing of S-adenosylmethionine (SAM) and methionine through enhancing methionine -homocysteine cycle together with methyl group donor activity , this results in improves vital organ function such as liver, kidney and brain. Also better lysozyme serum biochemical parameter maybe due to it improves plasma antioxidant activities of enzymes together with total antioxidant capacity antioxidant action [14] , also antibacterial effect of lysozymes together with its action on toxins produced by pathogenic bacteria (Clostridium spp.) maybe a cause of protection of vital organs from bad effect of both pathogenic bacteria [21] and its toxins [22]. increase in liver function test in group received tylosin may be caused by excessive use of this antibiotic under our experiment condition for 15 days divided in three intervals, as tylosin antibiotics metabolized by cytochrome P450-3A pass way in liver [23] which considered overload on hepatocytes due to use of tylosin for three successive times five days intervals within short period of time. The increased liver function test may resulted from high tissue

concentration of tylosin due its high volume of distribution to tissues (liver, kidneys lung) [24]and [25] and prolonged half-life 5.78 hours [26] and [27] which indicates prolonged persistence of tylosin in liver and kidney tissues for at least 5 days after stop of medicationand increase the load on tissues and probability of tissue damage [28] and [29] Increase in liver and kidney serum biochemical parameters in groups received colistin may be due that known nephrotoxicity [7] , other researchers found that use of colistin sulphate resulting in decrease total protein due to hematuria and proteinuria [8] , moreover other reported elevated albumin level in colistin treated broiler chickens [30] ,other researchers stated that parenteral use of colistin results in elevation of liver and kidneys parameters in growing broilers [9], on the other hand it was noticed that liver, lung, kidney, and thigh muscle after oral administration of colistin sulphate contains limited residues [31] however the continues use of this antibiotic in broiler flocks within short period of time will increase tissue residues resulting in harmful adverse effect. In the other side [16] reported that a clear decrease was seen in the total protein, ALT activities in the roosters which received overdose antibiotic for long duration, which may indicate a chronic effect of both dose and duration on liver functions. Also ALKPase was evidently one fold higher in case of group received over dose than the one treated with normal dose as well as an increase in the ALT was clear seen in normal dose and duration.

Concerning liver histopathological findings it was found that control negative (gr 1) showed no detectable pathological changes within all observation periods compared with treated groups. Group 8 received lysozymes showing unclear to mild pathological changes. Liver: Birds received tyrosin and colistin (gr 4) at 15 days of age liver sections showed, dilated portal vein with focal lymphoid cells aggregation in the hepatic parenchyma (Fig1). While, at 30 days showed; focal inflammatory cells infiltrations in the hepatic parenchyma was seen (Fig 2). Degeneration in the hepatocytes with congested central vein and sinusoids was detected at both 30 days (Fig 3) in group (3) received colistin. Focal necrosis with inflammatory cells infiltration were seen (Fig 4) at both 15 days in gr (7) while, at 30 days, hyperplasia of bile duct with massive number of inflammatory cells infiltrations in the portal area and dilated portal vein (Fig5). While groups received either tylosin-lysozymes (gr 5) or colistin – lysozyme (gr 6) showing mild congestion of portal vein.



H&E stained liver sections chicken of chicken given antibiotics and or prebiotic showing :

Fig 1: Liver of chicken showing dilated portal vein with focal lymphoid cells aggregation in the hepatic parenchyma.

Fig 2: Liver of chicken focal inflammatory cells infiltrations in the hepatic parenchyma.

Fig 3: Liver of chicken showing lymphoid cells aggregation .

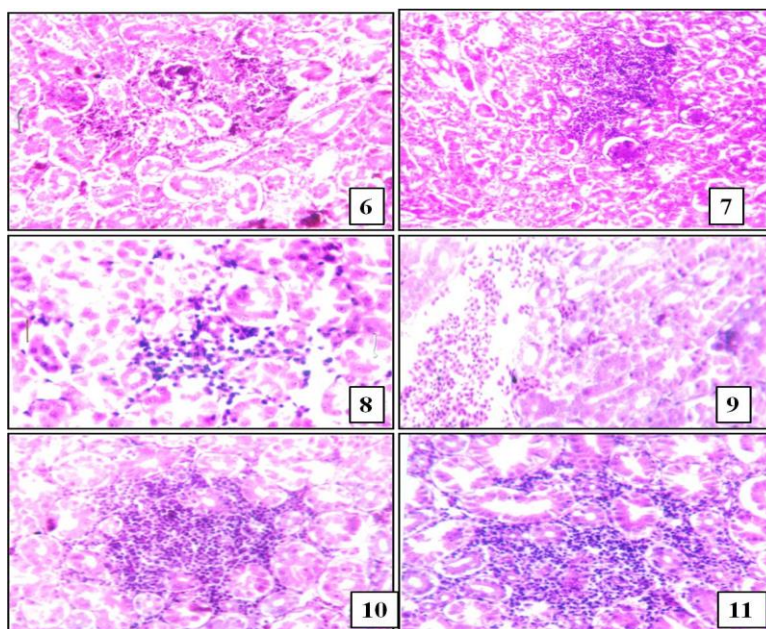
Fig 4: Liver of chicken showing focal necrosis with inflammatory cells infiltration

Fig 5: Liver of chicken showing hyperplasia in bile duct with massive number of inflammatory cells infiltration in the portal area .

Our results revealed that lysozymes was not harmful on liver by the end of the experiments , on the other hand tylosin excessive use within short period of time has an adverse effect on liver tissue this maybe due to its metabolism through liver [23] which is more prominent pathological changes when compared with colistin which show sort of hepatotoxicity [9] , on the other hand use of betaine dilute harmful effect induced by both antibiotics due to tissue protective effect, antifibrotic effect on liver , inhibition of lipid peroxidation together with inhibition of hepatic inflammation cytokine[20], also other researchers reported that betaine exert antioxidant activity on vital organs function including liver [22]. While lysozymes improves plasma antioxidant activities [14] together with improvement of bacterial toxins that causing hepatotoxicity [21].

Kidney: Tylosin and colistin (group 5) showed lesions at 15 days, as congestion in the blood vessels and focal renal hemorrhage (Fig 6). While. Focal lymphoid cells aggregations in between the renal tubules and glomeruli (Fig 7) was seen at 30 days.

Tylosin (group 2) at 15 days, focal inflammatory cells infiltrations in between the renal tubules and glomeruli (Fig 8), Congestion of blood vessels with focal extravasations of the blood vessels in between the renal tubules (Fig 9) at 30 days. Moreover, Colistin group 3 at 15 days, Proliferation and swelling in the endothelial cells lining the glomerular tuft of the glomeruli (Fig 10), focal mononuclear leucocytes inflammatory cells aggregations with congestion in the blood vessels and degeneration in the epithelial cells lining the renal tubules (Fig 11) at 30 days. Negative group showed apparent normal kidney tissues while those given lyszyme showed milder lesions than those given drugs only. The histopathological changes in liver due to the damaging effect of antibiotics specially when used in high concentration and /or prolonged administration, as recorded by [28]; [32] and [29].



H&E stained kidney sections chicken of chicken given antibiotics and or prebiotic showing :

Fig 6: chicken Kidney showing focal inflammatory cells infiltration in between the tubules and glomeruli.

Fig 7: chicken Kidney showing Focal lymphoid cells aggregations in between the renal tubules and glomulrai.

Fig 8: Kidney of chicken showing focal lymphoid cells aggregation in between the tubules and glomeruli.

Fig 9: Kidney of chicken Sever congestion of the blood vessels and focal renal hemorrhage.

Fig 10: Kidney of chicken showing focal inflammatory cells aggregation between the degenerated tubules.

Fig 11: Kidney of chicken showing proliferation and swelling in the endothelial cells lining the glomerular tuft.

Results of histopathology proved that groups given lyszyme showed milder liver and kidney lesions than those given drugs only. birds given combined drugs show more sever lesions than those given separate drug. Tylosin was more effective on liver, while colistin showed to be more effect on kidney. Administration of lysosime improve the adverse effect of drug on tested tissue sections.

It could be concluded that inspit of antibacterial effect of antibiotics on pathogenic microorganism, excessive use under our field conditions resulting in hepatic and kidney effect, birds given combined drugs show more sever lesions than those given separate drug. Tylosin was more effective on liver, while colistin showed to be more effect on kidney. Administration of lysosime improve the adverse effect of drug on tested tissue sections. Therefore, we advice to administer the used drugs in the recomended dose with prebiotic to get more better results.

REFERENCES

- [1] Schwalbe R, Steele-Moore L, Goodwin AC (2007): Antimicrobial Susceptibility Testing Protocols: CRC Press.
- [2] Adel Feizi ; Soroosh Babakhani and Hossein Nikpiran (2013): Comparative survey of tiamulin and tylosin in control of Mycoplasma gallisepticum in broiler chickens. Euro. J. Exp. Bio., 2013, 3(1):536-539
- [3] Lanckriet A., Timbermont L., De Gussem M., Marien M., Vancraeynest D., Haesebrouck F., Ducatelle R. and Van Immersee F. (2010): The effect of commonly used anticoccidials and antibiotics in a subclinical necrotic enteritis model. Avian Pathology. 39(1), 63-68.
- [4] Evans, M.E., Feda, D.J. and Rapp, R.P. (1999): Polymyxin B sulfate and colistin: old antibiotics for emerging multiresistant gram-negative bacteria. Annals of Pharmacotherapy, 33, 960-967.
- [5] Agnes Agunos, Dave Léger, Carolee Carson (2012): Review of antimicrobial therapy of selected bacterial diseases in broiler chickens in Canada. Canadian Vet. J; 53:1289-1300.
- [6] Chafik Redha Messai ; Khatima Ait-Oudhia ; D jamel Khelef ;Taha M ossadek Hamdi ;Nadia Safia Chenouf and Mohamed Ramzi Messai (2015): Serogroups and antibiotics susceptibility pattern of avian pathogenic Escherichia coli strains responsible for colibacillosis in broiler breeding farms in the east of Algeria. Afr. J. Microbiol. Res. Vol. 9(49), pp. 2358 – 2363.
- [7] Husaln, M.A. (2008): "Bacitracin, Glycopeptide Antibiotics, and the Polymyxins" In " Modern Pharmacology with Clinical Applications." 6th Edition. P: 554.
- [8] Michalopoulos, A. and Falagas, M.A. (2008): "Colistin and Polymyxin B in Critical Care" Crit Care Clin 24: 377– 391.
- [9] Muhammad Kashif Saleemi , Muhammad Fayyaz Ul Hussan, Muhammad Zargham Khan, Ahrar Khan, Rao Zahid Abbas and Arfan Ahmad (2014): Hemato-Biochemical Effects of Colistin Administered Intramuscularly in Growing Broiler Birds. Pak Vet J, 34(1): 78-81.
- [10] Donev B ; Angelov AK ; Vitanov S.(1978): Toxicity studies of Pharmachem's tylosin tartrate for broilers and turkeys. Vet Med Nauki. 1978;15(6):52-63.
- [11] Bonnie M. Marshall and Stuart B. Levy (2011): Food Animals and Antimicrobials: Impacts on Human Health. Clin Microbiol Rev. ;24(4):718-733.doi:10.1128/CMR.00002-11.
- [12] Adhiratha Boonyasiri; Teerawit Tangkoskul; Charkrapong Seenama; Jatuporn Saiyarin; Surapee Tiengrim and Visanu Thamlikitkul (2014): Prevalence of antibiotic resistant bacteria in healthy adults, foods, food

- animals, and the environment in selected areas in Thailand. *Pathog Glob Health*;108(5):235-245.doi:10.1179/2047773214Y.0000000148.
- [13] Mengmeng Zhang, Hong Zhang, Huixian Li, Furao Lai, Xiaofeng Li, Yuqian Tang, Tian Min, and Hui Wu (2016): Antioxidant Mechanism of Betaine without Free Radical Scavenging Ability. *J. Agric. Food Chem.*64, 7921–7930. DOI:10.1021/acs.jafc.6b03592.
- [14] J. Deng; B. Bl; Q. An; L. Kong; Q Wang; L. Tao and X. Zhang (2012): Effect of dietary inclusion of Lysozyme on growth performance and plasma biochemical parameters of rainbow trout (*Oncorhynchus mykiss*). *Aquaculture Nutrition*.18;332-339.doi:10.1111/j.1365-2095.2011.00902.x
- [15] Kawano, M., Namba, Y. & Hanaoka, M. (1981) Regulatory factors of lymphocyte-lymphocyte interaction. I. Con A-induced mitogenic factor acts on the late G1 stage of T-cell proliferation. *Microbiol. Immunol.* 25:505-515.
- [16] Wud M. E. Siddig; Mohammed A. A. Salim; Magdi Badawi ; Abdelgadir B. Mohamed ; Ishraga G. Ibrahim ; Mona K. Farid and Emad H. E. Konozy (2014): Regardless of the Antibiotic Group or Type, Misuse of antibiotics Adversely Impair Liver, Kidneys and Heart Functions "Biochemical and Histopathological Assessment". *Am. J. Pharm Health Res.* 2(5) 73-94. ISSN: 2321-3647.
- [17] Bancroft, J.D. and M. Gamble, (2008): *Theory and Practice of Histological Techniques*. 6th Ed., Churchill Livingstone, Elsevier, China.
- [18] Reitman, S.; and Frankel, S. (1957): A calorimetric method for determination of serum glutamic-oxalacetic and glutamic-pyruvic transaminases. *Amer. J. of clinic. Pathol.*, 28, 56-63.
- [19] Houot, O. (1985): interpretation of clinical laboratory test. Cited By siest, G., Henny,J.; schiele, F. and Young, D. s. in panphlete of Bio Merieux , France.
- [20] Meng-TszTsai; Ching-YiChen; Yu-HuiPan; Siou-HueiWang ; HarryJ.Mersmann; and Shih-TorngDing (2015): Alleviation of Carbon-Tetrachloride-Induced Liver Injury and Fibrosis by Betaine Supplementation in Chickens. Evidence-Based Complementary and Alternative Medicine. Volume 2015, Article ID 725379, 12 pages <http://dx.doi.org/10.1155/2015/725379>.
- [21] Liu, D., Guo, Y., Wang, Z. and Yuan, J. (2010): Exogenous lysozyme influence *Clostridium perfringens* colonization and intestinal barrier function in broiler chickens. *Avian Pathol.* 39: 17-24.
- [22] Zhang, G., Darius, S., Smith, S. R. and Ritchie, S. J. (2006): In vitro inhibitory effect of hen egg white lysozyme on *Clostridium perfringens* type A associated with broiler necrotic enteritis and its α -toxin production. *Lett. Appl. Microbiol.* 42:138–143.
- [23] Carletti M., Gusson F., Zaghini A., Dacasto M., Marvasi L. and Nebbia C. (2003): In vitro formation of metabolic-intermediate cytochrome P450 complexes in rabbit liver microsomes by tiamulin and various macrolides. *Vet. Res.* 34, 405-411.
- [24] Kowalski, C., Rolinski, Z., Zan, R. and Wawron, W. (2002): Pharmacokinetics of Tylosin in Broiler Chickens. *Polish Journal of Veterinary Science*, 5, 127-130.
- [25] Atef, M., El-Gendi, A.Y.I., Amer, A.M. and Kamel, G.M. (2009): Pharmacokinetic Assessment of Tylosin Concomitantly Administered with Two Anticoccidials; Diclazuril and Halofuginone in Broiler Chickens. *Advances in Environmental Biology*, 3, 210-218. <http://www.insipub.com/aensi/aeb/2009/210-218.pdf>.
- [26] Locke, D., Bush, M. and Carpenter, J.W. (1982): Pharmacokinetics and Tissue Concentrations of Tylosin in Selected Avian Species. *American Journal of Veterinary Research*, 43, 1807-1810.
- [27] Abu-Basha, E.A., Al-Shunnaq, A.F. and Gehring, R. (2012): Comparative Pharmacokinetics and Bioavailability of Two Tylosin Formulations in Chickens after Oral Administration. *Journal of the Hellenic Veterinary Medical Society*, 63, 159-165.
- [28] Roudaut, B. and Moretain, J.P. (1990): Residues of Macrolide Antibiotics in Eggs Following Medication of Laying Hens. *British Poultry Science*, 31, 661-675. <http://dx.doi.org/10.1080/00071669008417297>
- [29] Soliman, A.M. and Sedeik, M. (2016): Pharmacokinetics and Tissue Residues of Tylosin in Broiler Chickens. *Pharmacology & Pharmacy*, 7, 36-42. <http://dx.doi.org/10.4236/pp.2016.71006>
- [30] Ibrahim A. Ibrahim, Abd-El-Rehim A. EL-Ghannam, Abeer G. Ali, Dalia M. Hamed and Dina K. Arafa (2011): *Suez Canal Veterinary Medicine Journal (SCVMJ)*, XVI (2).
- [31] .Ahmed M. Soliman; Ahmed Ragab Elbestawy; and Sherin Ibrahim (2016): Pharmacokinetics, Bio-Equivalence and tissue residues of two oral colistin formulations in broiler chickens. *Int J Pharm Pharm Sci*, Vol 8, Issue 4, 166-170 .
- [32] Abenavoli L, Libri E, Bosco D, Gallo D, Luzzo F. (2012): Drug-induced liver injury. *Recenti Prog Med.*; 103(2): 79-84.