

Research Journal of Pharmaceutical, Biological and Chemical Sciences

Intracardiac Fungal Ball in A Preterm Newborn with Congenital Heart Disease Complicated by Right Atrial Mycetoma Obstructing Tricuspid Valve.

**Farooq Syed¹, Leslie Edward S Lewis², Ramesh Bhatt Y³, Jyothi Samanth⁴, and
Kiran Shetty^{5*}.**

¹Department of Pediatrics, KMC, Manipal University, Manipal, India.

²Professor, Neonatology, Department of Paediatrics, KMC, Manipal University, Manipal, India

³Associate Professor, Neonatology, Department of Paediatrics, KMC, Manipal University, Manipal, India

⁴Asst. Professor, Dept. of CVT (Cardio vascular technology), SOAHS (School of allied health sciences), Manipal University

⁵*PhD Scholar, Dept. of Cardiology, KMC, Manipal University, Manipal, India.

ABSTRACT

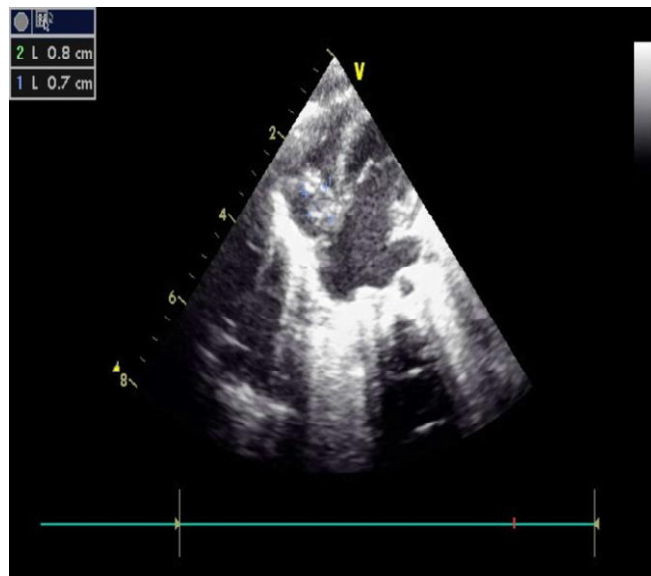
We present an unusually large intracardiac fungal ball for the first time in a preterm neonate measuring 18mm x 9 mm with congenital heart disease complicated by right atrial mycetoma attached to atrial septum protruding in and out of tricuspid valve producing tricuspid flow obstruction. Size of fungal ball rapidly progressed from 7mm x 8mm to 18mm x 9mm in a span of 8 days after starting systemic antifungals. Mycetoma was surgically removed salvaging RA septum.

Keywords: intracardiac fungal ball, new born, mycetoma, tricuspid valve.

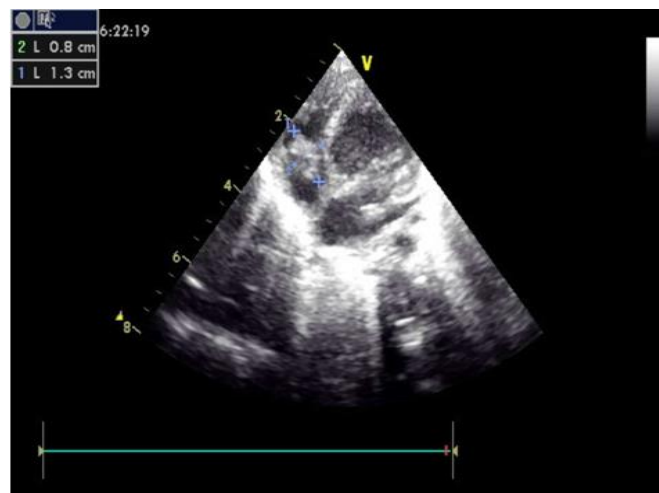**Corresponding author*

Case presentation

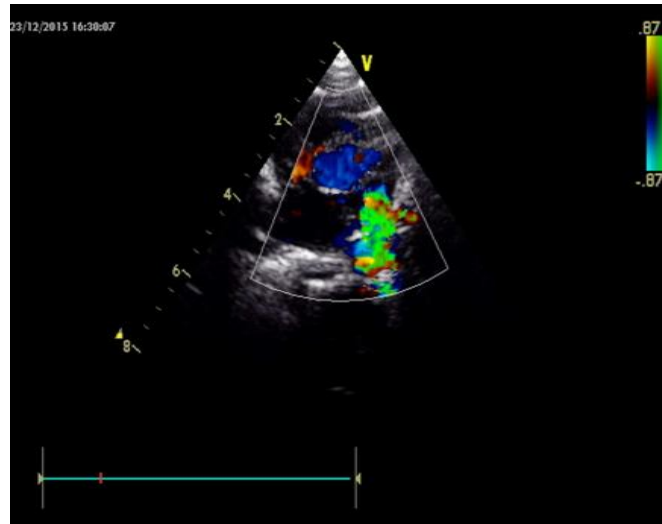
An early preterm (31 weeks) male baby born to a primi mother by normal vaginal delivery presented at 4 hours of life to our neonatal intensive care unit. He had tachypnea and respiratory distress (DOWN's score-7), hence intubated and ET surfactant (Curosurf) was given and connected to SIMV mode of ventilation later switched over to CPAP in view of persistent distress. Developed jaundice on day 4-given phototherapy for 24 hours, started on trophic feeds. On day 7 of life, developed tachycardia with bounding pulses, wide pulse pressure, and tachycardia, suspected to have hemodynamically significant PDA and was started on Lasix, fluid restriction. 2D ECHO confirmed the same and hence given a trial of Ibuprofen for PDA closure for 3days. Screening investigations done were suggestive of sepsis with total leucocyte count of 22,000cu.mm, platelet count of 35,000cu.mm. Hence, empirically started on antibiotics- Pipzo, Amikacin later graded up to Ceftazidime. In view of persisting murmur, repeat 2D ECHO showed large growth on tricuspid valve measuring 7mm x 8mm suggestive of vegetation. Same day as blood culture showed candida species, abdominal catheter was removed and systemic liposomal amphotericin B and fluconazole were started. Serial 2D echocardiography done showed increasing size of the fungal mass. Repeat 2D ECHO done on day 17 of life showed 18mm x 9mm large right atrial mass attached to right atrial septum protruding in and out of tricuspid valve producing tricuspid flow obstruction with RA and RV dilatation. Mycetoma was surgically removed salvaging RA septum, histopathology confirmed candida albicans. Baby is under regular follow-up with adequate weight gain.



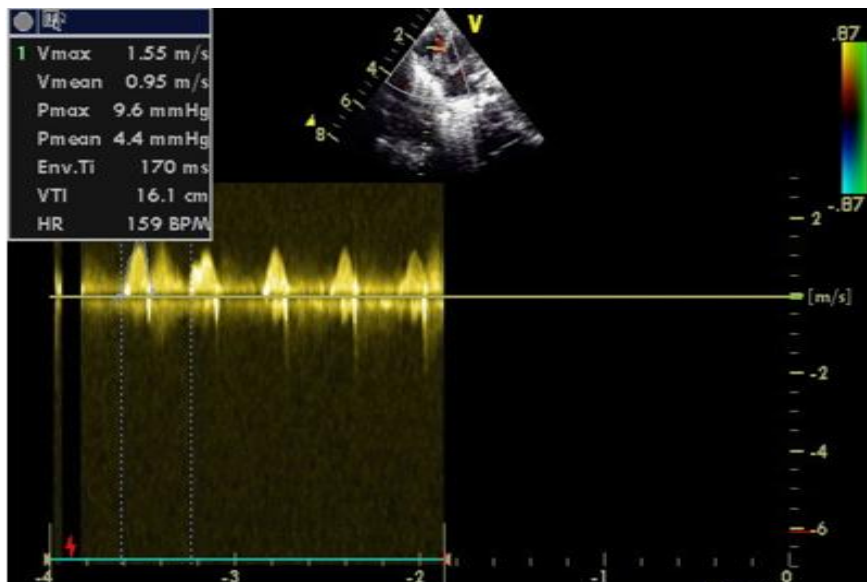
Subcostal view showing 8mmx 7mm mycetoma in RA Fungal ball in RA



Subcostal view showing 18mm x 9mm mycetoma in RA Fungal ball in RA



Parasternal short axis view showing significant PDA



Continuous wave Doppler showing moderate-severe TR Tricuspid regurgitation

DISCUSSION

Among antifungals, *Candida* species are the most common nosocomial infections in neonatal intensive care units especially in developing countries. Though *C. albicans* is the most common candidial infection, incidence of infections caused by non-*albicans* *Candida* species has been reported (1). Prematurity, premature rupture of membranes, intubation and mechanical ventilation, central venous catheters, broad-spectrum antibiotics, lack of enteral nutrition and prolonged parenteral nutrition are risk factors for invasive candidiasis. Systemic fungal infection is the third most frequent cause of late-onset sepsis in very low birth weight infants (2). A combination of Liposomal amphotericin and Fluconazole often used in cases of right atrial mycetoma (3). Depending on size and location of right atrial mycetoma, surgery has an important role in a select group of neonates. Right atrial mycetoma's are a potential source of embolism and hemodynamic compromise with obstruction of tricuspid inflow (3, 4, 5).

Candida sepsis is one of the most dreaded nosocomial infections in developing countries, if not treated aggressively may cause morbidities leading to mortalities in no time. Role of Liposomal amphotericin, Fluconazole and surgical management was evident from the literature. We suggest the threshold limit for serial

2D echocardiography has to be reduced especially in preterm/low birth weight babies with central venous cannula.

Hereby, we strongly recommend prophylactic anti-fungal in high risk neonates and early surgical intervention, due to rapid growth of right atrial mycetoma as evidenced in our case report.

REFERENCES

- [1] Lamagni, T.L., Evans, B.G., Shigematsu, M., et al. (2001) Emerging trends in the epidemiology of invasive mycoses in England and Wales (1990-9). *Epidemiology & Infection*, 126, 397-414.
- [2] Stoll, B.J., Hansen, N., Fanaroff, A.A., Wright, L.L., Carlo, W.A., Ehrenkranz, R.A., et al. (2002) Late onset sepsis in very low birth weight neonates: The experience of NICHD Neonatal Research Network. *Pediatrics*, 110, 285-291.
- [3] Stripeli F, Tsolia M, Trapali C, Papaevangelou V, Vlachos E, Pasparakis D, Constantopoulos A. Successful medical treatment of candida endocarditis with liposomal amphotericin B without surgical intervention. *Eur J Pediatr*. 2002; 167:469–470.
- [4] Levy I, Shalit I, Birk E, Sirota L, Ashkenzi S, German B, Linder N. Candida endocarditis in neonate: report of five cases and review of literature. *Mycoses*. 2006; 49:43–48.
- [5] Luchiani GB, Casali G, Viscardi F, Marcora S, Prioli MA, Mazzucco A. Tricuspid valve repair in an infant with multiple obstructive candida mycetomas. *Ann Thorac Surg*. 2005; 80:2378–2381.