

Research Journal of Pharmaceutical, Biological and Chemical Sciences

Morphometric Study of Suprascapular Notch and Scapular Dimensions with Their Clinical Implications.

Chandni Gupta, Vikram Palimar*, Akshay BM, and Sneha Guruprasad Kalthur.

Department of Anatomy, Kasturba Medical College, Manipal University, Manipal India, 576104.

*Department of Forensic Medicine & Toxicology, Kasturba Medical College, Manipal University, Manipal India, 576104.

ABSTRACT

The anatomical variations in the shape of suprascapular notch, and its transformation into a foramen by complete or partial ossification of the superior transverse scapular ligament, are well-known reasons of suprascapular nerve entrapment. So, the objective of this study is to measure various dimensions of suprascapular notch, glenoid cavity and scapula. The study was conducted on 60 dry scapulae of unknown sex. Width and length of scapula and glenoid cavity was measured. Width and depth of suprascapular notch was also measured. Glenoid cavity and suprascapular notch various shapes were also noted down. Distance of suprascapular notch from the supraglenoid tubercle and spinoglenoid notch was also noted down. Statistical analysis for all the parameter was done by using SPSS software. The mean length, width of scapula and glenoid cavity is 13.79, 9.40 and 3.78, 2.48cm respectively. The most common shape of glenoid cavity is pear shaped in 61.66% of cases. The width and depth of suprascapular notch is 0.88 and 0.67cm. The mean distance from supraglenoid tubercle and spinoglenoid notch to suprascapular notch is 2.96 and 2.11cm. Most common shape of suprascapular notch seen is U shape which was seen in 35% of cases. The measurements and shape of the glenoid cavity which were noted in this study will be useful for orthopaedic surgeons to select appropriate dimensions of the glenoid component for the shoulder replacement surgeries. The result of this study will also help the clinician in dealing with patients with suprascapular nerve entrapment.

Keywords: Glenoid cavity, Scapula, Suprascapular notch, Suprascapular nerve entrapment, Shoulder arthroplasty.

**Corresponding author*

INTRODUCTION

One of the clinically most key places on the scapula is the suprascapular notch (SSN). This structure is bridged by the superior transverse scapular ligament (STSL). The suprascapular nerve and vein run underneath this superior transverse scapular ligament, and above the ligament passes suprascapular artery. (1, 2, and 3) The suprascapular notch is a depression on the lateral part of the upper border of the scapula, medial to the coracoid process. Sometime this superior transverse scapular ligament (STSL), gets ossified and convert the suprascapular notch into a foramen which conveys the suprascapular nerve (SN) and vein to the supraspinatus fossa. (4, 5) Suprascapular nerve supplies muscular branches to the supraspinatus and infraspinatus, and cutaneous sensation to rotator cuff muscles, and ligamentous structures of the shoulder and acromioclavicular joints. Therefore, this notch is a significant landmark of the suprascapular nerve during arthroscopic shoulder surgeries. (6, 7)

Koepell HP and Thompson WA were the first persons who describe the suprascapular nerve entrapment syndrome. They stated that movements like abduction or horizontal adduction of the shoulder joint exert traction on the suprascapular nerve which thus leads to its compression against the superior transverse scapular ligament. (8)

The consequence of supra scapular nerve entrapment can be weakness in the arm, difficulty in external rotation and abduction, and finally it can lead to atrophy of the infraspinatus and supraspinatus muscles. This entrapment syndrome is generally seen in volleyball players and athletes who recurrently experience strain on their shoulder. Even the players like baseball players, weight lifters, tennis players, fencers, hunters who use bows, dancers, figure skaters and people whose profession need a lot of overhead work which involves extreme abduction and external rotation can have more chances of supra scapular nerve entrapment. (9, 10, 11, 12, 13)

Understanding of the shape and measurements of the glenoid cavity are vital in designing the suitable glenoid prosthesis for total shoulder replacement surgeries. Knowledge of variations in normal anatomy of glenoid is also crucial while assessing pathological disorders like osseous Bankart lesion and osteochondral defects etc. (14)

So, the aim of the present study is to measure various dimensions of supra scapular notch, glenoid cavity and scapula.

MATERIALS AND METHODS

The study was done on 60 dry scapulae of unknown sex. Out of 60 scapulae 28 were of right side and 32 were of left side. Width and length of scapula and glenoid cavity was measured. Width and depth of supra scapular notch was also measured. Glenoid cavity and supra scapular notch various shapes were also noted down. Distance of supra scapular notch from the supra glenoid tubercle and spino glenoid notch was also noted down.

The parameters were measured as follows using Vernier callipers- (Figure 1 and 2)

- Width of scapula- from the lowermost point of the glenoid to the vertebral border of the scapula.
- Length of scapula- from superior angle of scapula to inferior angle.
- Length of glenoid cavity- from the supra glenoid tubercle to the lowermost point of the glenoid.
- Width of glenoid cavity- measured at its widest distance from the midpoint of the anterior to the midpoint of the posterior rim of the glenoid cavity.
- Width of supra scapular notch- from the medial to the lateral border of the notch.
- Depth of supra scapular notch- the maximal vertical distance from the superior border to lowermost point of the supra scapular notch.
- Distance of supra scapular notch from the supra glenoid tubercle and
- Distance of supra scapular notch from the spino glenoid notch.

Statistical analysis for all the parameter was done by using spss software. Statistical correlation between right and left side was done using T- Test.

RESULTS

The mean of all parameters done on right and left scapulae is shown in table 1.

In total scapulae the mean length, width of scapula and glenoid cavity is 13.79, 9.40 and 3.78, 2.48cm. The width and depth of suprascapular notch is 0.88 and 0.67cm. The mean distance from supraglenoid tubercle and spinoglenoid notch to suprascapular notch is 2.96 and 2.11cm.

Various shapes of glenoid cavity and suprascapular notch are shown in chart 1 and 2.

In all 60 scapulae we found that suprascapular notch was absent in 1.66%, V- shaped in 5%, U- shaped in 35%, W- shaped in 3.33%, J- shaped in 31.66% and shallow in 15% of cases. In 5% of cases there was complete ossification of the notch and it was converted into foramen while in 3.33% there was incomplete ossification. (Figure 3 and 4)

In all 60 scapulae we found that in 10 scapulae (16.66%) the glenoid cavity was oval in shape while in 37 scapulae (61.66%) the glenoid cavity was pear shaped and in 13 scapulae (21.66%) it was inverted comma shaped. (Figure 5)

In the present study there was no significant correlation in any parameters of scapula on right and left side as in all the p value was > 0.05.

In the present study there was significant correlation between length of scapula and length of glenoid cavity as well as between length of scapula and depth of suprascapular notch as in all the p value was < 0.05 (P value-0.000).

In the present study there was also significant correlation between width of scapula and width of glenoid cavity as well as between width of scapula and width of suprascapular notch as in all the p value was < 0.05 (P value-0.000).

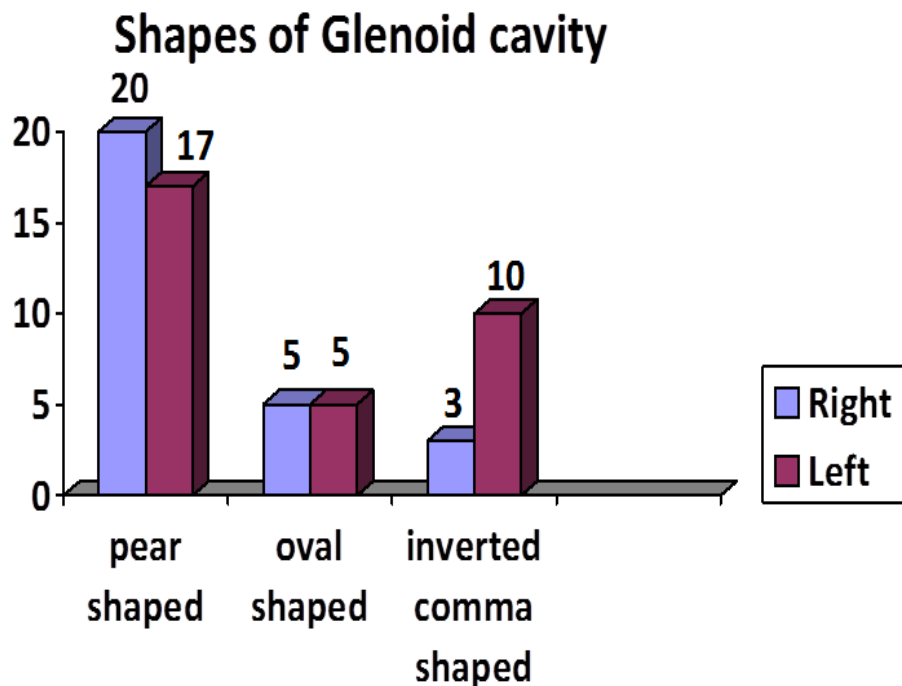


Chart 1. Showing number of scapula on right and left side having various shapes of glenoid cavity.

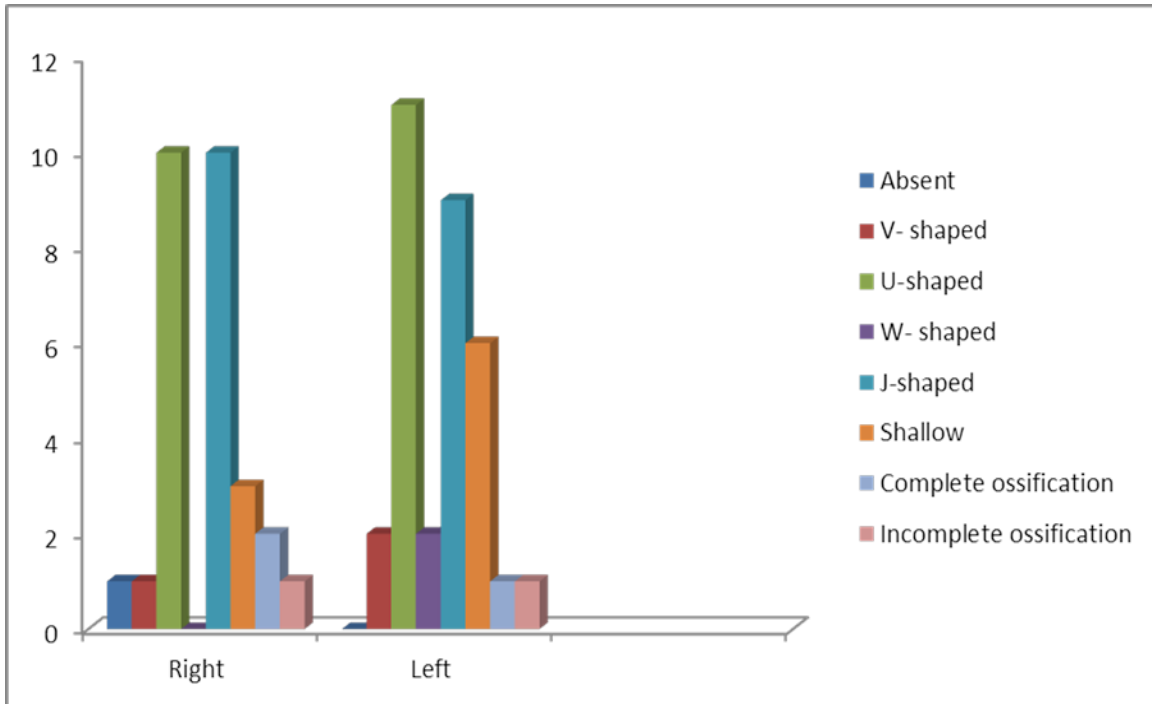


Chart 2. Showing number of scapula on right and left side having various shapes of suprascapular notch.

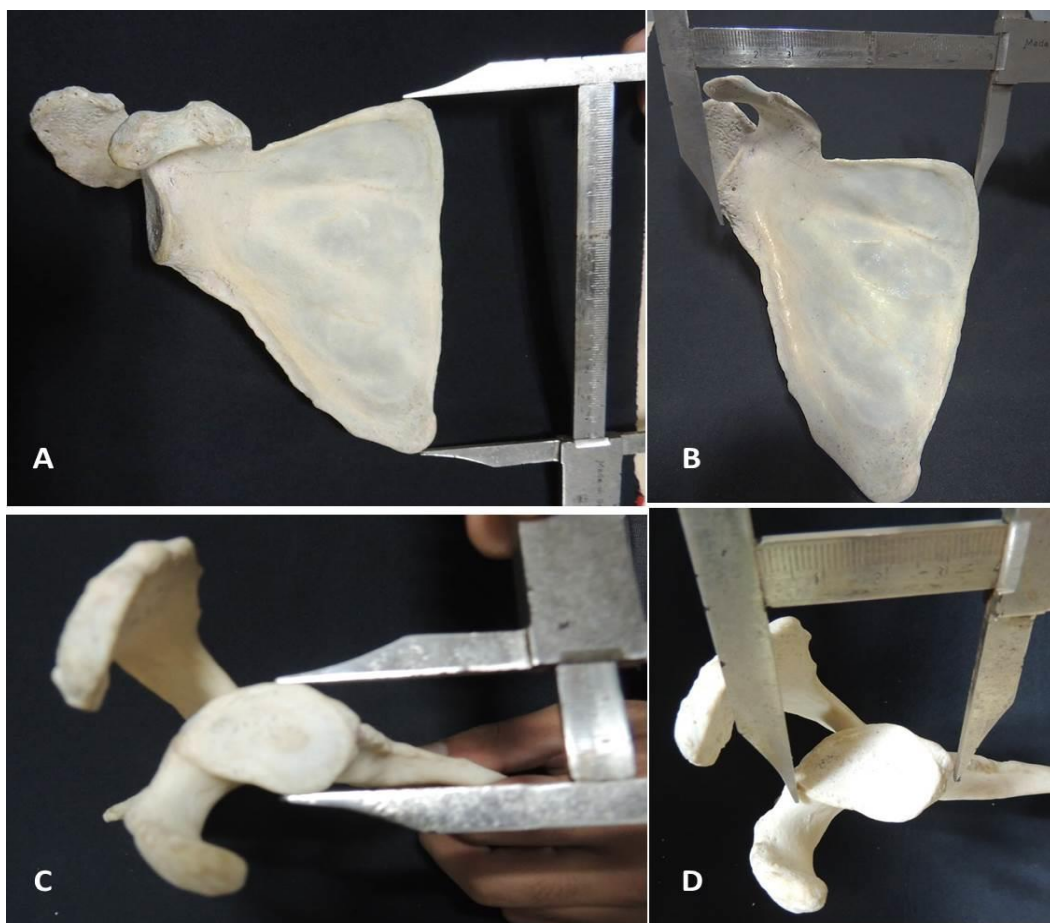


Figure 1. Showing various measurements done on scapua. A. Length of scapula, B. Width of scapula, C. Width of glenoid cavity, D. Length of glenoid cavity.

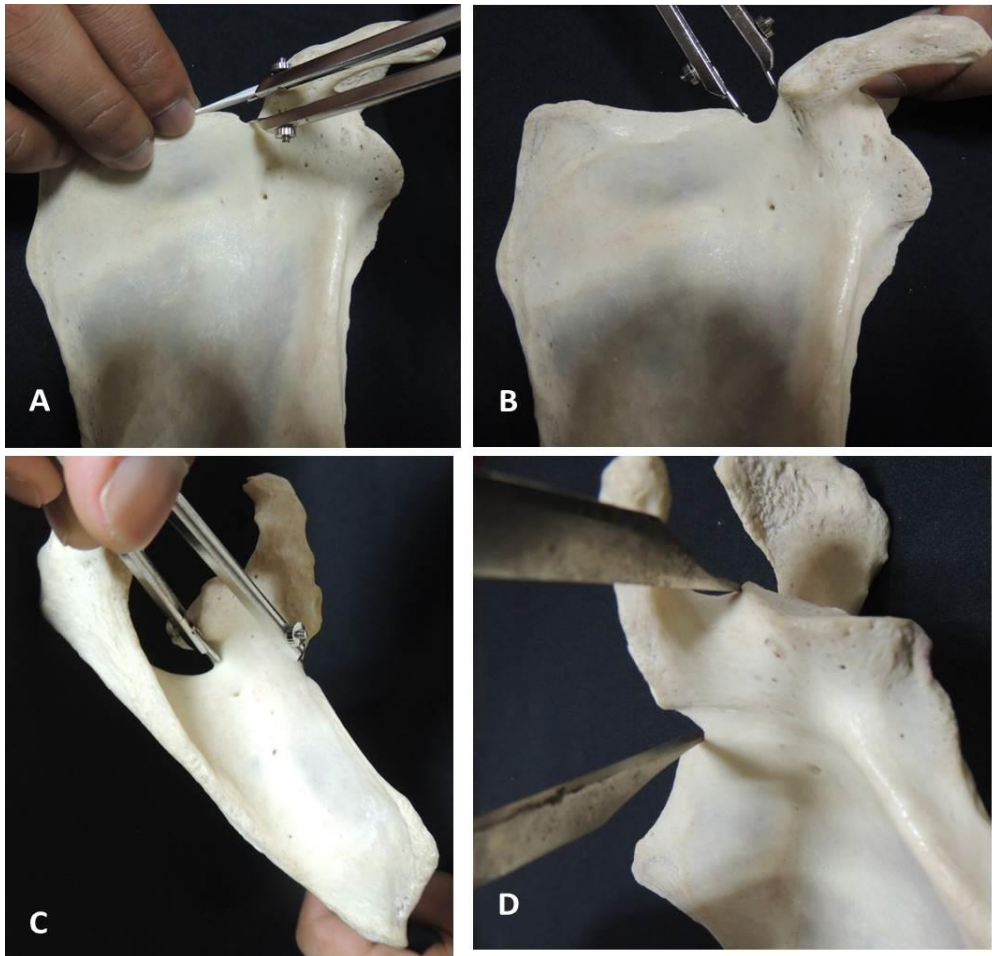


Figure 2. Showing various measurements done on scapua. A. Depth of suprascapular notch, B. Width of suprascapular notch, C. Distance from spinoglenoid notch to suprascapular notch, D. Distance from supraglenoid tubercle to suprascapular notch.

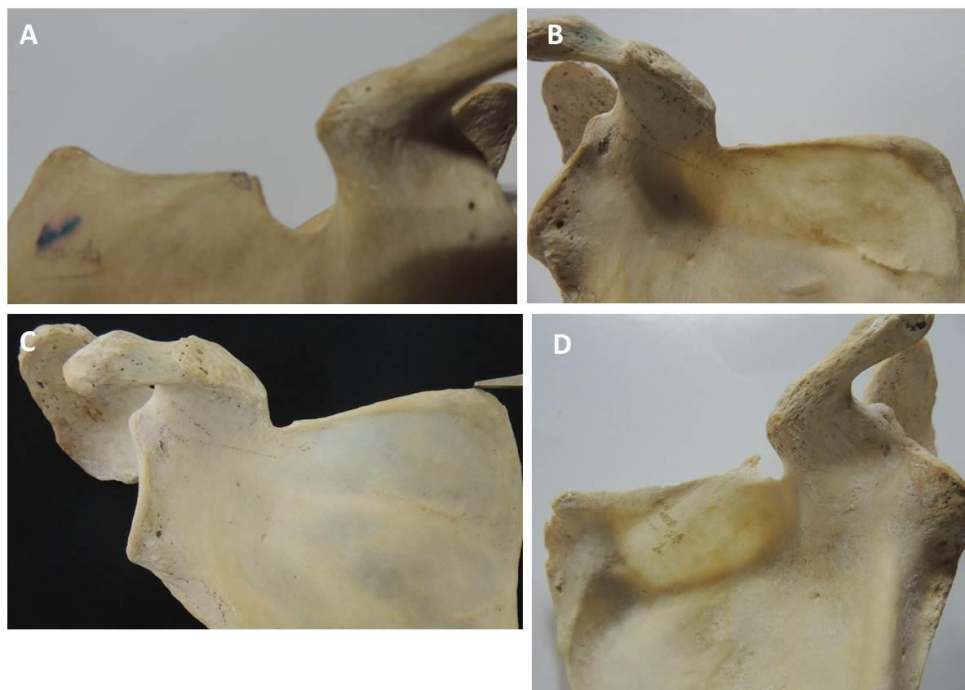


Figure 3. Showing various shapes of suprascapular notch. A. U shaped, B. Absent suprascapular notch, C. Shallow suprascapular notch, D. W shaped.

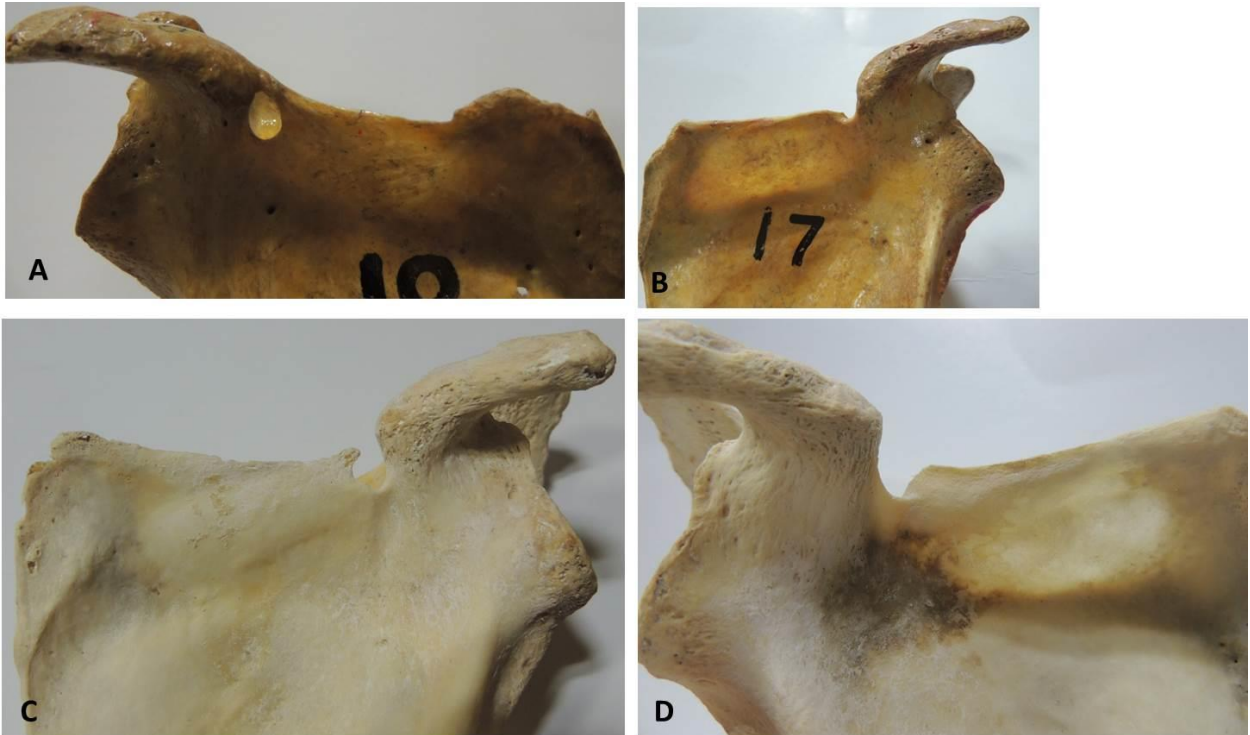


Figure 4. Showing various shapes of suprascapular notch. A. Complete ossification of suprascapular notch converting it into a foramen, B. J shaped, C Incomplete ossification of suprascapular notch, D. V shaped.

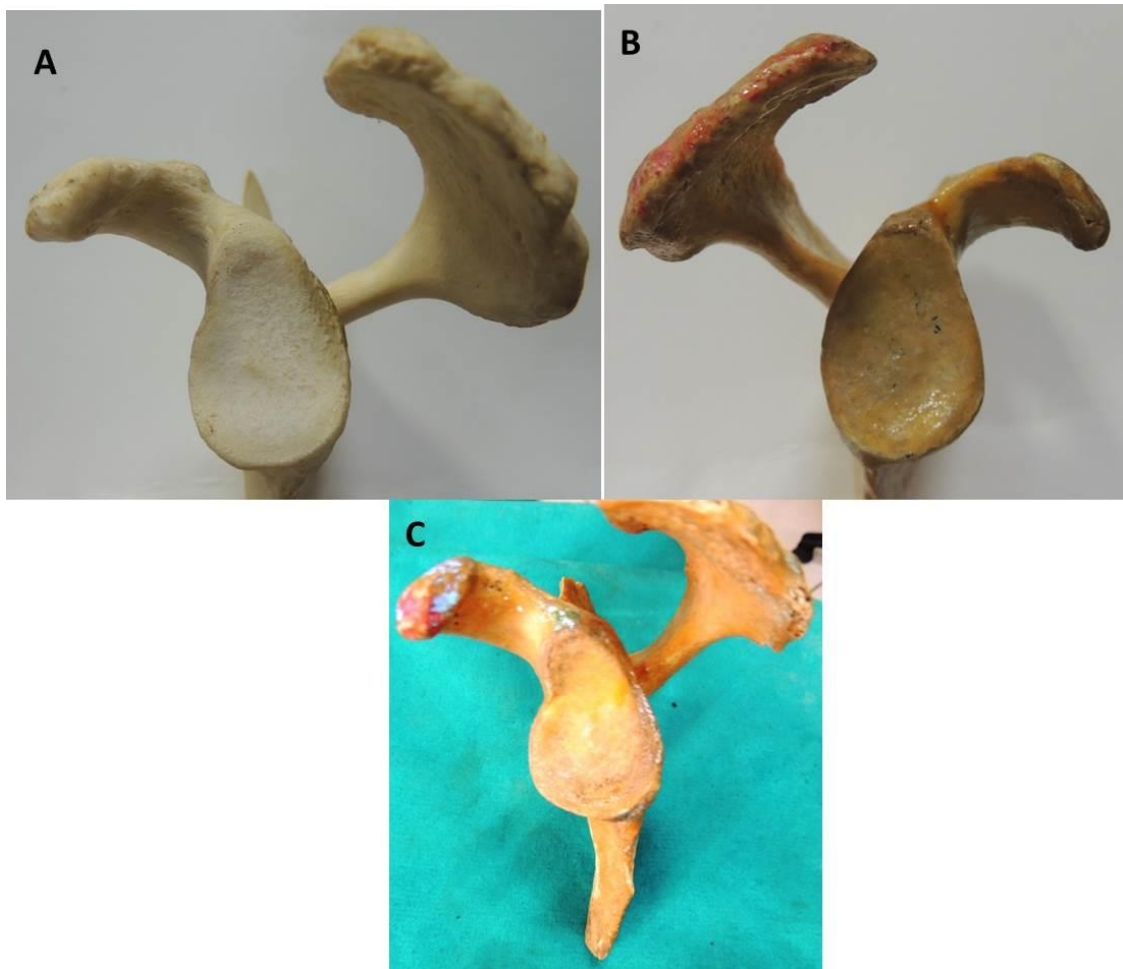


Figure 5. Showing various shapes of Glenoid cavity. A. Pear shaped, B. Oval, C Inverted comma shaped.

Table 1. Showing mean and range of all parameters done on scapula.

Parameters		Mean± SD (cm)	Range (cm)
Length of Scapula	Right	13.80±1.05	11.6-16
	Left	14.11±0.91	11.6-15.8
Width of Scapula	Right	9.35±0.78	7.8-10.8
	Left	9.45±0.78	8-11.1
Length of Glenoid cavity	Right	3.77±0.29	3.1-4.2
	Left	3.78±0.28	3-4.4
Width of Glenoid cavity	Right	2.4±0.19	2.1-2.8
	Left	2.48±0.24	2-3
Width of Suprascapular notch	Right	0.83±0.26	0.5-1.5
	Left	0.91±0.34	0.4-1.7
Depth of Suprascapular notch	Right	0.66±0.28	0.2-1.5
	Left	0.69±0.31	0.2-1.6
Distance of Supraglenoid tubercle to Suprascapular notch	Right	3±0.39	2.5-4
	Left	2.93±0.33	2.4-3.7
Distance of Spinoglenoid notch to Suprascapular notch	Right	2.02±0.38	1.1-2.9
	Left	2.18±0.32	1.5-2.8

DISCUSSION

The dimensions of the suprascapular notch is believed to play an important part in the predisposition for suprascapular nerve entrapment, supposing that in a small notch there are more chances of nerve impingement than in a large notch. (15) The shoulder joint is generally the most common joint in the body which can get dislocated easily. Dislocations with fractures of the glenoid cavity are also fairly common during trauma. (14) For treatment of such injuries, prosthesis and arthroplasty are commonly needed. The anatomical variations of shape and size of glenoid cavity of scapula is of utmost significance in understanding the diseases of rotator cuff, dislocation of the shoulder and to choose the appropriate size of the glenoid element in the shoulder arthroplasty. (16)

Soni G et al, Vandana R and Patil S and Lajja kantilal sutaria found 'U' shaped notch in 58, 35 and 38% Soni G et al and Lajja kantilal sutaria both of them found 'V' shaped notch in 7% while Vandana R and Patil S found that in 5.2% of cases, 'J' shaped notch in 27, 34.3 and 22%, notch was absent in 2,4,5 and 18%, and instead of a notch indentation was seen in 3,4,5 and 12% of cases. Soni G et al and Lajja Kantilal Sutaria both of them found that the notch was converted into a foramen by the complete ossification of the superior transverse scapular ligament in 3% while Vandana R and Patil S found that in 12.6% of cases and in all three studies incomplete ossification was seen in 11, 3 and 2% of cases. (17, 18 and 19) In present study we found U shaped in 35%, V- shaped in 5%, J- shaped in 31.66% , notch was absent in 1.66% and shallow in 15% of cases. In 5% of cases there was complete ossification of the notch and it was converted into foramen while in 3.33% there was incomplete ossification. Our results were almost similar to their results. In addition, we also found W- shaped notch in 3.33% of cases which Vandana R and Patil S found in 0.7% of cases.

Gosavi SN et al, Mamatha T et al and Rajput HB et al found the mean height of the glenoid cavity as 3.50, 3.36 and 3.47 cm on the right side and 3.53, 3.39 and 3.44cm on the left side. The Anteroposterior diameter was 2.41, 2.33 and 2.33cm on the right and 2.39, 2.30 and 2.29 cm on the left side. (14, 20 and 21) Gosavi SN et al, Mamatha T et al found in 49.9, 46% glenoid cavities were pear shape, 38, 20% were oval and 12.05, 34% were of inverted comma shape. (14, 20) In the present study we found the mean height of the glenoid cavity as 3.77 cm on the right side and 3.78cm on the left side. The Anteroposterior diameter was 2.4cm on the right and 2.48 cm on the left side. In our study we found that 61.66% glenoid cavities were pear shaped, in 16.66% were oval and in 21.66% it was inverted comma shaped. Our results were almost similar to their results.

Vandana R and Patil S found the mean distance from supraglenoid tubercle to suprascapular notch as 2.73cm while in our study the mean distance is 2.96 cm. (19)

As the complete ossification of superior transverse scapular ligament can lead to the formation of suprascapular foramen which can thus lead to suprascapular nerve entrapment syndrome and even it can also be caused by other morphometric variations of suprascapular notch, the information on such variations is important for surgeons to make the correct diagnosis and also for planning the best appropriate surgical interventions. (22)

The results of the present study will benefit the physician in treating the patients with suprascapular nerve entrapment and the data on glenoid cavity will help the orthopaedicians in selecting the correct glenoid component in shoulder arthroplasty.

REFERENCES

- [1] Barwood SA, Burkhart SS, Lo IK. Arthroscopic suprascapular nerve release at the suprascapular notch in a cadaveric model: an anatomic approach. *Arthroscopy*. 2007;23: 221–5.
- [2] Harmon D, Hearty C. Diameter of suprascapular nerve in the suprascapular notch. *Pain Phys*.2008;11:263–4.
- [3] Lafosse L, Tomasi A, Corbett S, Baier G, Willems K, Gobezie R. Arthroscopic release of suprascapular nerve entrapment at the suprascapular notch: technique and preliminary results. *Arthroscopy*. 2007; 23:34–42.
- [4] Aajmani ML. The cutaneous branch of the human suprascapular nerve. *J Anat*. 1994; 185:439–42.
- [5] Standring S, Ellis H, Healy J, Johnson D, Williams A. *Gray's Anatomy - The Anatomical Basis of Clinical Practice*. 39th Ed. New York: Elsevier Churchill Livingstone; 2005. Pectoral girdle, shoulder region and axilla; pp. 821–2.
- [6] Bigliani, Dalsey RM, McCann PD, April EW. An anatomical study of the suprascapular nerve. *Arthroscopy*. 1990;6: 301–5.
- [7] Shishido H, Kikuchi S. Injury to the suprascapular nerve during shoulder joint surgery: an anatomical study. *J Shoulder Elbow Surg*. 2001; 10: 372–6.
- [8] Kopell HP, Thompson WA. Pain and frozen shoulder. *Surg Gynecol Obstet* 1959; 109:92-96.
- [9] Antoniou J, Tae SK, Williams GR, Bird S, Ramsey MJ, Iannotti JP. Suprascapular neuropathy. Variability in the diagnosis, treatment, and outcome. *Clin Orthop Rel Res*. 2001; 386:131–8.
- [10] Cummins CA, Messer TM, Nuber GW. Suprascapular nerve entrapment. *J Bone Joint Surg*. 2000; 82-A: 415–24.
- [11] Edeland HG, Zachrisson BE. Fracture of the scapular notch associated with lesion of the suprascapular nerve. *Acta Orthop Scand*. 1975; 46(758):763.
- [12] Ferretti A, Cerullo G, Russo G. Suprascapular neuropathy in volleyball players. *The Journal of Bone Joint Surg AM*. 1987;69:260–3.
- [13] Vastamaki M GH. Suprascapular nerve entrapment. *Clin Orth Rel Res*. 1993;297(135):143.
- [14] Mamatha T, Pai SR, Murlimanju BV, Kalthur SG, Pai MM, Kumar B. Morphology of glenoid cavity. *Online J health Allied Scs*. 10(3), 2011, 7.
- [15] Rengachary SS, Burr D, Lucas S, Khatab HM, Mohn MP, Matzke H. Suprascapular entrapment neuropathy: a clinical, anatomical and comparative study, Part 2: anatomical study. *Neurosurg*. 1979; 5:447-451.
- [16] Rajput HB, Vyas KK, Shroff BD. A study of morphological patterns of the glenoid cavity of scapula *National J of Medical Research*, 2012; 2(4): 504-507.
- [17] Soni G, Malik V, Shukla L, Chhabra S, Gaur N. Morphometric Analysis of the Suprascapular Notch. *The Internet Journal of Biological Anthropology*. 2012; 5(1): DOI:10.5580/2B19.
- [18] Lajja kantilal sutaria. Morphology and morphometric analysis of suprascapular notch. *International Journal of Biomedical and Advance Research*.2013;4(1): 10.7439/ijbar.v4i1.891.
- [19] Vandana R, Patil S. Morphometric study of Suprascapular Notch. *National journal of clinical anatomy*. 2013;2(3):140-144.
- [20] Gosavi SN, Jadhav SD, Garud RS. Morphometric study of Scapular glenoid cavity in Indian population. *IOSR Journal of Dental and Medical Sciences*. 2014; 13(9):67-69.
- [21] Rajput HB, Vyas KK, Shroff BD. A study of morphological patterns of glenoid cavity of scapula. *National journal of medical research*. 2012;2(4):504-507.
- [22] Kannan U, Kannan NS, Anbalagan J and Rao S. Morphometric Study of Suprascapular Notch in Indian Dry Scapulae with Specific Reference to the Incidence of Completely Ossified Superior Transverse Scapular Ligament. *J Clin Diagn Res*. 2014; 8(3): 7–10.