

# Research Journal of Pharmaceutical, Biological and Chemical Sciences

## Renal Arterial Collar.

Ashwini LS\*, SN Somayaji, Mohandas Rao KG, and Jyothsna Patil.

Department of Anatomy, Melaka Manipal Medical College (Manipal Campus) Manipal University, Madhav Nagar, Manipal, Karnataka State, INDIA. 576104.

### ABSTRACT

Dissection of a 60-year-old male cadaver revealed double renal arteries on both the sides. On right side, the superior and inferior renal arteries were arising from the abdominal aorta at the level of L1 and L2 vertebrae respectively. From their origin, the superior renal artery was passing behind the inferior vena cava and the inferior renal artery was passing in front of inferior vena cava to enter into the hilum of the right kidney. Thus both superior and inferior renal arteries were forming an arterial collar around the inferior vena cava. On the left side, the two renal arteries were arising together from the abdominal aorta. The embryological basis for the above variation is probably due to the persistence of multiple mesonephric branches of dorsal aorta passing dorsal and ventral to the developing inferior vena cava (subcardinal part). Such arterial collar around the inferior vena cava may compress it causing obstruction to the venous return from the lower part the body.

**Key words:** Abdominal aorta, renal artery, inferior vena cava, venous return

*\*Corresponding author*

## INTRODUCTION

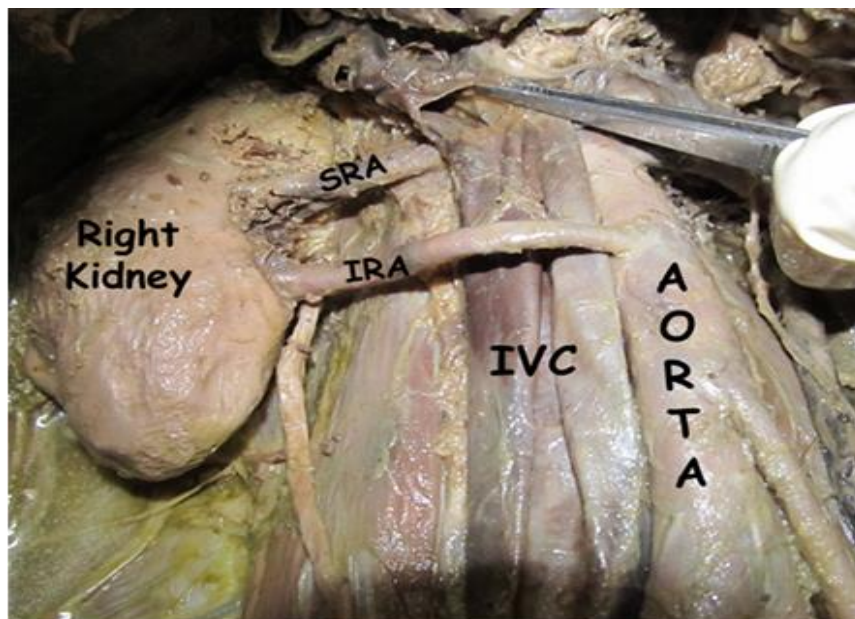
Normally, the renal arteries arise from the abdominal aorta at the level of L2 vertebra and pass behind the renal vein to enter the hilum of the kidney. On right side, the renal artery passes behind the inferior vena cava as it reaches the kidney. Bilateral double renal arteries are common and they usually arise from the abdominal aorta. However, the renal arteries forming an arterial collar around the inferior vena cava is a unique variation which is being reported in the present case.

## MATERIALS AND METHODS

The study involved the dissection of 60-year-old male cadaver of south Indian origin at the Department of Anatomy, Melaka Manipal Medical College, Manipal University, Manipal. The dissection procedures for abdomen and pelvis were followed according to the Cunningham's Manual of Practical Anatomy [1]. The body was preserved by the injection of formalin based preservative (10% formalin) and stored at 4° C.

## CASE REPORT

During routine dissection for medical undergraduate students, a rare case of bilateral double renal arteries was observed in a 60-year-old male cadaver. On right side, the superior and inferior renal arteries were arising from the abdominal aorta at the level of L1 and L2 vertebrae respectively. From their origin, the superior renal artery was passing behind the inferior vena cava and the inferior renal artery was passing in front of inferior vena cava to enter into the hilum of the right kidney. Thus both superior and inferior renal arteries were forming an arterial collar around the inferior vena cava. On the left side, the two renal arteries were arising together from the abdominal aorta.



**Figure.1:** Dissection of the posterior abdominal wall on right side to show the unusual origin of superior renal artery (SRA) & inferior renal artery (IRA) from the descending aorta (AORTA) to form an arterial collar around the inferior vena cava (IVC).

## DISCUSSION

Incidence of multiple renal arteries has been reported to be 20.2% and 19% on right and left sides respectively [2]. The past studies have reported the presence of two renal arteries on the right side, originating from the abdominal aorta [3]. The circumaortic renal collars formed by double renal veins on left side in which the renal veins form a collar around the descending aorta before draining into inferior vena cava have been

reported by many authors [4,5]. However, a case of the double renal arteries arising from the descending aorta forming an arterial collar around the inferior vena cava is being reported for the first time to the best of our knowledge. Such arterial collar around the inferior vena cava can lead to severe complication of its compression causing obstruction to the venous return from the lower part of the body.

Precise knowledge of the renal artery and its branching pattern is useful for surgeons performing nephrectomies and renal transplantations. Accessory renal arteries in 30-35% cases may enter the upper or lower poles of the kidneys. The main clinical importance of these arteries which are entering through lower pole is that they may obstruct the ureter leading to hydronephrosis [3]. The anatomical knowledge of accessory or multiple arteries is essential before performing any transplantation surgeries, where microvascular techniques are employed to reconstruct the renal arteries [6]. Intra-operative bleeding and post-surgical complications are often observed as a result of multiple or accessory renal arteries. A careful suturing is required by the surgeons in the cases having accessory or multiple renal arteries [7].

The embryological basis for the variations reported in the present case is probably due to the persistence of multiple mesonephric branches of dorsal aorta passing dorsal and ventral to the developing inferior vena cava (subcardinal part).

### CONCLUSION

The bilateral double renal arterial anomalies are very common but formation of arterial renal collar around inferior vena cava by the renal arteries is a unique observation. Recently, laproscopic surgeries and renal transplantations are gaining wide popularity and it is essential for clinicians to have a proper knowledge about the renal arterial anomalies. Thus, present case may be important for the surgeons and clinician to conduct the surgical and radiological procedures involving the multiple or accessory renal arteries.

### REFERENCES

- [1] Romanes GJ. Cunningham's Manual of Practical Anatomy 2000, 15 (2): pp .167-72.
- [2] Janscheck EC, Rothe AU, Holzenbein TJ et al. Urology 2004; 63 (4): 660-664.
- [3] Singh G, Ng YK, Bay BH. Clin Anat 1998; 11 (6): 417-420.
- [4] Ilkan T, Hüseyin GT , H. Hamdi C, Musturay K. International journal of experimental and clinical anatomy 2008;2: 72-6.
- [5] Rathode K, Ahmed N, Raut A. J Postgrad Med 2004; 50:77-78.
- [6] Brannen GE, Bush WH, Correa RJ Jr, Gibbons RP, Cumes DM. J Urol 1982; 128 (1): 112-115.
- [7] Srijit Das. Bratisl Lek Listy 2008; 109 (4): 182-184.