

Research Journal of Pharmaceutical, Biological and Chemical Sciences

A Comparative Cross-Sectional Study of Pre-implant Site Assessment Using Ridge Mapping and Orthopantomography (OPG) with cone Beam Computed Tomography (CBCT)

Prashanti Eachempati¹, Ong Joe Vynne², Asairinachan Annishka², Fickry Siti Syazwani Fickry², Md Alwi Naurah², , Jose Joy Idiculla³ , Htoo Htoo Kaw Soe⁴

¹ Department of Prosthodontics, Faculty of Dentistry, Melaka Manipal Medical College

² BDS completed students, Faculty of Dentistry, Melaka Manipal Medical College

³Department of Oral Pathology, Faculty of Dentistry, Melaka Manipal Medical College

⁴Department of Community Medicine, Faculty of Medicine, Melaka Manipal Medical College

ABSTRACT

This study aims to compare Ridge Mapping and OPG with CBCT for implant site assessment. Specifically, it aims to determine the accuracy of measured alveolar bone height when using OPG compared to CBCT, the accuracy of measured alveolar bone width when using Ridge Mapping compared to CBCT and the significance of the difference in measurement between OPG and Ridge Mapping with CBCT. A comparative study was done among a conveniently selected group of 30 implant sites. OPG and CBCT scans were taken, available bone height at the implant sites were measured and compared. Ridge Mapping was done using a number 60 K-file and the measurements were transferred to a sectioned dental cast on which the bone width was measured. The width obtained was then compared to that of the CBCT. There was a high correlation between CBCT and OPG using Pearson's correlation (0.9) with a mean difference of 0.7mm, showing no clinical significance. There was a moderate correlation between CBCT and Ridge Mapping using Pearson's correlation (0.5) with a mean difference of 1.2mm which is of no clinical significance. There is high correlation between the measured bone heights obtained from OPG compared to that of CBCT. There is also a moderate correlation between the measured bone widths obtained from Ridge Mapping compared to that of CBCT. No clinical significance in the difference of measurements obtained between OPG and Ridge Mapping with CBCT.

Keywords: Dental implants, Orthopantomography, Cone Beam Computed Tomography, Ridge Mapping

**Corresponding author*

INTRODUCTION

The use of dental implants to restore orofacial form and function is the result of the remarkable developments in dentistry. The increasingly sophisticated imaging techniques used in all phases of implant treatment contributes to the predictable results of implant systems. The advancements of these imaging techniques contribute information in every stage of treatment. [1]

In the placement of dental implants, pre-implant evaluation must be done before hand to ensure that the patient has an adequate bone height and bone width. This is to determine the size of the implant suitable to be placed, to ensure there is sufficient bone to support the implant placed, to aid in the success of the implantation and to ensure there is a minimum of 2mm distance from the implant to any vital anatomical structure. [2]

This pre-implant evaluation can be divided into clinical methods as well as radiographic analysis. For clinical methods of analysis, ridge mapping and direct surgical exposure can be done. There are various types of radiographic analysis that are available, either analog or digital, 2-dimensional or 3-dimensional.

A recent advancement in the radiographic analysis includes Cone Beam Computed Tomography where a conical beam is used and the image can be reconstructed at any angle using specific software.

The purpose of this study is to compare the pre-implant site assessment using ridge mapping and OPG with CBCT.

MATERIALS AND METHODOLOGY

A comparative study was done among a randomly selected group of implant patients and the measurements of available bone height and width were compared from a CBCT scan to that of OPG and ridge mapping (Figure 1 and 2). The reference population of the study were all patients that visited Melaka-Manipal Medical College with a source population being all patients that required dental implants in the Faculty of Dentistry, Melaka-Manipal Medical College. A pilot study was conducted with 10 of the dental implant patients to determine a suitable sample size where $\alpha = 0.05$ and power = 90%.

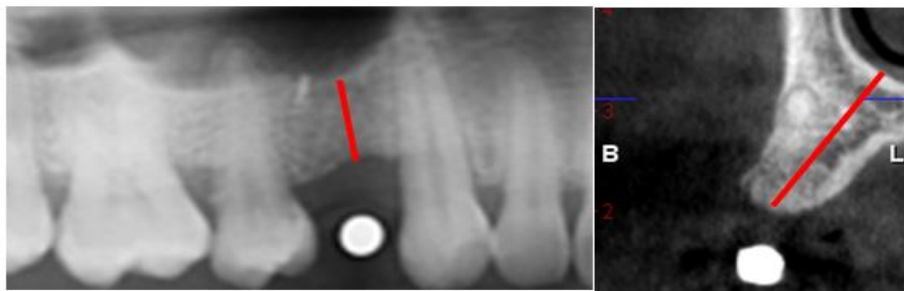

Figure 1: Bone height was measured from OPG & CBCT using Romexis 3.0 IR software and compared




Figure 2: Bone width was measured from Ridge Mapping & CBCT which was later compared

We included patients with missing teeth seeking dental implant placement, who consented to take part in our study and excluded radiographs that did not allow accurate measurements to be made.

Ethical approval was obtained from the Human and Ethics Committee of Faculty of Dentistry, Melaka-Manipal Medical College. Patient information sheet was prepared and distributed to the patients. Prior to the study, informed and written consent was obtained from the patient.

After conducting a pilot study, sample size was calculated using Pearson’s correlation coefficient and a value of 8 for OPG and 37 for ridge mapping were obtained as an ideal sample size. The higher sample of 37 was taken to proceed with the study. Purposive sampling was used, where the CBCT and OPG of the patient was taken using Planmeca 3Ds CBCT System (Helsinki, Finland) under the exposure of 90kVp and 14mA and images were measured and analysed using Romexis 3.0 IR. Before proceeding with ridge mapping, an alginate impression of the respective jaw was made and the cast was poured. Acrylic stents were fabricated on the casts obtained in which three buccal and lingual holes were drilled, located at 2, 4 and 6mm from a point that corresponds with the crest of the alveolar ridge [3, 4]. An additional measurement point was made at the apex of the crest of the alveolar ridge as shown in Figure 3. Local anaesthesia was then administered by using local infiltration technique on both buccal and lingual mucosa at the implant site to be measured. The acrylic stent was placed over the patient’s edentulous site and a number 60 endodontic K-file was used to penetrate the patient’s mucosa at the respective points made with the acrylic stent. The endodontic K-file was pierced into the mucosa until bone was reached and the rubber stopper was placed to contact the soft tissue overlying the ridge and mark the depth of penetration, thus indicating the thickness of the overlying soft tissue. The measurement was then recorded and this was repeated at the remaining 6 points of the ridge. The cast that was made earlier was sectioned at the implant site. The recorded measurements were transferred onto the cross section of the cast at their respective locations and this allowed the mapping of the underlying bone. The width of available alveolar bone was then measured.

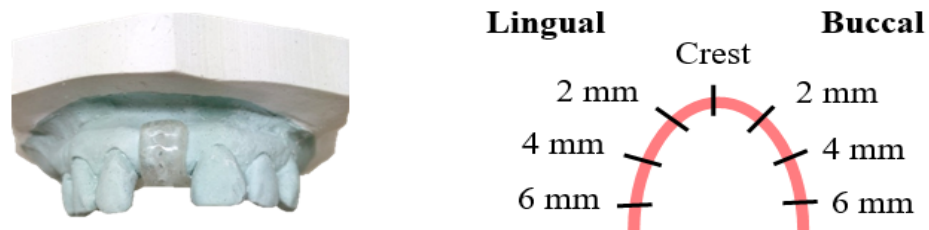


Figure 3: Alginate impression was made & an acrylic stent was fabricated on the dental cast & holes drilled on the stent [3,4]

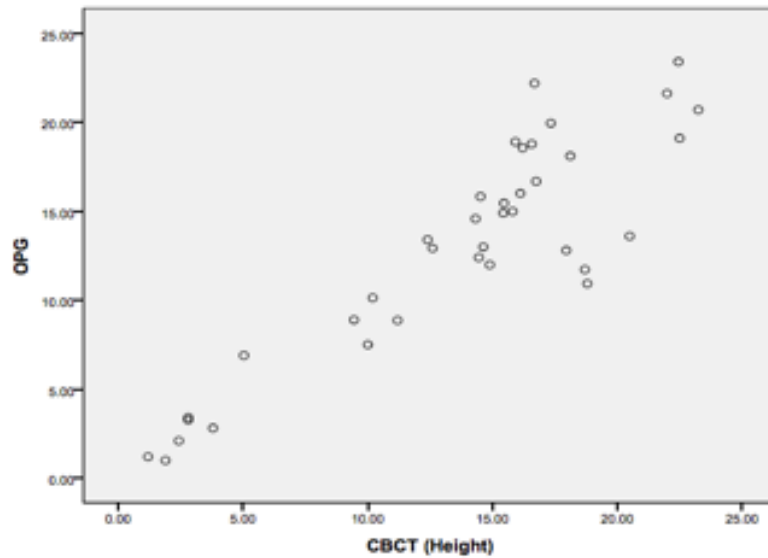
From the data collected, statistical analysis was done using Epi Info version 7 and SPSS Version 12. Pearson’s correlation coefficient was used.

RESULTS

The statistical values were calculated based on the analysis of 37 implant sites from a total of 12 subjects with 37 implant sites. Out of the 37 implant sites, 5 were from the anterior maxilla, 22 from the posterior maxilla and 7 were from the posterior mandible.

The scatter plot as shown in Graph 1 shows a high strength positive association between OPG and CBCT readings as the plots are closely associated to one another. From the correlations table depicted in Table 1, it can be seen that the correlation coefficient (r) equals 0.90, indicating a high strength correlation with a p-value of < 0.001, indicating that the data collected is highly significant. Based on Table 2, the data collected

from CBCT and OPG readings, the mean was found to be 0.7mm. The box-and-whisker plot in Figure 4 depicts that there is an underestimation of bone height at 37 implant sites, with the median being at 0.12 mm.



Graph 1: Scatter Plot showing the association between CBCT and OPG measurements

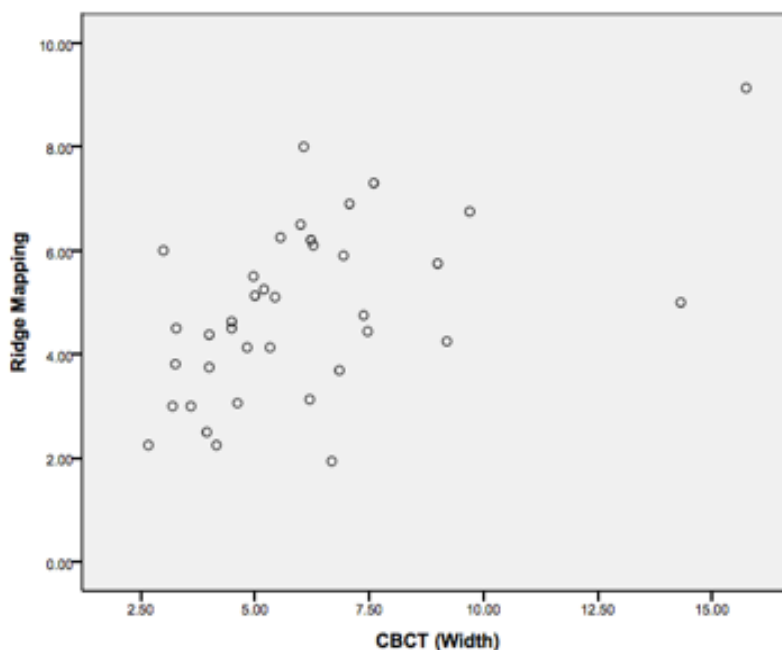
Case Processing Summary

	Cases					
	Valid		Missing		Total	
	N	Percent	N	Percent	N	Percent
Mean Difference (Height)	37	100.0%	0	.0%	37	100.0%

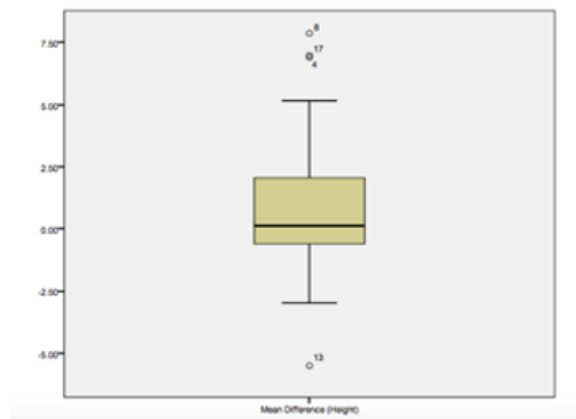

Figure 4: Box-and-whisker plot showing the median value and interquartile range of mean difference between OPG and CBCT.

Based on Graph 2, the scatter plot shows a moderate strength positive association between ridge mapping measurements and CBCT readings as the plots are widely separated from one another. Referring to Table 3, it can be seen that the correlation coefficient (r) equals 0.53, indicating a moderate strength correlation with a P-value of 0.001, indicating that the data collected is statistically significant. Based on the results obtained from the study, Table 4 shows that mean difference of ridge mapping measurements compared to CBCT readings is 1.2 mm with a median being at 0.34 mm. The box-and-whisker plot in Figure 5 depicts that there is an underestimation of bone height in the 37 implant sites.



Graph 2: Scatter Plot showing the association between CBCT and Ridge Mapping measurements

Case Processing Summary

	Cases					
	Valid		Missing		Total	
	N	Percent	N	Percent	N	Percent
Mean Difference (Width)	37	100.0%	0	.0%	37	100.0%


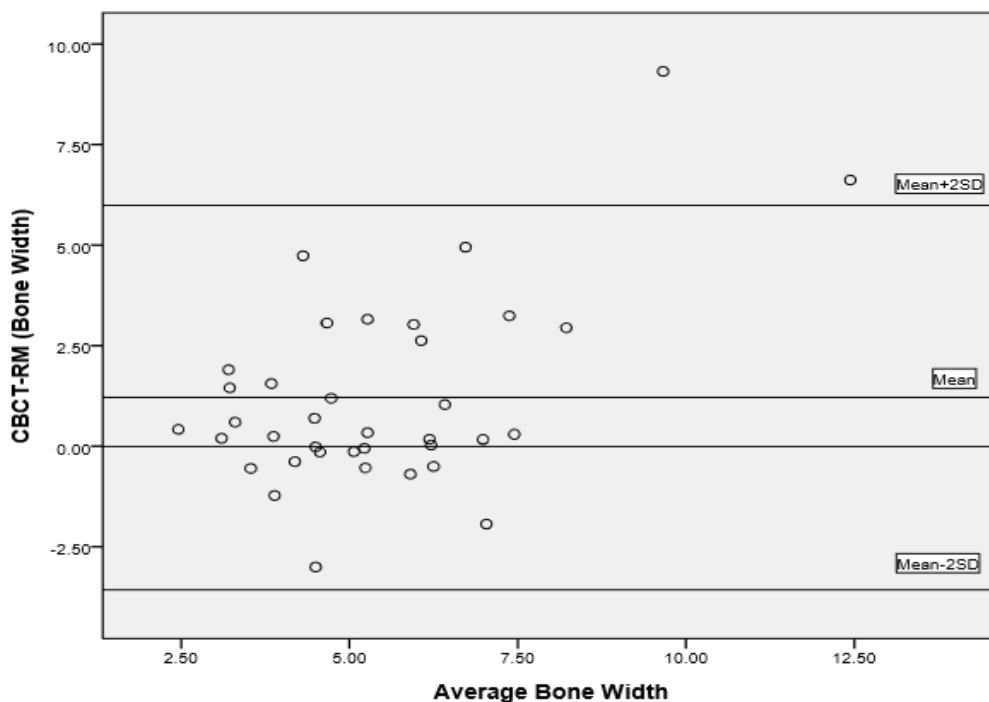


Figure 5: Box-and-whisker plot showing the median value and interquartile range of mean difference between Ridge Mapping and CBCT.

A further test was done to determine the correlation between the bone width measurements obtained from ridge mapping and CBCT readings. A Bland and Altman plot was made as shown in Graph 3. The plot shows 94.6% of the measurements were within the mean $\pm 2SD$, thus showing a high level of agreement between the measurements obtained from ridge mapping and CBCT.



Graph 3: Bland-Altman plot shows 94.6% of measurements within mean ±2SD thus showing a high level of agreement between the measurements of RM and CBCT

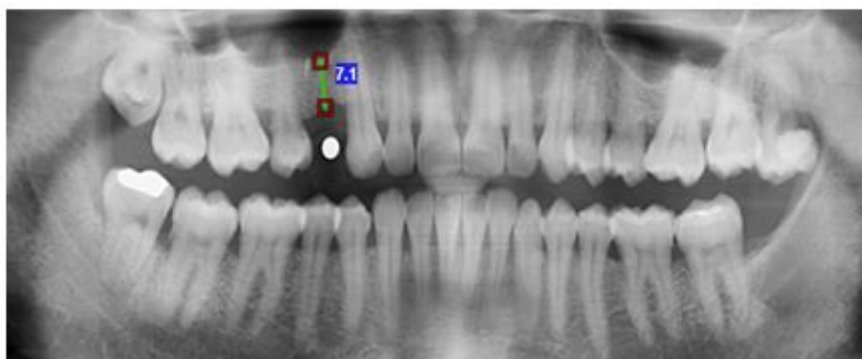


Figure 6: Magnification error from OPG was calculated and eliminated with the use of ball bearings of known diameter

DISCUSSION

Pearson’s correlation showed highly correlating measurements of 0.90 between OPG and CBCT. This indicates that the reliability of using OPG to determining the alveolar bone height is comparable to that of the “gold standard”.

Every OPG machine is known to have its respective distortion causing magnification of images compared to CBCT. This distortion varies from one site to another. To overcome this limitation, ball bearings of known diameter (3mm) were placed at the sites of interest (Figure 6). The radiographic diameter of the ball bearing was compared to that of the actual diameter and the distortion value was determined, using the formula [5] below:

$$\text{Actual bone height} = \frac{\text{Actual ball bearing diameter}}{\text{Radiographic ball bearing diameter}} \times \text{Radiographic bone height}$$

This value was used to calculate the actual bone height of the corresponding site, thus significantly minimizing the distortion error.

In measuring of the bone width prior to placement of an implant, we have compared both CBCT and ridge mapping. Both of these methods would ideally reveal the sagittal morphology of the alveolar bone and an orientation ideal to place the implant selected.

Based on the results of our study, the level of correlation of Ridge mapping to CBCT was 0.5, which is inferred as a moderately correlated result. The mean difference in measurements was 1.2mm between ridge mapping and CBCT. This concluded that the ridge mapping values obtained was underestimating the gold standard values of the CBCT. There are many possibilities that could have given rise to this error.

The goal of ridge mapping is to stop the instrument penetrating the mucosa at its first contact with the underlying bone. However, this exact point is difficult to determine as visualization is hindered by the overlying mucosa. Furthermore, cancellous bone is porous in nature, thus easily giving way to further penetration of the instrument. Allen F., Smith D.G. [4] along with Perez L.A. et al [6] who had all conducted a similar study also encountered this issue.

Another possibility that could have led to an underestimation of the measured bone width could be due to the presence of the mobile alveolar mucosa, which upon its reflection will result in greater errors when measuring the areas closer to the sulcus region. Similarly, Luk L. C. K. et al [7] faced this common challenge in his study.

According to Dr Cheung T.S. [8], underestimation of bone width can be caused due to the failure of complete seating of the clinical template over the edentulous area. The coronal portion of the alveolar bone is narrower than that of the apical portion. This incomplete seating resulted in coronal shifting of the location of measuring points giving an underestimated value. In contradiction to this statement, our study has not faced this situation. Accurate fabrication of the clinical templates for each individual patient on the cast would not cause a problem in seating later during the procedure. Acrylic is known to distort if not kept in moisture due to warpage, thus proper care of acrylic stents should be taken from processing up to placement in the patient's mouth to prevent this incomplete seating.

According to Perez L. A. et al [6], there was significant inter-examiner variability in their study. In our study, this common error was eliminated by training and calibration. It was calculated and determined that there was a high level of agreement between the readings obtained from the four examiners with an average R value of 0.9 for ridge mapping and 1 for OPG, which showed a strong positive correlation.

Transferring the readings obtained from the clinical procedure to the sectioned cast faced many minimal errors that were inevitable. This includes, the process of syneresis and imbibition of alginate that might have occurred during the time taken from impression making to pouring of the cast, the minor inaccuracies in sectioning of the cast and reproducing the site of mucosal penetration on the sectioned cast. The addition of all these minor errors would prove to have a summative effect on our final readings.

One of the significant findings observed from ridge mapping was the ability to visualise anatomical limitations of the underlying bone prior to implant placement. These limitations include, knife-edge ridges, concavities and bony prominences on the bone. This enables the clinician to devise a more appropriate treatment plan.

CONCLUSION

Within the limitations of the study, we have concluded that, (1) There is high correlation between the measured bone height obtained from OPG compared to that of CBCT; (2) There is moderate correlation between the measure bone width obtained from ridge mapping compared to that of CBCT; (3) There is no clinical significance in the difference of measurements obtained between OPG and ridge mapping with CBCT.

The limitations in our study for OPG include, overlapping of images in which, depending on the experience of individual clinicians, the extent of available bone height for an implant placement will be difficult

to determine due to the complex anatomical structures in the head and neck region. In the anterior region, the overlapping of the cervical vertebrae disrupts the quality of the radiograph.

The limitations in our study for ridge mapping include, determination of the facio-lingual location of mandibular canal and maxillary sinus, and the depth of buccal vestibule and floor of the mouth limit the ridge mapping procedure.

To conclude, ridge mapping along with OPG can be used for pre-implant site assessment in ideal cases where the pattern of resorption of the alveolar ridge is regular. In clinically evident ridge deformities or cases where ridge mapping is not feasible, a CBCT scan is recommended for pre-implant site assessment. Similarly, in cases where ridge irregularities are revealed through ridge mapping, CBCT scans are advocated

REFERENCES

- [1] Benson B.W, Shetty V. Dental Implants. In White S.C., Pharoah M.J., Oral Radiology: Principles and Interpretation. 6th Edition. Philadelphia,PA: Mosby Elsevier; 2009. pp. 597-10.
- [2] Kalra D., Jain G., Deoghare A., Lambade P. Journal of Indian Academy of Oral Medicine and Radiology 2010; 22(1):34-38
- [3] Chandraker N.K., Chowdary R., Verma A. Indian Journal of Dental Research 2014; 24(6):784-86
- [4] Allen F., Smith D.G. Clinical Oral Implant Research 2000;11: 34-8
- [5] Pertl L , Gashi-Cenkoglu B., Reichmann J., Jakse N., Pertl C. European Journal of Oral Implantology 2013; 6(1):73-80
- [6] Perez L.A., Brooks S.L., Wang H.L., Eber R.M. Oral Surgery Oral Medicine Oral Pathology Oral Radiology Endodontics 2005; 99:748-54
- [7] Luk L.C.K., Pow E.H.N., Li T.K.L., Chow T.W. International Journal of Oral Maxillofacial Implants 2011; 26:70-4
- [8] Cheung T.S. 2002, Comparison of Spiral Tomography (scanora) with Ridge Mapping and Plainfilm Radiography for Dental Implant Planning in Partially Dentate Jaws. Ph. D thesis, University of Hong Kong. Available from HKU Scholars. [September 2012]