

Research Journal of Pharmaceutical, Biological and Chemical Sciences

An Interesting Case Of Absent Pulmonary Artery!.

Pradeep Kumar Reddy K^{1*}, M Sudhakar Rao², Raja RajanM², Ashwal Aj², Padma Kumar R²,
and Goutham Reddy Katukuri¹.

¹Department of General Medicine, KMC Manipal, Manipal University, Manipal, Karnataka, India.

²Department of Cardiology, KMC Manipal, Manipal University, Manipal, Karnataka, India.

ABSTRACT

Combination of pulmonary hypoplasia and pulmonary artery agenesis is one of the rarest respiratory diseases. This case is about a 3 year old asymptomatic female child presented with congenital scoliosis, on further investigation she was found to have left pulmonary hypoplasia with left pulmonary artery agenesis. Though the patient may be asymptomatic for the age and findings might be incidental, our case report signifies the importance that when a patient presents with chest wall deformities it is worth to investigate further to rule out the other associated congenital anomalies as happened in our case.

Keywords: congenital scoliosis, pulmonary hypoplasia, pulmonary artery agenesis, asymptomatic

**Corresponding author*

INTRODUCTION

Congenital Pulmonary agenesis means complete absence of lung tissue and pulmonary hypoplasia which means a piece of lung tissue is present with blood supply either from pulmonary artery or bronchial vasculature or from systemic circulation. Although these conditions are rarely presented, they may be associated with other anomalies like pulmonary artery agenesis which is due to malformation of 6th aortic arch of same side during embryogenesis [12, 13]. It can be asymptomatic and an incidental finding or it can present with recurrent respiratory tract infections. CT pulmonary angiography can identify this condition and based on this investigation it is classified into complete pulmonary agenesis or pulmonary hypoplasia which is supplied by ipsilateral pulmonary artery or by systemic circulation.

Case

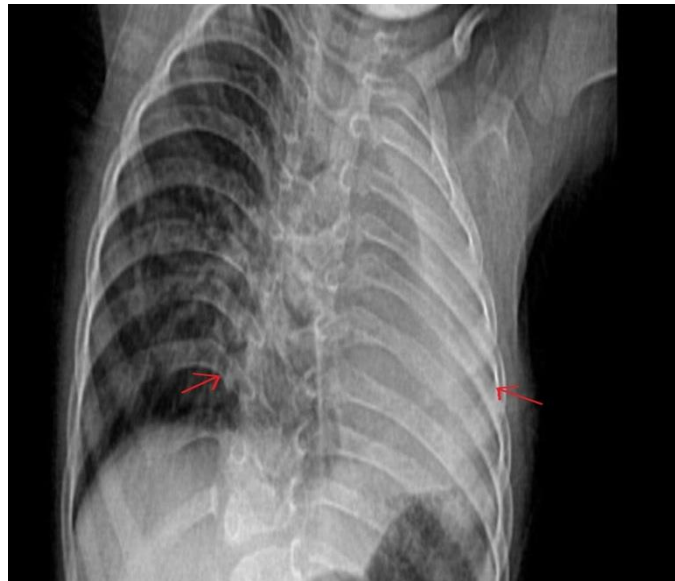


Figure 1: Chest X-ray PA view showing left hemithorax white-out, with scoliosis showing convexity towards right and hyperinflation of the contralateral lung

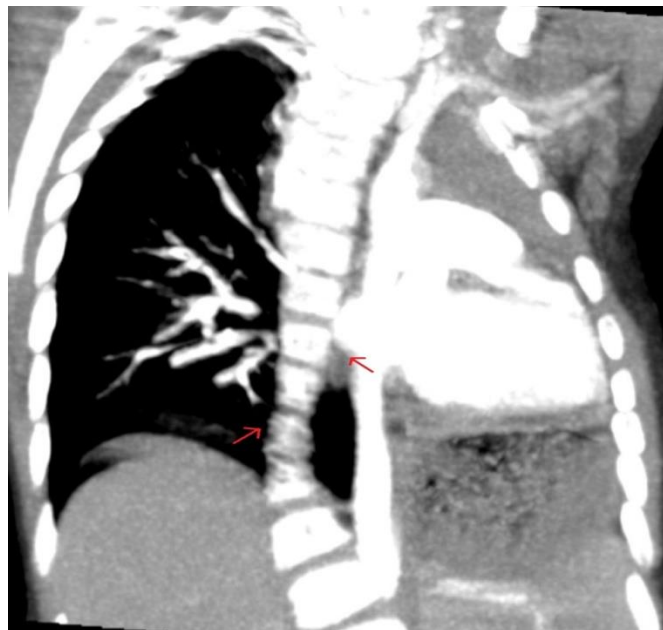

Figure 2

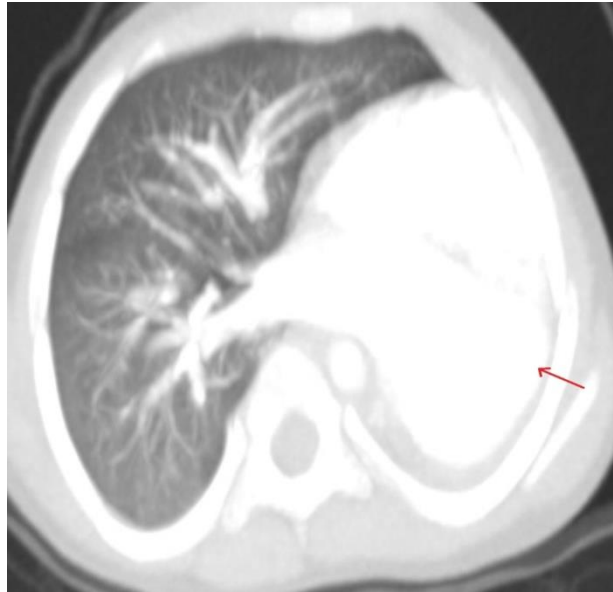


Figure 3

Figure 2 &3 : computed tomography scan coronal view and axial view showing absence of lung parenchyma on left side with gross mediastinal shift, rudimentary left main bronchus and absent left main pulmonary artery along with scoliosis of thoracic vertebra to right side

A 2yr 11month old female child was admitted in our hospital for congenital scoliosis. There was no history of respiratory illness. She was delivered by lower segment caesarean section at 8 months of gestational age in view of pregnancy induced hypertension. Birth weight was 1.3kgs and she cried immediately after birth. Developmental history was normal with no complications postnatally. She was promptly immunized. Examination findings were suggestive of scoliosis with right hemithorax measuring 24 cm and left hemithorax measuring 21 cm with decreased to absent breath sounds on left side. Incidentally on chest radiograph opacification of left hemithorax was observed [fig 1]. In view of scoliosis child was sent for cardiac evaluation to rule out any congenital anomalies. Two dimensional echocardiogram showed Hypoplastic pulmonary artery. Suprasternal view showed dilated bridging vein suggestive of anomalous draining left pulmonary vein. To confirm the diagnosis CT angiogram was done which showed absence of lung parenchyma on left side with gross mediastinal shift, rudimentary left main bronchus and absent left main pulmonary artery along with scoliosis of thoracic vertebra to right side [fig 2 & fig 3].

DISCUSSION

At 5th week of intrauterine life, bronchial buds are formed and by the end of 6th month all the 17 segments of lung are formed [1] whereas complete development of bronchial tree occurs in initial postnatal life. Pulmonary hypoplasia is of varying degrees [2,3]. According to Boyden [4], developmental disorders of lung can be either of the below:

- Agenesis- complete absence of lung tissue
- Aplasia- No lung tissue but rudimentary bronchioles are present
- Hypoplasia- All lung tissues exist but they are underdeveloped
- Based on angiographic data, clinical classification is as below:
- Complete absence of lung parenchyma and ipsilateral pulmonary artery
- Hypoplastic lung tissue with ipsilateral pulmonary artery supply to it
- Hypoplastic lung tissue with systemic circulation to it

In view of above classifications, this patient is categorized under group B boyden classification and group C clinical classification.

Etiologically pulmonary hypoplasia can be primary (Idiopathic) or secondary. Chest wall deformities, cystic adenomatoid malformations, diaphragmatic hernia limits the development of lung leading to secondary

pulmonary hypoplasia[5,6]. It can be unilateral or bilateral where bilateral pulmonary hypoplasia is rarely seen and it is commonly associated with thoracic dystrophies which have bad prognosis unlike in unilateral pulmonary hypoplasia where contralateral lung is enlarged which may limit the symptomatology.

Severity of the disease depends upon the degree of hypoplasia. In some patients APGAR score at birth may be less and they may require mechanical ventilation too but few children may have good APGAR score at birth and this finding may be an incidental one, as seen in this 2yr 11month old female patient. Anyways recurrent respiratory infections are not uncommon in these patients.

Chest X-ray is the first tool in diagnosis of pulmonary artery agenesis with lung hypoplasia. Incases of Hypoplastichemi thorax with ipsilateral diminished pulmonary artery vasculature, pulmonary artery agenesis is to be suspected [7]. CT angiography is normally sufficient for diagnosis. It can also detect cardiovascular malformations and it is the diagnostic tool in this case. To see the exact perfusion of lung by pulmonary artery before surgery, scintigraphy is done [8,9]. Perfusion scintigraphy and ventilation-perfusion studies can be done in pulmonary agenesis to see if ventilation is normal or diminished [9-11]

Symptomatic treatment may be advised initially. If symptoms are recurring, surgery is treatment of choice. Pneumonectomy or lobectomy can be done if hypoplastic lung is supplied by systemic circulation. If it is supplied by ipsilateral pulmonary artery then surgery is contraindicated.

CONCLUSION

Being an incidental finding, pulmonary hypoplasia with pulmonary artery agenesis may be considered a rare condition according to literature. But it should be a differential diagnosis in case of shortness of breath or recurrent respiratory tract infections in a patient who have other congenital anomalies like thoracic dystrophies, renal anomaly, cardiac anomaly along with prenatal history of pregnancy induced hypertension, prolonged rupture of membranes or polyhydramnios.

REFERENCES

- [1] TW Sadler. Respiratory system. In: Sadler TW, editor. , eds. Langman's medical embryology. 8th edn MD: Lippincott Williams & Wilkins, 2009:275–84
- [2] Deniz Ö, Tozkoparan E, Çiftçi F, et al. Sol pulmoneraplazi (agenezi) (olgusunumu). Gülhane Tip Dergisi 2004;46:56–8
- [3] Roque AS, Burton EM, Boedy RF, et al. South Med J 1997;90:335–7
- [4] Boyden EA. Am J Surg 1955;89:79–89
- [5] Gülen F, Kar S, Midyat L, et al. Open J Pediatr 2011;1:75–8
- [6] Porter H. Arch Dis Child Fetal Neonatal Ed 1999;81:81F–3F.
- [7] Mardini MK, Nyhan WL. Chest 1985; 87: 522-27.
- [8] Rupperecht E, Wunderlich P, Dietzsch HJ, Hennig K, Platzbecker H, Berger G, Leupold W, Wunsche W. Z Erkr Atmungsorgane 1977;147:57–72.
- [9] Galuska L, Marton H. Orv Hetil 1996;137:411–414.
- [10] Krall WR, Ploy-Song-Sang Y. South Med J 1980;73:233–236
- [11] Wu MT, Pan HB, Chiang AA, Hsu HK, Chang HC, Peng NJ, Lai PH, Liang HL, Yang CF. Am J Roentgenol 2002;178:667–672.
- [12] Pool PE, Vogel JH, Blount SG Jr. Am J Cardiol 1962;10:706–732.
- [13] Toews WH, Pappas G. Chest 1983;84:497–499.