

Research Journal of Pharmaceutical, Biological and Chemical Sciences

Histopathological and ameliorative effect Of "*Raphanus Sativus*" extract against Copper Sulphate toxicity in "*Ctenopharyngodonidella*" Fish.

Celine Hilda Mary S^{1,2*}, Leema Rose Mary¹, Anitha R¹, and Anandan R³.

¹PG and Research Department of Biochemistry, St. Joseph's college of Arts & Science, Cuddalore, Tamilnadu- 607 001, India.

² Research and development centre, Bharathiar University, Coimbatore, Tamilnadu- 641046, India.

³Biochemistry and Nutrition Division, ICAR-Central Institute of Fisheries Technology, Cochin-682029, India.

ABSTRACT

Nowadays the consumption of fish by the humans has been increased due to their low cholesterol and high protein content. The marine ecosystem has been contaminated by the heavy metals.^[1] In the present study the acute toxicity of copper sulphate was analyzed by the exposure of the copper sulphate to the fresh water fish *Grass carp (ctenopharyngodonidella)* in the concentration of (3ppm/l for 15 days). The vital organs like Gill, Liver, and muscle tissues showed pronounced effect on the activity of biochemical parameters. Copper sulphate administration increases the concentration of urea, cholesterol, GOT (Glutamate oxaloacetate transaminase), GPT (Glutamate pyruvate transaminase) and ALP (Alkaline phosphatase) level. The concentration of protein was decreased significantly in all the tissues. All the biochemical parameters were reversed nearly to the normal levels significantly after the treatment with *Raphanus Sativus* leaves extract with the concentration of 250mg/l for 15 days.

Keywords: copper sulphate, biochemical parameters, toxicity, Grass carp, Raphanus Sativus.

*Corresponding author

INTRODUCTION

Fish is one of the most sensitive indicators of trace metal pollution and are often at the top of aquatic food chain and may consume large amount of metals from the water.[2] and they reflect the biological effects of environmental pollution. In natural life, some trace metals are essential at low level but toxic at higher concentrations. Aquatic eco-systems usually reflect all the input generated by a variety of activities taking place in hydrographic basin they are inserted.[3] The researchers were attracted by the pollutants of the aquatic system all over the world . [4]

The toxicity of environmental system was interpreted by determining the biomarker (biochemical, physiological, & histological markers). Histopathological analyses of different organs may indicate the biological response to an unfavorable situation, because often the prolonged exposure of the organisms to toxic agents affects the structure and the function of vital organs jeopardizing the individual, pollution and sometimes the species. Copper sulphate is an essential metal for all organisms including fish, and has an important role in metabolism. However, the accumulation of copper affect various blood parameters, growth, behavior, enzyme activity and reproduction of fish.[5] Fishes are very good biosensors of aquatic contaminants and as bio-indicator species responds with great sensitivity to changes in the aquatic environment. The radish leaves are used to improve the oxygen supply within the blood, which helps to remove the yellow hue from the skin.[6] The objective of the study was to assess the copper sulphate induced toxicity and the protective effect of *Raphanus Sativus* in the fish *Ctenopharyngodon idella* and to describe the histopathological alterations in the gills, liver and muscles of the specimens.

MATERIALS AND METHODS

Sample Collection

The live specimens of adult fresh water fish *Ctenopharyngodon idella* (Grass carp), both sexes, body weight 15-50g were collected from the pond water located at the Karayamputhoor area in Cuddalore district and used as the test animals. They were acclimatized to the laboratory condition for few days in plastic fish tanks. (15-25cm in length,15-50g of body weight). Physiochemical characteristics of the tap water used in this experiment were temperature at 26°C and pH-7. The toxicant was dissolved in distilled water and mixed well in the fish tank. The tanks were provided with continuous aeration and were maintained under light-dark (12:12 hrs) cycle. During acclimatization, the fishes were fed with commercial pelleted food for 2-8 times per day. The water concentration of the toxic substance was renewed after 15 day

Preparation of Plant Extract

Fresh radish leaves were collected, sun -dried & grounded to fine powder, using the coffee mill attachment of a moulinex domestic food blender. The powder was kept in a desiccators for later use.

The aqueous extract of radish leaves powder was prepared by dissolving 250mg/l of distilled water and then introduced directly in to the tanks in a single dose.

Experimental Design:

Toxicity Study:

Group 1 : control (in saline)

Group 2 : 3ppm/l Copper Sulphate (15 days)

Group 3 : 250mg/l (*Raphanus Sativus* leaves extract) (15 days)

Biochemical Analysis

Six fishes from each group were sacrificed at the end of 15 days. The vital organs like Gill, Liver, and muscle of the fish were taken for the determination of the biochemical parameters, activity of the enzymes and antioxidants. The estimation of protein was done by Lowry's method.[7] The estimation of urea was done by DAM method.[8] The amount of cholesterol was estimated by Zak's method.[9] The activity of glutamate

oxaloacetate transaminase (GOT) was determined by Reitman's and Frankal method (Reitman's and Frankal, 1957).[10] The glutamate pyruvate transaminase (GPT) activity was determined by Reitman's and Frankal method (Reitman S and Frankal S, 1957).[11] The ALP activity was determined by King and Armstrong method (King EJ and Armstrong AR, 1934) (EC 3. 1. 3. 1). [12]

RESULTS

The results of various parameters investigated in the present study have been presented in Fig.1 to Fig.6. As it is evident from the figures, copper sulphate administration increases the concentration of **urea**, **cholesterol**, and decreases the level of **protein**. The activity of the enzymes like **GPT**, **GOT** & **ALP** levels were increased. The levels were reversed nearly to the normal levels significantly after the treatment with radish leaves extract.

Figure 1: Changes in the concentration of biochemical parameter protein.

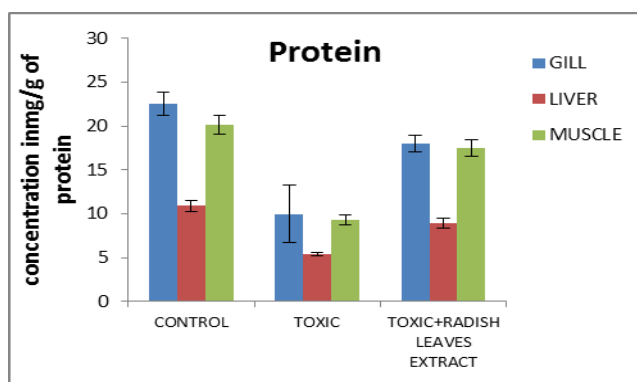


Figure 2: Changes in the concentration of the biochemical parameter Urea

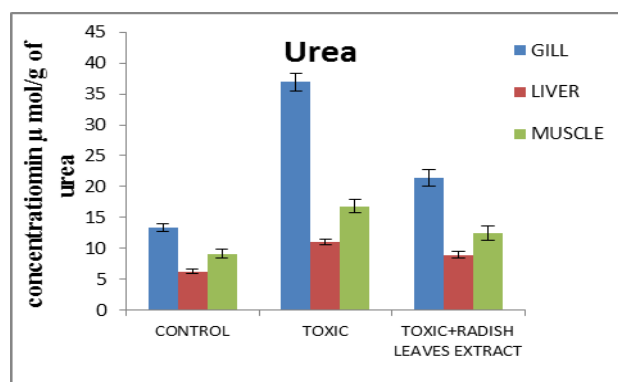


Figure 3: Changes in the concentration the biochemical parameter Cholesterol.

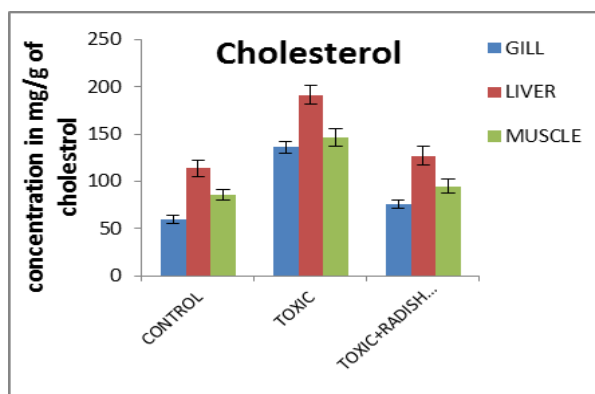


Figure 4: Changes in the activity of the enzyme GOT

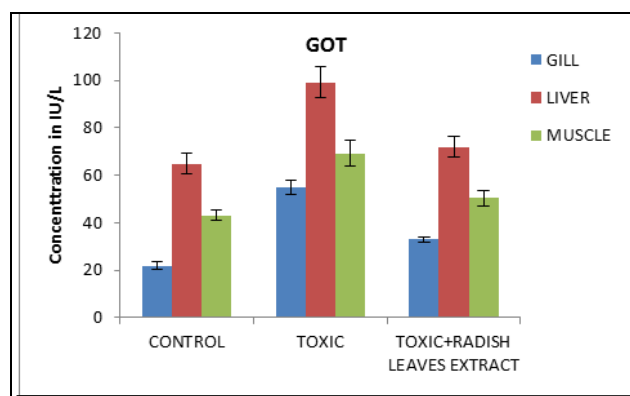


Figure 5: Changes in the activity of the enzyme GPT

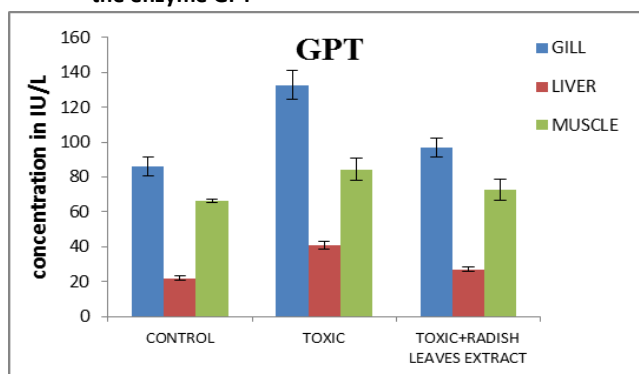
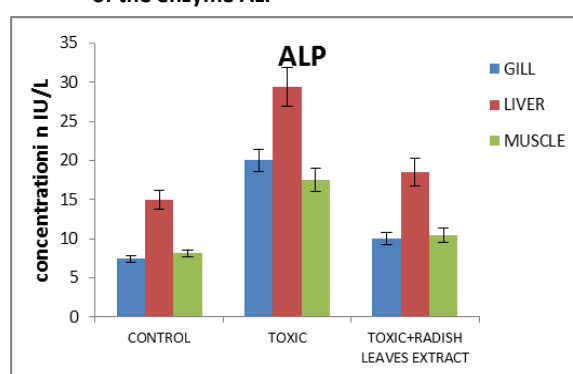


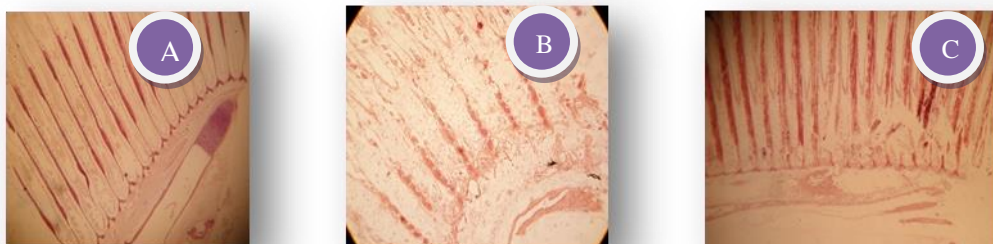
Figure 6: Changes in the activity of the enzyme ALP



HISTOPATHOLOGICAL RESULTS

Histopathological studies of Gill, muscle, and liver of fishes in Copper sulphate intoxication are shown in the Fig.5 to Fig 7. In Gill the secondary lamellae are intact and the hypertrophy is seen. In toxic fish after the exposure of copper sulphate the fragmentation of primary lamellae and the erosion in secondary lamellae are seen. In muscle mild intramuscular edema was observed. In toxic fish the elongation and separation of muscle fiber was observed and the fibers are seem to be less compact after the exposure of copper sulphate on fish. In liver the normal liver architecture were changed after the exposure of copper sulphate. It shows complete disintegration. Marked necrosis with hyper vacuolization is observed.

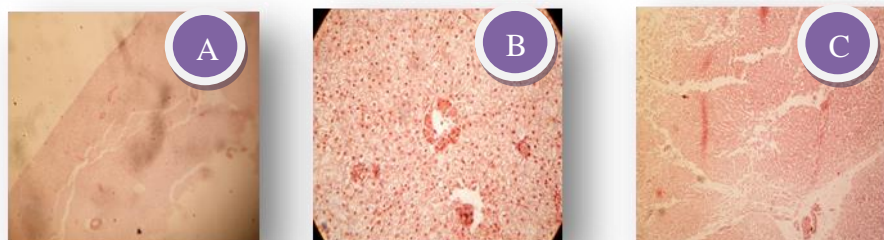GILL



a) NORMAL GILL b) TOXIC GILL c) TREATED GILL

Figure 5: Normal aspects of gill with filament and Mild hypertrophy are seen. Secondary lamellae are intact (a); Fragmentation of primary lamellae and erosion of secondary lamellae was observed. Complete disintegration of primary epithelial cells was seen. Epithelial lifting, hyperplasia of epithelial cells and lamellar fusion (b); Appearance of primary lamellae and erosion of secondary lamellae was observed. Regeneration of epithelial cells, filtration of erythrocytes in venous and hypoplasia of epithelial cells were observed (c).

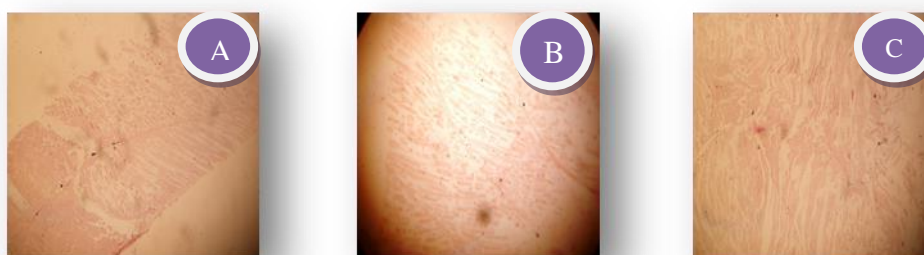
LIVER



a) NORMAL LIVER b) TOXIC LIVER c) TREATED LIVER

Figure 6: Normal liver architecture observed (a); Complete disintegration of endothelial lining cells of hepatocytes around the central vein is observed. Marked with hyper vacuolization is observed (b); Mild appearance of endothelial lining cells of hepatocytes around the central vein is seen. Decreased level of necrosis with hypo vacuolization is observed(c).

MUSCLE



a) NORMAL MUSCLE b) TOXIC MUSCLE c) TREATED MUSCLE

Figure 7: Normal aspects of muscle with intact muscle fibers and Mild intramuscular edema were observed with shortening of muscle fibers (a); Thickening, elongation and separation of muscle fibers were observed with intramuscular edema. Fibers seem to be less compact (b); Smoothing and appearance of muscle fibers were observed. Fibers seem to be more compact (c).

DISCUSSION

In our study it has been observed that the level of protein was decreased in most of the tissues, may be due to the metabolic utilization of ketoacids to gluconeogenesis pathway for the synthesis of glucose, or for the maintenance of osmotic and ionic regulation. It could also be due to the production of heat shock proteins or destructive free radicals or could be a part of heavy metal induced apoptosis. [13]

The decrease in protein content may be due to reduced protein synthesis and increased proteolysis. The same effect was observed in *Cyprinus carpio* and found that the total protein content of the brain, liver and muscle were declined. [14]

In the present study total protein content was decreased in all the tissues and it may be due to the breakdown of proteins in the fabrication of some amount of energy for organism. The degree of increase in free amino acids is resulted by the decreased protein level. Protease activity is increased in all the tissues due to inactivation of oxidative enzymes, reduction in energy production and acceleration of proteolysis. The values were significantly increased to the normal level after the treatment with radish leaves extract.

The increased level of urea may be due to the breakdown of protein to amino acids. The amino acids were catabolised by the deamination and transamination process. Increased level of urea might be due to the activation of urea cycle for the detoxification of ammonia. Effect of copper sulphate progressively increases the level of ammonia, indicated by its accumulation in tissues. The main basic mechanism of detoxification of ammonia is its conversion to urea, and the arginase activity serves as an index of the increased level of urea and elevates the osmo-concentration of body fluids and facilitates the fish to tolerate the toxicity.[15] The values were significantly decreased to the normal level after the treatment with radish leaves extract.

The level of cholesterol was increased in the present result may be due to the increased synthesis of cholesterol by diverting glucose towards lipid metabolism.[16] Significant increase in total cholesterol in both the test samples reflects the presence of a marked hypercholesterolemia. Increased level of hepatic lipids in the samples signals the presence of hyperlipemia. [17] The values were significantly decreased to the normal level after the treatment with radish leaves extract.

The activity of GOT, GPT was increased in liver followed by muscle and gill, may indicate disturbance in the cell organelles. Such damage to cell organelles has been reported in various studies. Liver is the metabolic centre for detoxification of chemicals and further changes in the activities of Glutamate-Oxaloacetate Transaminase (GOT) and Glutamate-Pyruvate Transaminase (GPT) confirms the liver damage. [18] It has been reported that the level of GPT increased in toxic hepatitis and viral hepatitis. The increased

activity of GOT and GPT in the experimental fishes may be due to the toxicities, which suggests enhanced protein catabolism and probable hepatocellular damage in the organism. [19]

The phosphatase (ALP) is an important biomarkers because they are involved in adaptive cellular response to the potential cytotoxicity and genotoxicity pollution. It is a microsomal enzyme involved in membrane transport of metabolites across membrane. [20] Results of the present study show that the toxicity of copper sulphate increases the activity of the ALP in the liver followed by the gill and muscle. The elevated level may as a result of liver damage or arrested bone growth. [21] This may be due to the strategic roles of this organ in the managements of toxicant and their metabolic waste. [22] An increased synthesis and reduced biliarsy excretion of ALP and the cholestatic disorders are usually associated with the increased level of ALP.[23]

SUMMARY AND CONCLUSION

The present study revealed that the copper sulphate intoxication makes alteration in the level of urea, cholesterol, protein and the activity of GOT, GPT & ALP. The Increase values of these parameters indicate hepatocellular destruction and establish the hepatic cell breakage from their normal configurations. So, we may conclude that the toxicological effect of copper sulphate alters morphological and physiological functions in hepatic tissues of *Ctenopharyngodonidella* by modulating the enzymological and biochemical changes. While, these changes can be ameliorated by radish leaves extract because of its antioxidant properties as it is a vitamin C rich vegetable.

REFERENCES

- [1] Mirnov. In the first American-Soviet Symposium on the biological effect of pollution on marine organism (EPA). 1978 ; 600/9-78-007.
- [2] Mansour SA. and Sidky MM. Ecotoxicological Studies, Heavy Metals Contaminating Water And Fish From Fayoum Governorate , Egypt. 2002.
- [3] Tundisi, J., Mastummura –Tundisi, T. And Rocha,O. Therorical Basis For Reservoir Management. In: Tundisi, J, G. And Straskraba, M. Theoretical Reservir Ecology And Its Application. Sao Carlos, Sp. (1999); 52 ap .: il.pp.505-528.
- [4] Dutta HM, Dalal R. International Journal of Environmental Research 2008; 2:215-224.
- [5] Oruc, H. H. Cengiz, M. Beskaya, A. J. Vet. Diagn. Invest. 2009; 21: (4), 540-543.09
- [6] "Radish nutrition facts". Retrieved 2014; 10-02.
- [7] Lowry, O.H., M.J. Rosenbrough, A.L. Farr and R.J. Randall. J. Biol. Chem 1951; 193: 265-275.
- [8] Wearne, J.T.,J.Clin.path.1958; 11:367.
- [9] Zlatkis A, Zak B, Boyle GJ. J Clin Med 1953; 41: 486-92.
- [10] Reitman S. Frankel S. Am J clin Pathol. 1957; 28:56-63.
- [11] Reitman S. Frankel S. Am J clin Pathol.1957; 28: 56-63.
- [12] King E. J Clin Path. 1954; 7: 132.
- [13] Schmidt Nielson B. Osmoregulation: Effect of Salinity and Heavy Metal. Fed. Proc. 1975; 33: 2137-2146.
- [14] Joseph. Proc. Nat. Conc. Env. Impact on Biosystem (1987); 263-267.
- [15] Schoffeniels E and Gilles R Nitrogenous constituents and nitrogen metabolism in arthropods in: Chemical Zoology (eds.) M. Florkin and B. T. Scheer, Academic press, London, New York,1970; pp.218-219.
- [16] Rana, S. V. Kumar, A. Ind. Health. 1980; 18: (1), 9-17.
- [17] Gill, T.S., Pande, J. And Tewari, H.M. Ecotoxicol. Environ. Saf. 1991; 21: 80-91.
- [18] Asztalos, B. And Hemesok, J.Comparative Biochemistry and Physiology (1985); 82:PP. 217-219.
- [19] Praful, Gpdkar, B. And Darshan, Godkar. P.Text Book of Medical Laboratory Technology, Bhalani Publishing House, Mumbai,India. 2003.
- [20] Ayalogu O.E., Igboh N.M.. And Dede E.B. J.Appl.Sc.Envir.Mgmt 2001; 5 :(1) 97-100.
- [21] Sastry, K.V., Siddique, A.A And Samuel, M Acta.Hydrorbiol. 1988; 16 :(6) 625-631.
- [22] Leohner T.W., Reash R.J. And Williams M. Tissue Biochemistry Evaluation. Rcotoxicol. Envir. Saf. 2001 ; 50: 217-224.
- [23] Ali M, Parvez S, Pandey S, Atif F, Kaur M, Et Al. Environ Int . (2004); 30: 933-938.