

# Research Journal of Pharmaceutical, Biological and Chemical Sciences

## Cefoperzone - Sulbactam Induced Hypoprothrombinemia.

Vijay Jaimni<sup>1</sup>, Neha Agarwal<sup>1</sup>, Sudhakar Rao M<sup>2\*</sup>, and Sudha Vidyasagar<sup>2</sup>.

<sup>1</sup>Department of Medicine, KMC Manipal, Manipal University, Manipal, Karnataka, India.

<sup>2</sup>Department of Cardiology, KMC Manipal, Manipal University, Manipal, Karnataka, India.

### ABSTRACT

An elderly man who presented to the hospital with UTI and renal failure was given cefoperazone-sulbactam, subsequently developed hematemesis and hematuria. Cefoperazone, a parenteral third generation cephalosporin is effective against many Gram positive and Gram negative organisms. Cefoperazone, similar to other cephalosporins such as cefamandole, contains the methylthiotetrazole (NMTT) side chain, which can cause hypoprothrombinaemia and consequently bleeding manifestations. This type of coagulation disorder usually responds to Vitamin K administration.

**Keywords:** Cefoperazone- sulbactam, Hypoprothrombinaemia, Coagulation disorder, Vitamin K, N-methyl- thio-tetrazole (NMTT) side chain

*\*Corresponding author*

## INTRODUCTION

Cefoperazone, a third generation cephalosporin acts by inhibiting biosynthesis of cell wall mucopeptide. Sulbactam acts a beta-lactamase inhibitor, thus restoring cefoperazone activity against beta-lactamase producing strains. Cefoperazone, similar to other cephalosporins that contain the methyltetrazole side chain, can cause hypoprothrombinaemia and thus bleeding [1]. Use of cefoperazone therefore, warrants caution especially in individuals with vitamin K deficiency [2].

Here we report a rare side-effect encountered in a 77 year old male.

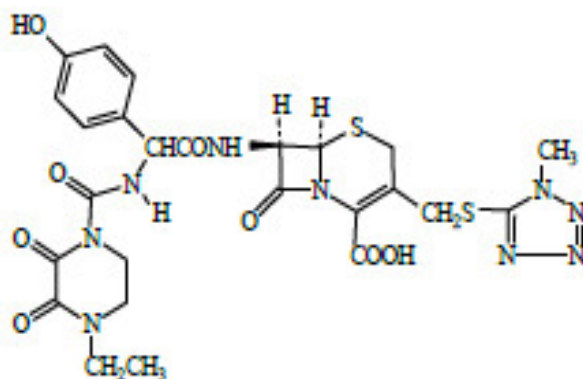


Fig 1. Structure of cefoperazone

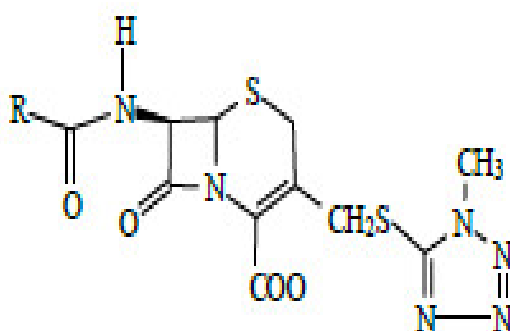


Fig 2. Structure of NMTT ring

## CASE REPORT

A 77 year old male, known to be diabetic and hypertensive; came to the hospital with complaints of decreased urine output, fever and burning micturition. General physical examination revealed pallor, and systemic examination demonstrated suprapubic tenderness. Hemogram showed leukocytosis, urine microscopy was positive for pus cells, and renal parameters revealed raised serum creatinine. Ultrasound abdomen revealed a shrunken right kidney with grade III renal parenchymal changes.

In view of urinary tract infection (UTI) cefoperazone- sulbactam was started empirically, prior to which blood and urine cultures were sent. Although both urine and blood cultures were reported to be sterile, treatment was continued; as patient was improving clinically. On day 7 of antibiotics, patient developed hematuria, and the subsequent day, he developed hematemesis. Coagulation studies revealed prolonged prothrombin time and high INR values (refer table 1). All other causes of elevated PT/INR were ruled out including liver dysfunction. Cefoperazone-sulbactam was discontinued, and 4 units of fresh frozen plasma were transfused, along with 3 doses of vitamin K in view of persistent bleeding. On subsequent days, there was no hematemesis, hematuria decreased, and PT/INR normalized (refer table 1).

**Table 1. Lab parameters during hospitalisation**

| Parameters             | At admission | Day 7/8 | Day 9 | Day 11 |
|------------------------|--------------|---------|-------|--------|
| PT(secs)               |              | 54.2    | 48.3  | 16.7   |
| INR                    |              | 4.36    | 3.79  | 1.06   |
| APTT (secs)            |              | 48.8    | 40    | 32     |
| Hb (gm/dl)             | 10.0         | 8.6     | 8.2   | 7.1    |
| TLC (cells/cu.mm)      | 12700        | 10000   |       |        |
| T. Bil (mg/dl)         | 0.4          | 0.3     |       |        |
| AST (IU/l)             | 7            | 11      |       |        |
| ALT (IU/l)             | 5            | 6       |       |        |
| Creatinine (mg/dl)     | 6.2          | 4.9     | 5.2   | 5.7    |
| Urine WBCs (cells/hpf) | 30-35        | 4-5     |       |        |

PT- prothrombin time, APTT- activated partial thromboplastin time, Hb- hemoglobin, TLC- total leukocyte counts, T.bil- total bilirubin, AST- aspartate aminotransferase, ALT- Alanine transaminase, WBC- white blood cells, hpf-high power field.

### DISCUSSION

Cefoperazone, a third-generation cephalosporin, contains the N-methyl- thio-tetrazole (NMTT) side chain. Administration of NMTT-containing cephalosporins (i.e. cefoperazone, cefamandole) can cause alterations in the hepatic glutathione redox state, resulting in a dose-related increase in oxidised glutathione, which is responsible for the inhibition of microsomal reduction of vitamin K epoxide [3]. This causes decreased levels of vitamin K dependent coagulation factors in blood, thereby causing deranged coagulation profile and in-turn bleeding manifestations.

This patient was started on empiric antibiotics; cefoperazone-sulbactam, in order to treat his urinary tract infection. The patient improved clinically, however he developed hematuria, followed by hematemesis, after 7 days of antibiotic therapy. A decrease in total leukocyte count and normal liver function tests effectively ruled out sepsis and hepatic dysfunction as causes for the deranged coagulation profile. Hypoprothrombemia was suggested as a cause, as it is a rare, but documented side effect of cefoperazone-sulbactam.

The derangement of coagulation parameters caused by cefoperazone-sulbactam responds to Vitamin K administration, according to Wong RS et al. Hence, the antibiotic was withdrawn, and the patient was administered 4 units of FFP and 3 doses of Vitamin K. This ensued in clinical improvement as well as normalization of the coagulation profile.

In addition, Chung AH et al postulated that incidence of bleeding manifestations increases in patients with deranged renal function [4]. Cefoperazone is partially excreted by the kidneys, and thus the dose has to be adjusted in patients with renal failure to prevent drug toxicity. In the above case, the patient suffered from chronic kidney disease stage 4 (GFR estimated= 9.38 ml/min/1.73m<sup>2</sup> MDRD). However, since the reaction appears to be idiosyncratic, adjusting the dose according to renal function did not prevent the patient from developing bleeding manifestations.

In conclusion, while administering cefoperazone and other molecularly similar cephalosporins, the rare side effect of a deranged coagulation profile must be kept in mind. A little extra caution is warranted in patients with renal dysfunction. Further studies are required on this topic



**REFERENCES**

- [1] Ozen IO, Moralioglu S, Karabulut R, Bagbanci B, Turkyilmaz Z, Demirogullari B, Sonmez K, Basaklar AC, Kale N. Acta Chir Belg 2008;108(6):777-8.
- [2] Wong RS, Cheng G, Chan NP, Wong WS, NG MH. Am J Hematol 2006;81(1):76.
- [3] Alagozlu H, Cindoruk M, Unal S. Clin Drug Investig 2006;26(8):481-4.
- [4] Chung AH, Watson K. Am J Health Syst Pharm 2008;65:823–826.