

# Research Journal of Pharmaceutical, Biological and Chemical Sciences

## Andrological, Oxidative Stress And Pathological Effects Of Encapsulated Peppermint Oil With Gum Arabic, Part I.

<sup>1</sup>\*Aly H M, <sup>2</sup>Amal E Abd El- Kader, <sup>3</sup>Amal M Abo El-Maaty, and <sup>4</sup>Hafiza A Sharaf.

<sup>1</sup>Department of Cell Biology, National Research Center, Egypt.

<sup>2</sup>Department of Chemical Engineering and Pilot Plant Laboratory, National Research Center, Egypt.

<sup>3</sup>Department of animal Reproduction and AI, Veterinary Division, National Research Center, Egypt.

<sup>4</sup>Pathology Department, Medical researches Division, National Research Center, Egypt.

### ABSTRACT

To study if encapsulated peppermint oil has any protective effects on some blood serum antioxidants, testosterone and tissue pathology, 30 male Swiss albino mice were divided into five equal groups. Group1 received no treatment and served as control , group 2 treated with carbon tetrachloride (CCl<sub>4</sub>) as a toxic sub-lethal drug, group 2 treated with encapsulated peppermint oil, group 4 treated with gum Arabic the matrix carrier used for peppermint encapsulation and group 5 treated with both carbon tetra chloride and encapsulated peppermint oil. Blood samples and tissues were collected after scarifying animals. Sera were collected and underwent testosterone, glutathione reduced (GSH) and Malondialehyde (MDA) analysis. Results revealed that encapsulated peppermint oil alone has no androgenic effect but when CCl<sub>4</sub> used either alone or with encapsulated peppermint oil, it significantly increased testosterone. Gum Arabic and encapsulated peppermint oil increased significantly GSH and MDA indicating oxidative stress which also confirmed in pathological sections of liver of mice treated with encapsulated peppermint oil but when encapsulated peppermint oil administered with CCl<sub>4</sub> it decreased its toxic effects and decreased the oxidative stress too. It could be concluded that encapsulated peppermint oil has protective properties and nearly adverse the toxic effects of CCl<sub>4</sub>.

**Keywords:** peppermint oil, encapsulation, gum Arabic, antioxidants, mice

*\*Corresponding author*

## INTRODUCTION

Encapsulation is a process where a continuous thin coating is formed around solid particles, liquid droplets, or even gas cells that are fully contained within the capsule wall [1]. Encapsulating any substance may have a potential application in different types of food or pharmaceutical products where maximum protection or slow release is required [2]. Flavors, acids, alkalis, buffers, lipids, enzymes, microorganisms, artificial sweeteners, vitamins, minerals, preservatives, antioxidants, cross-linking agents, leavening agents, colorants, and nutrients, all became more benefit when undergo encapsulation [3]. The advantage of encapsulation is to change the physical state from liquid to solid [4]. Encapsulation protects oil ingredients against auto-oxidation and off oxidation and off-flavor. As well as, microencapsulation can protect fatty acids from light and heat damage, and suppress or retard their oxidation [5, 6].

*Mentha piperita* (Linn;peppermint) is a perennial, glabrous and strongly scented medicinal herb belonging to the Labiatae family (Lamiaceae) which has been shown to possess antioxidant, antimicrobial, antifungal, anti-carcinogenic and antiallergic activities [7,8]. The essential oil of mint may be exploited as a natural source of bioactive phytopchemicals bearing antimicrobial and antioxidant potentials [9]. *Mentha Piperita* [Peppermint] oil is composed primarily of menthol and menthone. Other possible constituents include pulegone, menthofuran, and limone. Peppermint oil also contains various minerals, vitamin A, vitamin C, and fatty acids [10] Peppermint oil as a herbal medicine have been used for many conditions, including loss of appetite, common cold, bronchitis, sinusitis, fever, nausea, vomiting and indigestion [11]. Arabic gum (*Acacia gum*) is a water soluble polysaccharide of complex calcium, magnesium and potassium salts, could be obtained by collecting *Acacia Senegal* tree exudates [12], and was used for encapsulating some vegetable oils [13], primaquine [14], and ampicillin [15].

Carbon tetrachloride ( $\text{CCl}_4$ ) is being used in research to induce liver injury [16].  $\text{CCl}_4$  is assumed to initiate free radical-mediated lipid peroxidation, leading to the accumulation of lipid derived oxidation products and in turn liver injury and excess collagen deposition in the liver, resulting in liver fibrosis [17].

The aim of this study was to evaluate the possible protective effect of encapsulated peppermint oil against induced hepatotoxicity of male mice.

## MATERIALS AND METHODS

### Preparation of encapsulated peppermint oil:

Peppermint oil was obtained from Kato Aromatic Co., Giza [Egypt]. Gum Arabic was obtained from PRS Panreac [Espania]. Maltodextrin DE - 20 was obtained from the National CO., Maize Product Cairo [Egypt].

### Emulsion Preparation and Spray Drying:

Solutions of 20% gum Arabic were prepared by dispersing the solids in deionized water and heating at 60°C over a steam bath to facilitate solubilization. The solutions were allowed to cool to room temperature before storing at 40°C overnight. The peppermint oil (20% w/w) was added and homogenized vigorously (10000 rpm for 5 min.) with an Ultra Turrax M- 45 homogenizer at ambient temperature. The obtained emulsion was maintained under slow agitation during spray drying. The emulsion was spray dried in a BUCHI 190 Spray Dryer with an evaporation rate of 1.5 kg /1 hour and a chamber diameter of 10 cm, equipped with a pressurized nozzle operating at 5 atmospheres. Feed is metered into the dryer by a peristaltic pump. Drying conditions performed using inlet temperature 200°C. Powder was collected at the bottom of dryer cyclone and kept in air tight containers at 80°C until analyzed as previously described an chemical composition of peppermint oil was also determined [18].

### Animals and Experimental design:

Thirty Swiss albino male mice of 25–30 g body weight and of five weeks age, obtained from the Animals House of the National Research Center, Egypt were used during this experiment. The animals were acclimatized one week prior to the experiments and were housed under standard conditions (i.e. at  $22 \pm 2^\circ\text{C}$ ; humidity: 50–55% and 12h/12h light/dark cycle), in polypropylene cages and fed with standard laboratory

chow pelleted diet and water ad libitum. The standard balanced diet was consisted of casein 15 g/100g, starch 43.7 g/100g, sucrose 21.8 g/100g, fat 15 g/100g, salt mixture 3.5 g/100g and vitamin mixture 1 g/100g, according to Varna et al., [19]. All the animal treatment was conducted in accordance with the guideline approved by Institutional Animal Ethics Committee.

Animals were divided into five equal groups. Animals of group 1 received no treatment and served as control. Animals of group 2 were administered carbon tetrachloride (CCl<sub>4</sub>) orally by gavage at dose of 2ml/Kg body weight (diluted 1:1 in olive oil) for three consecutive days to produce liver injury. Animals of group 3 administered orally by gavage encapsulated peppermint oil at dose 1mg/kg body weight, this dose is equal to 1/10 of LD50 (LD = 2490 mg/kg body weight) which was dissolved in 10 ml water daily for 10 consecutive days. Animals of group 4 were orally administered encapsulated peppermint oil at the dose (1mg/kg body weight) for 10 days and CCl<sub>4</sub> for the last 3 days before sacrificed. Mice of group 4 were administered orally by gavage gum Arabic as a carrier at dose [1mg/kg body weight) for ten days. At the end of experiment, blood samples were collected from all groups and then sacrificed. Sera was harvested and kept at -20°C till hormonal assaying.

**Hormone assay and antioxidant analysis:**

Testosterone was analyzed using commercially available ELISA kits. Intra-assay and inter-assay coefficient of variations were 4.5 and 6.3%. The sensitivity of assay was 0.038 ng/ml. Reactive oxygen metabolites in terms of lipid peroxidation [20] and reduced glutathione [21] were measured in blood serum of all animals. Blood serum glutathione reduced GSH was determined by spectrophotometer using the Bio-diagnostic kit [Cat number GR2511]. Lipid peroxidation product (Malondialdehyde, MDA) was assayed by the measurement of MDA levels on the base of MDA reacted with thiobarbituric acid and resultant color read with spectrophotometer at 532nm using commercially supplied kits (Bio-diagnostic, Kit number MD2529).  
Histopathological study:

For histopathological studies, samples of liver tissues were cut and fixed in 10% formalin saline. After the fixation, the tissues were washed and processed by standard histology procedures and embedded in paraffin. Tissue sections were stained with haematoxylin and eosin (Hx&E) according to Drury and Wallington [22]. The stained slides were examined under a light microscope.

**Statistical Analysis:**

Analysis of variance [ANOVA] was processed using statistical package for social science (SPSS) software version 16 [23] and data were presented as means ± S.E.M. [Standard error of mean] P ≤ 0.05. Duncan's Multiple Range test was used to differentiate between significant means.

**RESULTS**

It could be noticed from table (1) that there is significant increase (P<0.01) in testosterone concentrations in carbon tetrachloride (CCl<sub>4</sub>) treated rats (11.74±1.19) and carbon tetrachloride (CCl<sub>4</sub>) plus encapsulated peppermint treated group (16.15±2.20) compared to control (7.32±1.37), gum Arabic (7.47±1.23) and encapsulated peppermint (6.48±1.48) treated animals. Neither encapsulated peppermint nor gum influenced testosterone concentrations. Compared to control animals, CCl<sub>4</sub> plus encapsulated peppermint treated animals had in significantly (P<0.0001) nearly similar GSH levels, but gum Arabic, CCl<sub>4</sub> and peppermint treated animals had significantly high GSH (Table 1).

**Table (1): Blood serum concentrations of testosterone, glutathione reduced and lipid peroxide product malondialdehyde.**

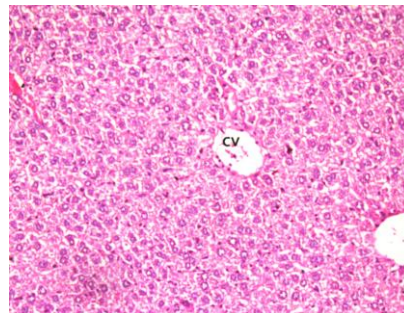
Parameter	Control	Gum Arabic	Mint oil	CCl <sub>4</sub>	CCl <sub>4</sub> +Mint oil
Testosterone**	7.32 <sup>a</sup> ±1.37	7.47 <sup>a</sup> ±1.23	6.48 <sup>a</sup> ±1.48	11.74 <sup>ab</sup> ±1.19	16.15 <sup>b</sup> ±2.20
GSH***	10.69 <sup>a</sup> ±0.93	31.39 <sup>b</sup> ±0.07	42.13 <sup>c</sup> ±7.59	24.19 <sup>b</sup> ±0.47	13.24 <sup>a</sup> ±1.64
MDA*	18.18 <sup>a</sup> ±2.01	49.82 <sup>b</sup> ±19.14	46.31 <sup>b</sup> ±8.72	27.27 <sup>ab</sup> ±0.93	20.86 <sup>ab</sup> ±10.79

Encapsulated peppermint oil (Mint oil), \*P>0.05, \*\*P<0.01, \*\*\*P<0.0001, Means with different superscripts are significantly different at p<0.05

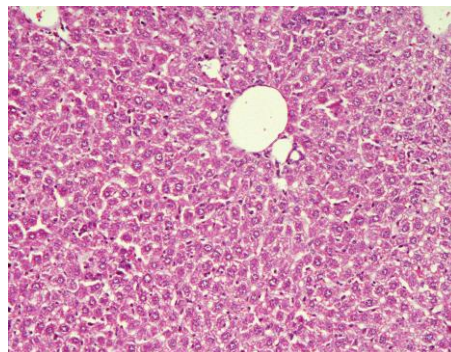
MDA levels significantly increased in gum Arabic and peppermint treated animals compared to controls but insignificant ( $P=0.09$ ) increase was observed in other groups compared to controls (Table 1).

**Histopathological results:**

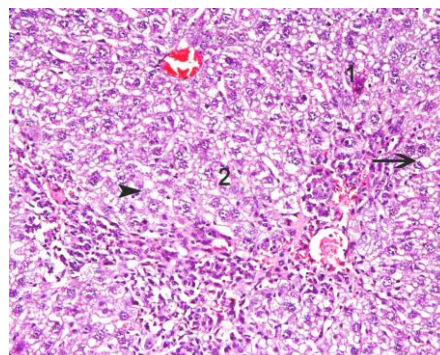
The microscopic examination of control liver sections of mice showed normal architecture of liver lobules and hepatocytes arranged in cords radiating from the central vein and separated by blood sinusoids (Figure 1). Meanwhile, no pathological change could be observed in liver treated with Arabic gum (Figure 2). Whereas, carbon tetrachloride revealed sever cellular degeneration in the form of vacuolar and fatty degeneration in liver tissue. In addition, fibrosis and marked inflammatory cellular infiltration, dilatation and congestion of portal vessels, necrosis and karyolysis of some nuclei and loss of liver architecture were observed as shown in (Figure 3, 4).



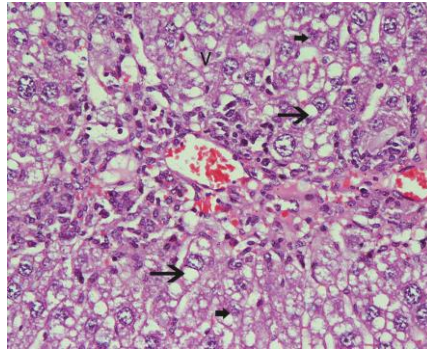
**Figure (1):** Micrograph of liver section of normal control mice showing normal architecture of liver lobule, CV central vein and blood sinusoids ( Hx&Ex200)



**Figure (2):** Micrograph of liver section of mice treated with gum Arabic showing normal structure of liver tissues, hepatocytes nearly normal (Hx & E x200).

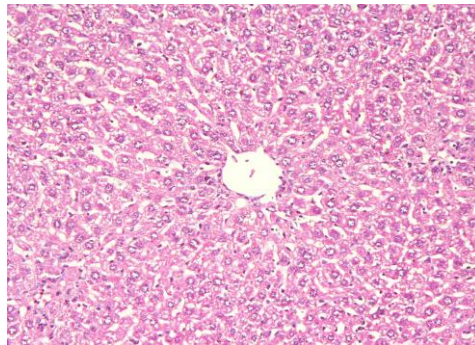


**Figure (3):** Micrograph of liver section of mice treated with  $CCl_4$  showing sever damage of liver tissues, fibrosis and marked inflammatory cellular infiltration, congestion of central vein, (Hx&E x200).

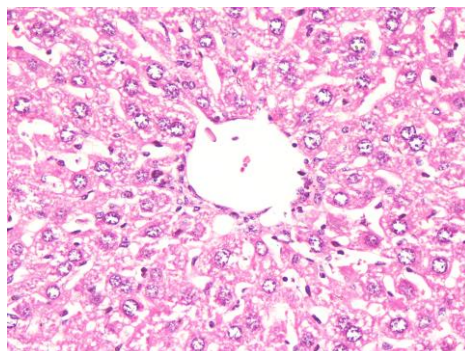


**Figure (4):** High power of liver section of mice treated with  $\text{CCl}_4$  showing marked vacuolar degeneration (V), fatty degeneration (big arrow) of hepatocytes, signs of nuclear degeneration in the form of necrosis (1), karyolysis (small arrow) (Hx&E x400) .

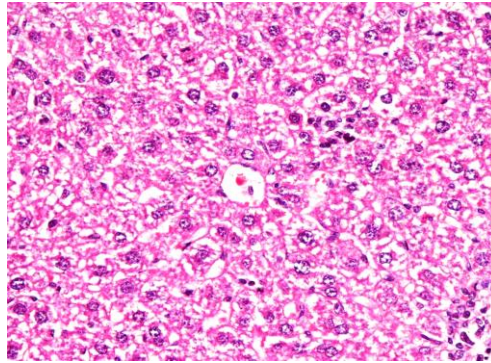
The liver of mice subjected to encapsulated peppermint oil showed minute cytoplasmic vacuoles and hypertrophied kupffer cells (Figure 5, 6). The administration of peppermint oil to mice treated with  $\text{CCl}_4$  ameliorated the pathological changes of  $\text{CCl}_4$ . No fatty degeneration, reduction of fibrous tissue, moderate cellular infiltration was observed (Figure 7, 8).



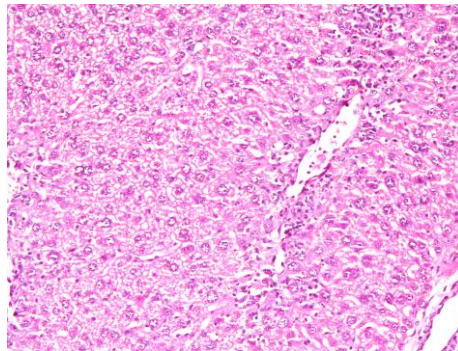
**Figure (5):** Micrograph of liver section of mice treated with encapsulated peppermint oil showing that the liver tissues almost normal, however, mild infiltrative inflammatory cells and the kupffer cells are hypertrophied (Hx&E x200).



**Figure (6):** Micrograph of liver section of mice treated with encapsulated peppermint oil showing normal structure of liver tissues, minute cytoplasmic vacuoles, mild cellular infiltration and hypertrophied of kupffer cell (Hx&E x400).



**Figure (7):** Micrograph of liver section of mice treated with  $\text{CCl}_4$  and encapsulated peppermint oil showing some improvement represented in absence of fatty degeneration, no fibrous tissue, minute vacuolar degeneration, while, the hepatic tissue relatively normal around central area. (Hx&E x400)



**Figure (8):** Micrograph of liver section of mice treated with  $\text{CCl}_4$  and encapsulated peppermint oil showing minimal fibrous tissue, mild diffusion of inflammatory cell infiltration in sinusoids and around portal area (Hx&E x400).

## DISCUSSION

The slight insignificant decline of testosterone recorded in mice treated with encapsulated peppermint oil was also observed in rats treated with *Mentha piperita labiatae* and *Mentha spicata labiatae* herbal tea at doses of 20 g/L *M. piperita* tea, 20 g/L *M. spicata* tea, or 40 g/L *M. spicata* tea compared with control [24]. Moreover, *M. piperita* ontesticular tissue caused segmental maturation arrest in the seminiferous tubules; however, the effects of *M. spicata* extended from maturation arrest to diffuse germ cell aplasia in relation to the dose [24]. Both peppermint oil and tea [24] had the ability to decrease testosterone either directly by causing minute cytotoxicity to leydig cells inhibiting their secretions or indirectly by decreasing lutenizing hormone (LH) from the pituitary gland [24]. The significant increase of testosterone in mice treated with  $\text{CCl}_4$  not only related to its common hepatotoxic effects [25], but also the exposure to  $\text{CCl}_4$  has been reported to induce free radical generation in the testis and blood [26]. Gum Arabic had no influence on testosterone as it attained an anticancer activity to human hepatocellular carcinoma cells when conjugated with curcumin and this conjugate exhibited enhanced accumulation and toxicity in cells due to the targeting efficiency of the galactose groups present in gum Arabic [27].

Carbon tetrachloride ( $\text{CCl}_4$ ) is a potent hepatotoxin capable of causing experimental hepatic damage through the cytochrome P450-mediated activation to free radicals and reactive species, which in turn induce hepatocyte necrosis, inflammation and, subsequently, lead to liver fibrosis. Highly reactive radicals generated from  $\text{CCl}_4$ , as trichloromethyl and trichloromethyl peroxy affect the hepatocytes and cause structural and functional changes of their cellular membranes [28].  $\text{CCl}_4$  is one of the most commonly used hepatotoxins in the experimental study of liver injury [29]. The present study demonstrated hepatotoxicity of  $\text{CCl}_4$  seems to be mediated by reactive metabolite trichloromethyl ( $\text{CCl}_3$ ) free radical [30]. These activated radical bind covalently with the macromolecules and induce peroxidative degeneration of membrane lipids of endoplasmic reticulum rich poly unsaturated fatty acids [25]. This leads to the formation of lipid peroxides, which in turn give products like malondialdehyde that cause damage to the membrane.  $\text{CCl}_4$  intoxication induced a severe centrilobular necrosis and loss of hepatic tissue, with mild inflammatory cell infiltration around the central vein

region and sinusoidal spaces leading to infiltration of inflammatory cells that contributed to hepatic oxidative stress and fibrogenesis [31]. This lipid peroxidative degeneration of biomembranes is one of the principal causes of hepatotoxicity of  $\text{CCl}_4$  [32]. The result of the present study demonstrated that  $\text{CCl}_4$  caused vacuolar and sever fatty degeneration, nuclear degeneration and cell necrosis of liver cells.

The mechanism of this change may be produced by organelle injury at different subcellular foci, metabolic disorder, and deficiency of essential lipotropic factors or excessive mobilization of fat from extra hepatic [33]. The second phase of  $\text{CCl}_4$ -induced hepatotoxicity involves the activation of Kupffer cells, which is accompanied by the production of pro-inflammatory mediators [34]. In the present results, sever inflammatory cellular infiltration, fibrous septa radiating from the portal tracts in  $\text{CCl}_4$  treated group was observed. Hepatic fibrosis is usually initiated by hepatocytes damage, leading to recruitment of inflammatory cells and platelets, activation of kupffer cells and subsequent release of cytokines and growth factors [35]. In rats,  $\text{CCl}_4$  significantly decreased of GSH level in liver tissue homogenates but a significant increase in lipid peroxidation of liver tissue homogenate [36].

Peppermint is one of the essential oils that was shown to have significant antioxidant activities, provide good defense against oxidative damage and associated health effects [37]. In vitro, peppermint oil has been reported to show anti-inflammatory, antimicrobial, and antifungal activities as well as strong antioxidant activity, and antiallergenic and antitumor actions [38,39]. In addition, *M. piperita* extract was reported to have free radical-scavenging activity [40]. Peppermint oil has an excellent safety profile with no known side effects or toxicity [41]. The minute hepato-cytotoxicity represented by minute cytoplasmic vacuoles, mild cellular infiltration and hypertrophied of kupffer cell and the significant increase of GSH and MDA of the present study indicated that in acute oral studies peppermint oil was reported to have minimally toxic [42]. In rats, short-term and sub-chronic oral studies reported cyst like lesions in the cerebellum that were given doses of peppermint oil containing pulegone, pulegone alone, or large amounts of menthone [42].

Histopathological evaluation of rats treated with the same dose of 20g/L *Mentha piperita* Labiatae and *Mentha spicata* Labiatae tea and a 40g/L *Mentha spicata* Labiatae revealed a mild to severe degree of hepatic damage when compared to the control group. In *Mentha piperita* Labiatae, there was only minimal hepatocytes degeneration. In *Mentha spicata* Labiatae (20g/L and 40g/L), there were granular or ballooning hepatocyte degeneration and necrosis, sinusoidal and central vein dilatation and reported also lipid peroxidation and hepatic damage occurs after *M. piperita* and *M. spicata* administration in rat liver and the damage seems to be dose dependent [43]. Contrary to the slight toxic effects of peppermint oil [42] and encapsulated peppermint oil of the present study, when administered to hepatotoxic induced animals it had a sort of protective effect represented by decreased concentrations of GSH and MDA to values nearly similar to control. The liver, which is rich in GSH, supplies this antioxidant to various extrahepatic tissues via a distinct GSH transport system [44]. GSH maintains the integrity of the liver when the organ is challenged by a wide variety of xenobiotics, ROS and toxic compounds [45]. The depletion of GSH resulting from increased utilization to scavenge lipid peroxides may shift the redox status towards oxidative stress. The GSH content in liver and lung tissues was significantly elevated suggesting a protective role of mint extract [40]. Compared to control rats, those received 20g/L *M. spicata* tea of drinking water had significantly increased GSH-Px activities and the TBARS level were significantly increased [43]. As well as, the extract of *Mentha piperita* leaves decreased the levels of lipoperoxides and increased sulfhydryl groups in liver showed strong scavenging activity in Swiss albino mice subjected to induced lung carcinogenicity and mutagenicity [40]. Moreover, a moderate protective effect of peppermint oil against the toxicity of  $\text{CCl}_4$  was also represented by relatively normal histological pattern of hepatocytes, few of them were still vacuolated, less inflammatory cell infiltration, fatty infiltration and fibrous tissue was diminished [46].

These protective effects referred to antioxidant, antimicrobial, antifungal, anticarcinogenic and antiallergic activity of peppermint oil [46] which related to the dose of administration where free radical scavenger and oxidative damage inhibitory activities of high doses of peppermint oil but at lower doses, the oil was still toxic to the cells [9]. As well as some ingredients of the peppermint oil had proved to initiate toxic effects on high doses. Short-term and subchronic oral studies reported cyst-like lesions in the cerebellum in rats that were given doses of peppermint oil containing pulegone, pulegone alone, or large amounts (>200 mg/kg/day) of menthone. With the limitation that the concentration of pulegone in these ingredients should not exceed 1%, it was concluded that *Mentha piperita* (peppermint) oil, *Mentha piperita* (peppermint)

extract, *Mentha piperita* (peppermint) leaves, *Mentha piperita* [peppermint] water are safe as used in cosmetic formulations [42]. Moreover, menthol could prevent liver damage induced by  $\text{CCl}_4$  [47].

The minimal induced hepatotoxicity could be also referred to the carrier material used to encapsulate peppermint oil [Gum Arabic] since gum Arabic from *Acacia seyal* and *Acacia senegal* is a branched-chain polysaccharide which has strong antioxidant properties, and has been used to reduce the experimental toxicity [47]. In contrast to Ahmed et al. [47], gum Arabic treated rats had decreased liver malondialdehyde (MDA) but increased glutathione (GSH) when given in drinking water for 8 weeks in a dose of 15%. The absence of hepatotoxicity in mice treated with gum Arabic of this study may be explained by the protective effect of gum Arabic by modulating the expression of hepatic oxidative stress genes, and thus can improve antioxidant status [47].

### CONCLUSION

Encapsulated peppermint oil with gum Arabic as a carrier alone may have no protective effects but its protective effect became significant when administered to intoxicated animals. Encapsulated oil need to be subjected to further studies to determine the suitable protective and safe dose and the administration period as peppermint oil effects are dose dependant.

### REFERENCES

- [1] King, A.H. (1995). Encapsulation of food ingredients. In Encapsulation and Controlled Release of Food Ingredients, Risch, S.J. and Reineccius, G.A. [eds.]. American Chemical Society, Washington, DC, Chapter 3, pp. 26–39.
- [2] Madene, A. Jacquot, M. Scher J. Desobry, S. (2006): Flavour encapsulation and controlled release – a review. *International Journal of Food Science and Technology*, 41, 1–21
- [3] Risch, S.J. [1995]. Review of patents for encapsulation and controlled release of food ingredients. In Encapsulation and Controlled Release of Food Ingredients, Risch, S.J. and Reineccius, G.A. (eds.). American Chemical Society, Washington, DC, Chapter 18, pp. 197–203.
- [4] DeZarn, T.J. [1995]. Food ingredients encapsulation. In Encapsulation and Controlled Release of Food Ingredients, Risch, S.J. and Reineccius, G.A. [eds.]. American Chemical Society, Washington, DC, Chapter 7, pp. 75–86.
- [5] Kagami, Y., Sugimira, S., Fujishima, N., Matsuda, K., Kometani, T., & Matsumura, Y. [2003]. Oxidative stability, structure, and physical characteristics of microcapsules formed by spray drying of fish oil with protein and dextrin wall materials. *Journal of Food Science*, 68, 2248e2255.
- [6] Minemoto, Y., Hakamata, K., Adachi, S., & Matsuno, R. [2002]. Oxidation of linoleic acid encapsulated with gum arabic or maltodextrin by spray-drying. *Journal of Microencapsulation*, 19, 181e189.
- [7] Samarth RM, Panwar M, Kumar M, Kumar A. Radioprotective influence of *Mentha piperita* (Linn) against gamma irradiation in mice: antioxidant and radical scavenging activity. *Int J Radiat Biol* 2006; 82:331-7.
- [8] Jain D, Pathak N, Khan S, Raghuram GV, Bhargava A, Samarth R, Mishra PK. Evaluation of cytotoxicity and anticarcinogenic potential of *Mentha* leaf extracts. *Int J Toxicol* 2011; 30:225-36.
- [9] Sharafi SM, Rasooli I, Owlia P, Taghizadeh M, Astaneh SD. Protective effects of bioactive phytochemicals from *Mentha piperita* with multiple health potentials. *Pharmacogn Mag*. 2010 Jul-Sep; 6[23]: 147–153.
- [10] Mahadevappa, N Divya Kittayanapallya Hanumantharaju Pooja Vishwanath Suvarna, Vinutha Moses , Soumya Chandrashekar and Shobha Gowda, 2014. Study on advanced application of mint oil. *J Adv Sci Res*, 2014, 5[4]: 01-03
- [11] Akdogan M, Kiliç I, Oncu M, Karaöz E, Delibas N. Investigation of biochemical and histopathological effects of *Mentha piperita* L. and *Mentha spicata* L. on kidney tissue in rats. *Hum Exp Toxicol*. 2003 Apr; 22[4]: 213-9.
- [12] Mora, PC, Borali, PG. [2002] *Democosmetic application of polymeric biomaterials*. N Polymers biomaterials [e.S. Dumitriu]. 2<sup>nd</sup> Edition/ New York: Marcel ekker.
- [13] Weinbreck F, Minor M, DeKruif CG [2004]: Microencapsulation of oils using whey protein/gum arabic coacervates. *J Microencapsulation* 2004, 21[6]: 667-679.



- [14] Nishi KK, Jayakrishnan A, [2005]:preparation an in-vitro evaluation of primaquine- conjugated gum arabic microspheres. *Trens Biomater Artif Organs* 18(2) 191-197.
- [15] Nishi KK, AntonyM, Jayakrishnan A, [2007]: Synthesis an evaluation of ampicillin-conjugated gum arabic microspheres for sustained release. *J Pharm Pharmacol* 59(4): 485-493.
- [16] Sadeghi H, Nikbakht M, Ghaitasi I, Sabzali S. [2008] .: Hepatoprotective effect of *Cichorium intybus* on CCl<sub>4</sub>-induced liver damage in rats. *Afr J Bioch Res*, 2: 141–144
- [17] Abdel-Moneim AM, Al-Kahtani MA, El-Kersh MA, Al-Omair MA. Free Radical-Scavenging, Anti-Inflammatory/Anti-Fibrotic and Hepatoprotective Actions of Taurine and Silymarin against CCl<sub>4</sub> Induced Rat Liver Damage. *PLoS One*. 2015 Dec 11;10(12):e0144509.
- [18] Badee, A.Z.M. Abd El- Kader, AE. and Aly, HM. [2012]: Microencapsulation Of Peppermint Oil By Spray Drying. *Australian Journal of Basic and Applied Sciences*, 6(12): 499-504.
- [19] Vrana, A., P. Fabry, L. Kazdova, & K. Zvolankova, 1978. Effect of the type and proportion of dietary carbohydrate on serum glucose levels and liver and muscle glycogen synthesis in the rat, *Nutrition and Metabolism*, 22: 313-320.
- [20] Ohkawa, H.; Ohishi, W.; Yagi, K. Assay for lipid peroxides in animal tissues by thiobarbituric acid reaction. *Anal. Biochem.*, 95, 351-358 [1979].
- [21] Tsimikas, S. Measures of oxidative stress. *Clinics in Laboratory Medicine*, 26, 571-5vi [2006].
- [22] Drury, R.A. and Wallington, E.A. [1980]: *Carletons Histological Technique*. 4<sup>th</sup> Ed., Oxford univ. press. New York, Totonto
- [23] SPSS, Statistical Package for Social Sciences, SPSS Inc., Chicago, IL, USA Copyright©for Windows, version 16.0. SPSS, 2007.
- [24] Ozguner M, Kocak A, Oncu M, Cicek E. Effects of peppermint teas on plasma testosterone, follicle-stimulating hormone, and luteinizing hormone levels and testicular tissue in rats. *Urology*. 2004, 64:394-8.
- [25] Yan-Jun L, Jie-ping Y, Zhao-Hong S, et al. *Gingko biloba* extract reverses CCl<sub>4</sub>- induced liver fibrosis in rats. *World J Gastroenterol*, 2004; 10, 1037-42.
- [26] Ahmed AA, Fedail JS, Musa HH, Kamboh AA, Sifaldin AZ, Musa TH. Gum Arabic extracts protect against hepatic oxidative stress in alloxan induced diabetes in rats. *Pathophysiology*. 2015 22(4):189-94.
- [27] James NR, Kumar PR, Raj DK, Kumary TV. Gum arabic-curcumin conjugate micelles with enhanced loading for curcumin delivery to hepatocarcinoma cells. *Carbohydr Polym*. 2015 Dec 10;134:167-74
- [28] Sun F, Hamagawa E, Tsutsui C, Ono Y, Ogiri Y, Kojo S. Evaluation of oxidative stress during apoptosis and necrosis caused by carbon tetrachloride in rat liver. *BBA-Mol Basis Dis*. 2001;1535:186–191.
- [29] Johnston, D. and Kroening, C. [1998]. Mechanism of early carbon tetrachloride toxicity in cultured rat hepatocytes. *Pharmacol. Toxicol.*, 83:231-239.
- [30] Pohl L, Schulliek R, George J. Reductive oxygenation mechanism of metabolism of carbon tetrachloride phosgene by cytochrome p-450. *Mol Pharmacol*, 1984; 25, 318-24.
- [31] Vladimir-Knežević S, Cvijanović O, Blažeković B, Kindl M, Štefan MB, Domitrović R. Hepatoprotective effects of *Micromeria croatica* ethanolic extract against CCl<sub>4</sub>-induced liver injury in mice. *BMC Complement Altern Med*. 2015 Jul 15;15:233.
- [32] Cotran, R.S.; Kumar, V. and Robbins, S.L. [1994]: cell injury and cellular death. IN : *Robbin s Pathologic Basis of disease*, 5<sup>th</sup> Ed., prism Book Pvt. Ltd., pp.379-430.
- [33] Poli, G.; Gravela, E.; Albono, E.; and Dianzani, M. [1979]: Study on fatty liver with isolated hepatocytes. The action of carbon tetrachloride on lipid peroxidation and triglyceride synthesis and secretion. *EXP. Mol. pathol.*, 30:116-127
- [34] Eidi A, Mortazavi P, Tehrani M E , Rohani A H , Safi S [2012] : hepatoprotective effects of pantothenic acid on carbon tetrachloride-induced toxicity in rats. *EXCLI Journal* 11:748-759
- [35] Bruck, R.; Shirin, H.; Aeed, H.; Matas, Z.; Homchman, A.; Pines, M. and Avni, Y. [2001]; Prevention of hepatic cirrhosis in rats by hydroxyl radical scavengers. *J. hepatol.*, 35:457-64.
- [36] Ganie SA, Zargar BA, Masood A, Zargar MA. Hepatoprotective and antioxidant activity of rhizome of *Podophyllum hexandrum* against carbon tetra chloride induced hepatotoxicity in rats. *Biomed Environ Sci*. 2013 Mar;26(3):209-21.
- [37] Saleh MA, Clark S, Woodard B, Deolu-Sobogun SA. Antioxidant and free radical scavenging activities of essential oils. *Ethn Dis*. 2010 Winter;20[1 Suppl 1]:S1-78-82.
- [38] Inoue, T., Sugimoto, Y., Masuda, H. and Kamei, C. [2001] Effect of peppermint [*Mentha piperita* L.] extracts on experimental allergic rhinitis in rats. *Biol. Pharm. Bull.*, 24, 92-95.
- [39] Comar, K.M. and Kirby, D.F. [2005] Herbal remedies in gastroenterology. *J. Clin. Gastroenterol.*, 39, 457-468.

- [40] Samarth RM, Panwar M, Kumar M, Kumar A. Protective effects of *Mentha piperita* Linn on benzo(a)pyrene-induced lung carcinogenicity and mutagenicity in Swiss albino mice. *Mutagenesis* 21 : 61–66, 2006
- [41] Bravo, L., [1998]: polyphenols: chemistry, dietary sources, metabolism, and nutritional significance. *Nutr. Rev.*, 56:317-333.
- [42] Nair B. 2001: Final report on the safety assessment of *Mentha Piperita* [Peppermint] Oil, *Mentha Piperita* [Peppermint] Leaf Extract, *Mentha Piperita* [Peppermint] Leaf, and *Mentha Piperita* [Peppermint] Leaf Water. *Int J Toxicol.* 2001;20 Suppl 3:61-73.
- [43] Ozguner M, Aydin G, Gokalp O. Investigation of biochemical and histopathological effects of *Mentha piperita* Labiatae and *Mentha spicata* Labiatae on liver tissue in rats. *Hum Exp Toxicol.* 2004 Jan;23(1):21-8.
- [44] Locigno, R. and Castronovo, V. [2001] Reduced glutathione system: role in cancer development, prevention and treatment [review]. *Int. J. Oncol.*, 19, 221–236.
- [45] Lu, S.C. [1999] Regulation of hepatic glutathione synthesis: current concepts and controversies. *FASEB J.*, 13, 1169–1173
- [46] Kaushik P1, Kaushik D, Khokra SL. Ethnobotany and phytopharmacology of *Pinus roxburghii* Sargent: a plant review. *J Integr Med.* 2013 Nov;11(6):371-6.
- [47] Ahmed FF, Cowan DL, Sun AY. Detection of free radical formation in various tissues after acute carbon tetrachloride administration in gerbil. *Life Sci.* 1987; 41, 2469-75.
- [48] Janbaz KH, Gilani AH. [2002]: Menthol prevents liver damage induced by paracetamol and CCl<sub>4</sub>. *Pakistan J. Biol. Sci.* 5:1101-1103