

# Research Journal of Pharmaceutical, Biological and Chemical Sciences

## Urachal Actinomycosis: Case Report.

D Pon Jeeva Mathan\*, T Praveen Kumar, R Jeyaraman, P Suresh Babu.

Department Of General Surgery, Sree Balaji Medical College and Hospital, Bharath University, Chrompet, Chennai -600044, Tamil Nadu, India.

### ABSTRACT

A 50 Yr Old Male Presented With Lower Abdomen Pain and Difficulty In Voiding. For 2 Months. An Abdomen CT revealed an irregular mass seen superior to dome of urinary bladder adherent to mesentery, ileum and sigmoid colon. Cystoscopy was done and no tumour was detected and bladder dome was intact differential diagnosis included a urachal tumour with invasion to adjacent organs or a chronic inflammatory disease. Partial cystectomy and limited resection of involved ileal segments was done and final pathologic report was consistent with urachal actinomycosis. Urachal Actinomycosis Is an uncommon disease that has rarely been reported. it is a chronic suppurating inflammatory disease caused mainly by actinomycosis israeli. We report a case of urachal actinomycosis that presented as lower abdomen pain and difficulty in voiding.

**Keywords:** Urachal actinomycosis , lower abdomen pain , cystoscopy, voiding

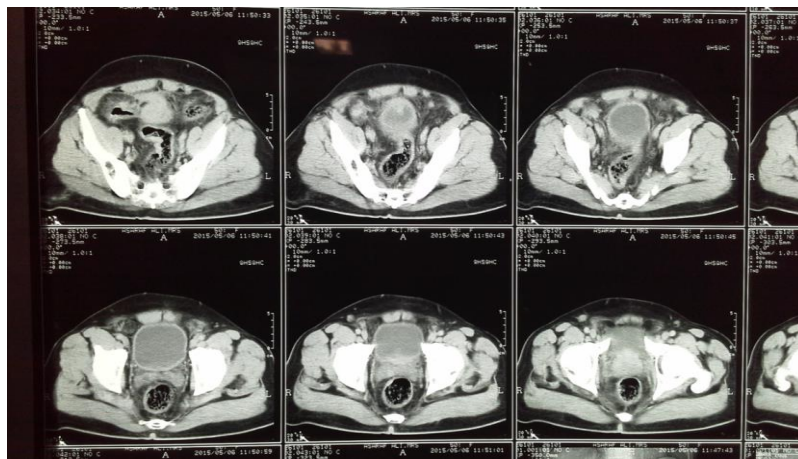
*\*Corresponding author*

**CASE REPORT**

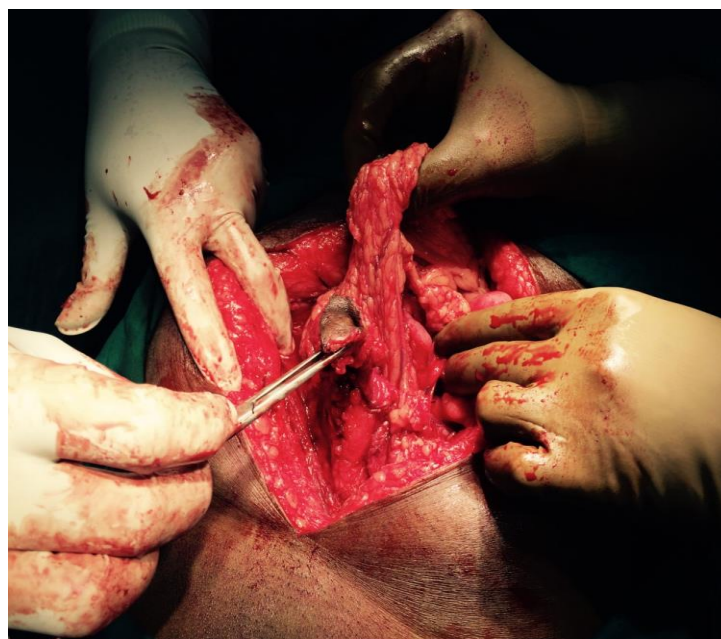The patient, a 50 yr old male hails from nagore came with complaints of lower abdomen pain and difficulty in voiding for 2 months. He had history of dribbling of urine and history of dysuria. There was history of previous appendectomy done 10 yrs back. He neither had any history of haematuria, vomiting, fever, weight loss nor loss of appetite [1,2].

On examination he is a well built individual who was adequately nourished. On inspection his umbilicus was normal there was no discharge, sinuses nor dilated veins present over it. On palpation we could appreciate an ill defined mass of 6\*5 cm [3] which was palpable at the suprapubic area extending to the right side. It was not warm, not tender, surface was smooth and firm in consistency the inferior border is not made out clearly. The skin over the swelling is normal there was no palpable regional lymph nodes and the external genitalia was normal. On per rectal examination we could clearly see grade ii prostate enlarged.

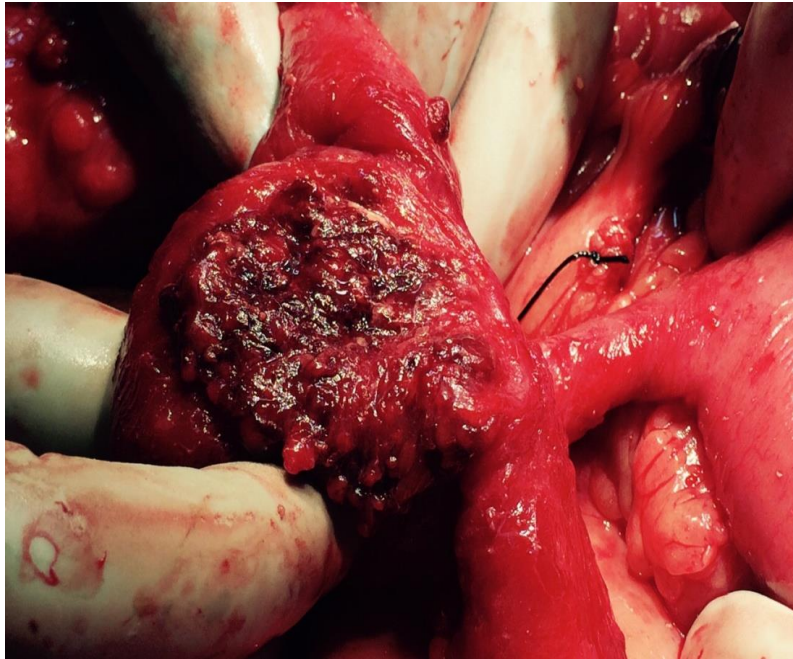
Routine blood investigations were done in which CBC showed leucocytosis. His x ray chest was normal and his cect revealed enlarged prostate [4], thickened urinary bladder wall in dome, an irregular mass seen superior to dome of bladder which was adherent to mesentery, ileum and sigmoid colon. Urachal mass with infiltration [5]. On cystoscopy [6] there was no tumour detected and bladder dome was intact.



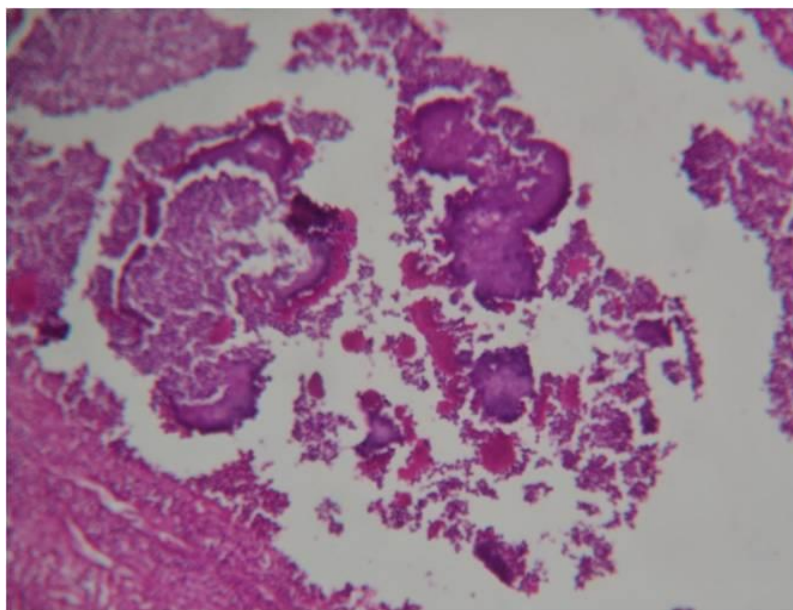
**Figure 1: Clearly See the Mass Infiltrating**



**Figure 2: In This Urachal Tract Which Ended In a Diffuse Mass Along With Ileal Loops and Mesentery**



**Figure 3: This Picture Shows the Mass**



**Figure 4: This Shows Chronic Inflammatory Fibrotic Lesion Enclosing Colonies of Actinomyces israelii**

### DISCUSSION

Actinomyces is a filamentous gram positive bacillus, “myces”- its a greek meaning for fungus. Thought by early microbiologist to be fungi because of its morphology and the disease they cause, it’s a chronic suppurative disease which spreads by direct extension through sinuses .They require disruption of the mucosal barrier to cause disease.

Most commonly its caused by Actinomyces israelii, less commonly by A. gerencseriae, A. Naeslundii, A. viscosus, A. meyeri, A. propionica. Its shows fungus like features like branching in tissues. The filaments frequently segment during growth to produce pleomorphic, diptheroidal or club shaped cells. It’s strictly anaerobic, gram positive, non-motile, non-proteolytic and catalase negative. It’s a part of normal mouth and gut flora. It occurs in the following areas, cervicofacial infection is due to poor oral hygiene, lumpy jaw which

follows tooth extraction, thoracic infection is from aspiration, abdominal infection is from perforated gut or ruptured appendix, foot infection from bacteria in the soil, and it is not a communicable disease. The main signs and symptoms of abdominal actinomycosis are mild fever, weight loss, fatigue, constipation or diarrhoea, stomach pain, nausea, vomiting, noticeable lump in the lower abdomen, appearance of sinus tracts on the surface of the abdomen. The important findings will be from indurated masses with fibrous walls and central loculations with pus, as the pus contains "sulphur granules" which is gritty yellow white which will be a average diameter of 2mm. Composed of mycelia mass. It is a chronic infection. The important investigation which has to be done is specimens for pus, sputum and tissue biopsy. Microscopic examinations may reveal sulphur granules. Culture medium used will be thioglycolate medium and BHI [brain heart infusion]. Gas liquid chromatography of metabolic byproducts is done now a days. The main stay of management will be surgical drainage of abscess followed by effective medical management. The drug of choice would be penicillin G the patients allergic to penicillin might switch over to clindamycin {1.2gm} imipenem {1gm} cephalosporins and erythromycin is also used. Conventional therapy is using high dose penicillin of dosage 18-24 million u daily for 2-6 weeks followed by oral penicillin for a period of 6-12 months. Routinely we give 1-6 million u of penicillin daily for 2-6 weeks. In severe cases 12 million u /day is not excessive. Now a days prophylactic penicillin is given to patients who has recurring infection especially before oral surgery [7].

#### REFERENCES

- [1] Hamid D, Baldauf JJ, Cuenin C, Ritter J. Eur J Obstet Gynecol Reprod Biol. 2000;89:197–200.
- [2] Sergent F, Marpeau L. J Chir 2004;14:150–156.
- [3] Filipović B, Milinić N, Nikolić G, Ranthelović T. J Gastroenterol Hepatol. 2005;20:517–520.
- [4] Das N, Lee J, Madden M, Elliot CS, Bateson P, Gilliland R Int J Colorectal Dis. 2006;21:483–484.
- [5] Dogan NU, Salman MC, Gultekin M, Kucukali T, Ayhan A. Int J Gynaecol Obstet. 2006;94:58–59.
- [6] Kodali U, Mallavarapu R, Goldberg MJ. Endoscopy 2003;35:451–453.
- [7] Harsch IA, Benninger J, Niedobitek G, Schindler G, Schneider HT, Hahn EG, Nusko G. Endoscopy 2001;33:1065–1069.