

# Research Journal of Pharmaceutical, Biological and Chemical Sciences

## Prostate Stromal Sarcoma: Case Report.

KT Chittibabu\*, P Sasikumar, KS Ravishankar, and P Sureshbabu.

Department of General Surgery, Sree Balaji Medical College & Hospital, Bharath University, Chrompet, Chennai – 600044, Tamil Nadu, India.

### ABSTRACT

Prostate stromal sarcoma is quite rare, comprising only 0.1–0.2% of all prostate cancers. Here, we report one case of prostate sarcoma in a 42-year-old man, presented with difficulty in passing urine and difficulty in passing stools. Transrectal ultrasound showed a large well defined lesion with heterogenous, echotexture and lobulated outline arising from right half of the prostate. MRI pelvis revealed prostatic stromal sarcoma. Pelvic evisceration was performed; pathology revealed high-grade pleomorphic sarcoma.

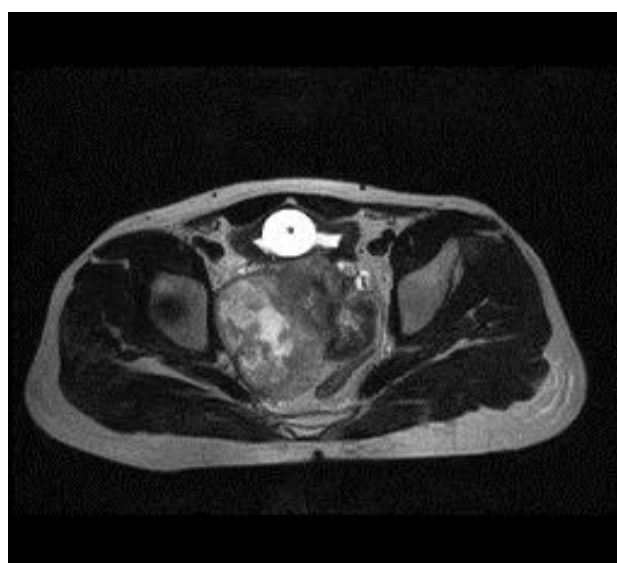
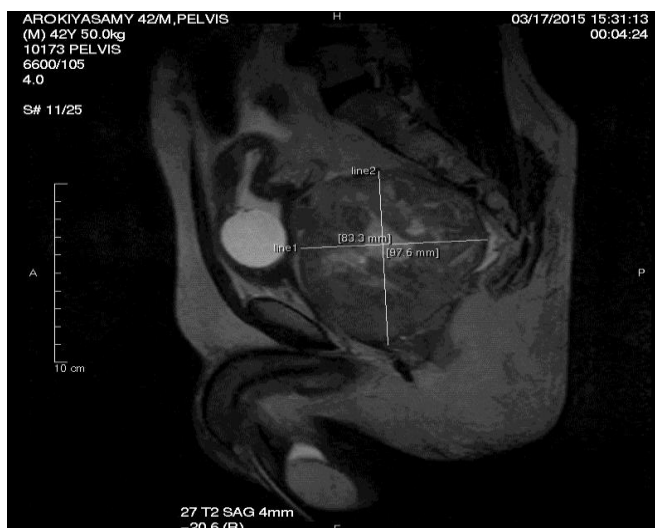**Keywords:** prostrate, sarcoma, MRI.

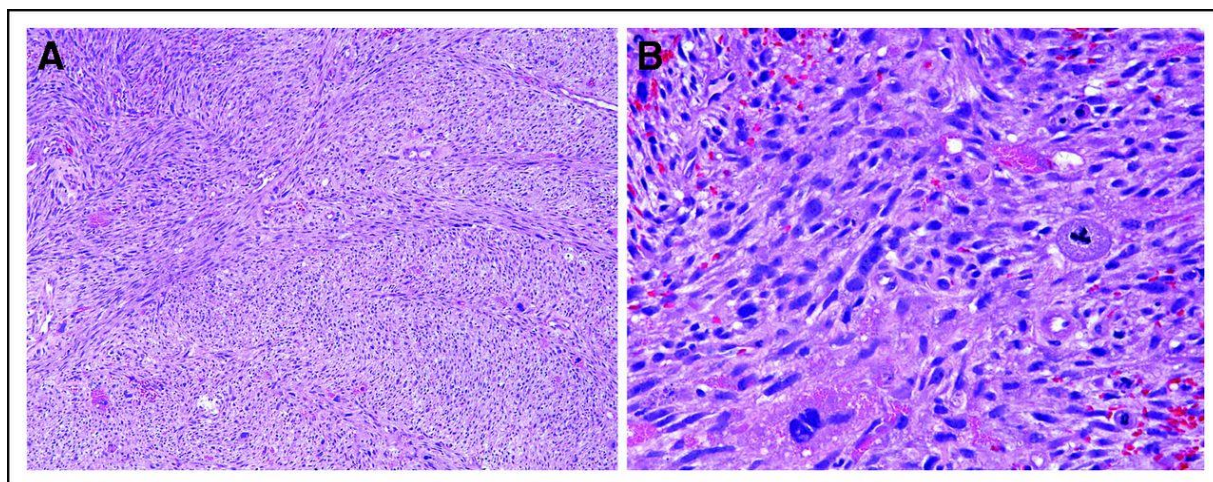
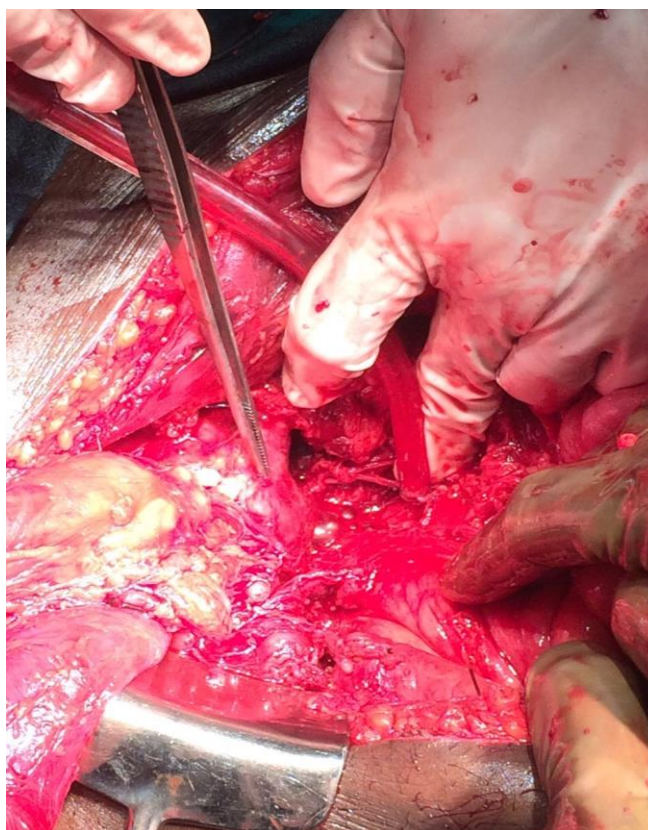*\*Corresponding author*

**Case Report**

A 42 year old male came with complaints of difficulty in passing urine and passing stools associated with abdominal pain which was colicky and intermittent. He had history of loss of weight and loss of appetite. He had history of malena. He had no history of fever, vomiting & trauma or similar complaints in the past. On Examination, Lower abdomen was distended and tender. No mass palpable. No spine tenderness observed. Per rectal examination revealed 3\*2 cm mass palpable in the anterior aspect of the rectum which was hard in consistency. No bleeding per rectum noted. Glove stained with normal fecal matter. Baseline investigations were done. PSA was negative. In ultrasound abdomen carcinoma of the prostate to be considered. Which followed by TRUS, A large well defined lesion with heterogenous echotexture and lobulated outline measuring 7.5 x 6.9 cm seen arising from right half of prostate. Lesion seen displacing the prostatic urethra and foleys towards left side. Few cystic areas noted within. MRI Pelvis proved Large heterogenous lesion with lobulated margins noted arising from the prostate. CT confirmed a large heterogenously enhancing mass lesion with lobulated margins, arising from the prostate gland and seen extending posteriorly and superiorly with possibilities of Prostatic stromal sarcoma and Prostatic Adenocarcinoma.

Transrectal prostate biopsy section suggestive of Prostatic stromal sarcoma. Pelvic Evisceration was planned. En mass resection of bladder, prostate and rectum done. No lymph nodes enlarged in pelvis. Ureterosigmoid colon anastomosis. End sigmoid colostomy done. Pathology from the resected peritoneal mass high-grade pleomorphic sarcoma that was consistent with the primary prostatic sarcoma tumor.





**DISCUSSION**

Sarcoma of the prostate is a rare lesion [4]. The disease is particularly rampant and fatal in infants, children, and young adults; most died within 1 year from the date of diagnosis. However, in older men the disease seems to possess a mortality and morbidity very similar to adenocarcinoma of the prostate. At present, there is still debate on its specific definition, pathology, and prognosis. Sarcomas arising in the prostatic stroma in children are virtually always Rhabdomyosarcomas. Sarcomas of the prostate have been classified by Melicow [4]. Included are round and Spindle cell sarcoma, fibrosarcoma, angiosarcoma, myxosarcoma and lymphosarcoma. Some authors consider stromal tumors of uncertain malignant potential (STUMPs) and stromal sarcoma to be in a spectrum of the same disease. Serum PSA is usually Negative.

Low-grade sarcomas are locally aggressive neoplasms that can show contiguous involvement of seminal vesicles and extraprostatic extension. They normally do not metastasize or involve the bladder and rectum. It has been suggested that even low-grade sarcomas can locally invade, despite having at times a relatively bland cytology. However, high-grade neoplasms are more aggressive, with a higher prevalence of

spread to the seminal vesicles, bladder, and rectum. Surgical margins are sometimes difficult to obtain because of involvement of adjacent structures. Vascular invasion has also been shown to be present in high-grade sarcomas, with selected cases demonstrating metastases to the liver and lung.

Because prostatic stromal sarcoma is a rare tumor, there are limited data about its prognosis, mostly in a very few case reports or from series with a small number of cases. Low-grade stromal sarcomas can be locally invasive, but these tumors normally do not metastasize. The high-grade counterpart is more aggressive and may lead to death mainly because of metastasis or early local invasion. A minority of patients diagnosed with high-grade stromal sarcomas showed poor short-term survival if they were diagnosed early with resection with clear margins. Cases with distant metastasis behaved variably, with some early deaths due to widespread metastases and others showing long-term survival years after their initial presentation. Patients are normally treated with radical prostatectomy or cystoprostatectomy. There are no current data to evaluate the effectiveness of chemotherapy or radiotherapy.

### CONCLUSION

Sarcoma of prostate is a rare malignant neoplasm. Early diagnosis can help in treating the patient with surgical resection.

### REFERENCES

- [1] Clatworthy HW, et al. *Cancer* 1973; 32: 1157-1160.
- [2] Ghavimi F, et al. *Cancer* 1973;32:1178-1185.
- [3] Innes Williams D, and Schistad G. *Br J Urol* 1964;36:51-65.
- [4] Melicow MM, Pelton TH, and Fish GW. *J Urol* 1943;46: 675-707.
- [5] Hamlin WB, and Lund PK. *J C'vol* 1967;97:518- 522.
- [6] Holton CP, et al. *Cancer* 1973;32: 1316.
- [7] Goodwin WE, Mims MM, and Young HH. *J Urol* 1968;99:651- 655.
- [8] Longley J. *J Urol* 1955;73:417-423.
- [9] Lowsley OS, and Kimball FN. *Br J Urol* 1934;6:328-348.
- [10] Mostofi FK, and Price EB Jr. *Tumors of the male genital system. Atlas of Tumor Pathology, Fascicle 8, Second Series. Washington, Armed Forces Institute of Pathology, 1973.*