

Research Journal of Pharmaceutical, Biological and Chemical Sciences

Variations of Superficial Volar Arch: A Cadaveric Study of the South Indian Upper Limb Specimens.

Lydia S Quadros*, Rohini Alva, and Antony Sylvan D'souza.

Department of Anatomy, Kasturba Medical College, Manipal University, Madhav Nagar, Manipal - 576104, Karnataka, India.

ABSTRACT

The superficial volar (Palmar) arch and the arteries contributing to its formation are highly variable. The arch is usually formed by the superficial branch of the ulnar artery and completed by one of the branches of radial artery, that is, the superficial palmar branch, arteria princepspollicis or arteria radialisindicis. It is rarely completed by the axis artery of the upper limb, that is, median artery which accompanies the median nerve. Fifty formalin-fixed upper extremities from of unknown sex were dissected and the superficial volar arch was observed. Thirty five(70%) hands showed complete superficial volar arch which was completed mainly by superficial branch of radial artery and in three cases it was completed by the median artery. Fifteen(30%) hands showed incomplete volar arch. Since the superficial volar arch is the main source of arterial supply to the palm, the details about its possible variations is important for the reconstructive hand surgeons.

Keywords: Hand, median artery, radial artery, ulnar artery, superficial volar arch

**Corresponding author*

INTRODUCTION

Superficial volar arch (SVA) irrigates the whole of the hand. It is mainly formed by the superficial palmar branches of the ulnar and radial arteries. The branches such as arteria princepspollicis and arteria radialisindicis (branches of radial artery) may also complete the arch from the radial side. From the convexity of the superficial volar arch, three common digital branches are given to the adjacent sides of the little and ring fingers, ring and middle fingers and middle and index fingers. Additionally, a proper digital branch is given to the ulnar side of the little finger [1].

According to Adachi, there are three categories of superficial volar arches – the type 1 (formed only by the ulnar artery), type 2 (formed by ulnar and radial arteries, which is considered to be a classic type) and type 3 (which includes the contribution from median artery) [2]. Bergmann et.al., has described five different types of complete superficial volar arches [3]. Thus the present study was conducted to find out the possible variations in the SVA.

MATERIALS AND METHODS

Fifty formalin-fixed adult upper extremities of unknown sex were dissected according to Cunningham's manual of practical anatomy [4]. The morphology of the superficial volar arch was studied and the variations were noted.

RESULTS

The formation of SVA was categorized into complete SVA and incomplete SVA. Among fifty upper extremities, thirty nine hands exhibited complete SVA and eleven hands exhibited incomplete SVA.

Complete SVA – It was further subdivided into Type 1 (complete radio-ulnar communication) (Figure. 1) and Type 2 (radio-medio-ulnar communication) (Figure. 2). Thirty four hands showed type 1 and one hand showed type 2 complete SVA.

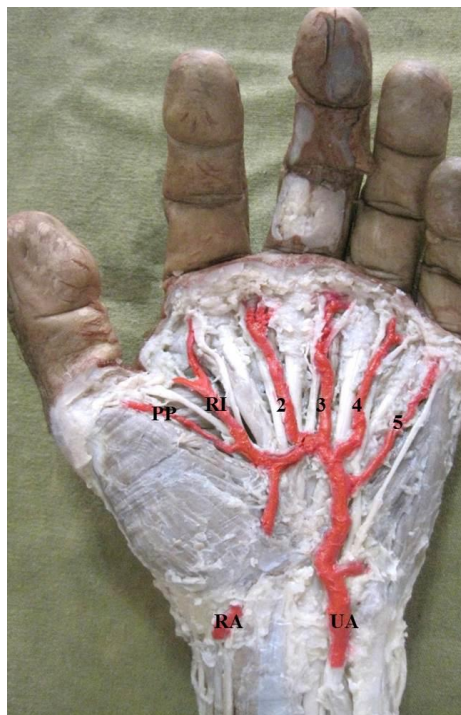

Figure 1: Left hand showing Complete SVA (complete radio-ulnar communication). UA –Ulnar artery; RA – Superficial branch of the radial artery; PP – Arteria princepspollicis, RI – Arteria radialisindicis; 2,3,4 – 2nd, 3rd and 4th common digital arteries; 5 – Proper digital artery.

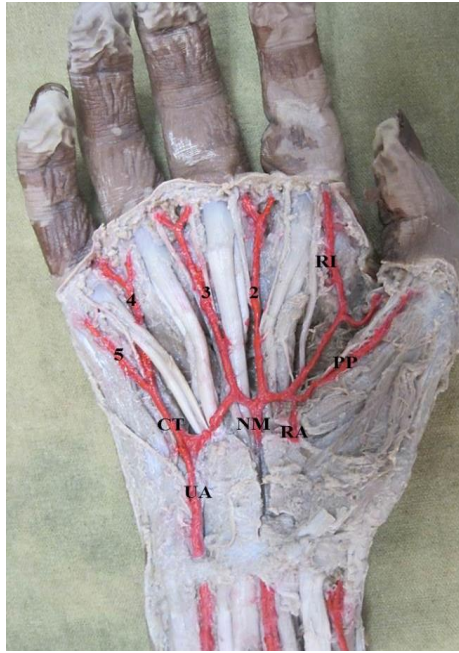

Figure 2: Right hand showing a Complete SVA (radio-medio-ulnar communication). UA – Superficial branch of ulnar artery; RA – Superficial branch of radial artery; NM – Arteria Nervi Mediana; RI – Arteria radialisindicis; PP – Arteria princepspollicis; 2, 3, 4 – 2nd, 3rd and 4th common digital arteries; 5 – Proper digital artery; CT – common trunk for 4th common digital artery and proper digital artery for the little finger.

Incomplete SVA – It was further subdivided into Type 1 (radio-ulnar type without communication between radial and ulnar arteries) (Figure. 3), Type 2 (ulnar type, with ulnar artery supplying the medial three and a half digits and rest by the superficial branch of radial artery) (Figure. 4), Type 3 (ulnar type, with ulnar artery supplying the medial three and a half digits and rest by the deep branch of radial artery) (Figure 5.). Nine hands showed type 1, five hands showed type 2 and one hand showed type 3 incomplete SVA

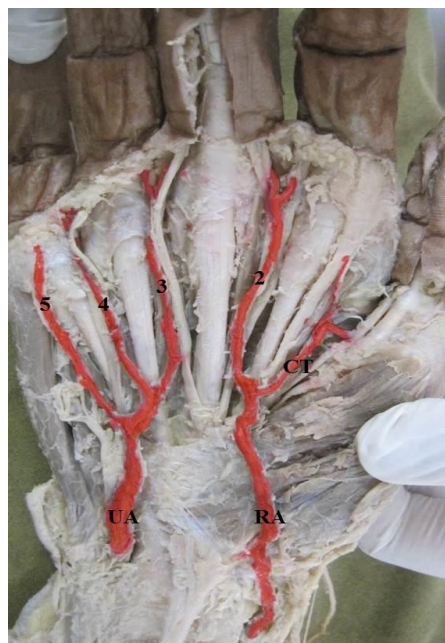


Figure 3: Right hand showing an Incomplete SVA (radio-ulnar type without communication between radial and ulnar arteries). UA – Superficial branch of ulnar artery; RA – Superficial branch of radial artery; 2, 3, 4, - 2nd, 3rd and 4th common digital arteries; 5 – Proper digital artery; CT – common trunk for arteria princepspollicis and arteria radialisindicis.

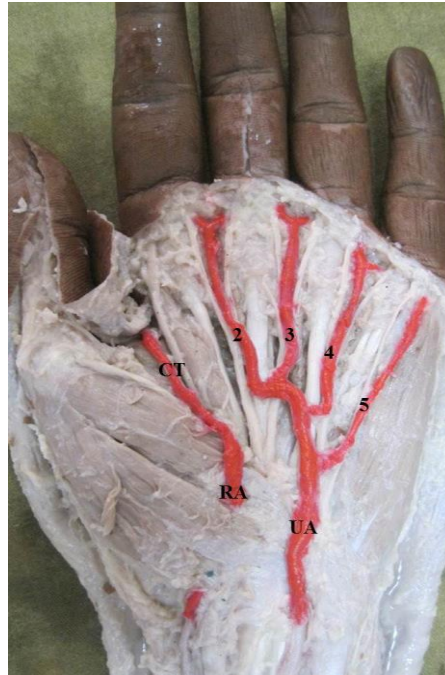

Figure 4: Left hand showing an Incomplete SVA(ulnar type, with ulnar artery supplying the medial three and a half digits and rest by the superficial branch of radial artery).UA – Superficial branch of ulnar artery; RA – Superficial branch of radial artery; 2, 3, 4 – 2nd, 3rd and 4th common digital arteries; 5 – Proper digital artery; CT – common trunk for arteria princepspollicis and arteria radialisindicis.

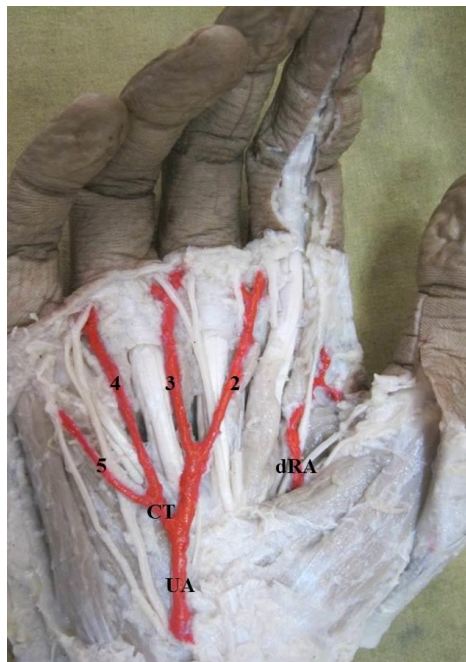


Figure 5: Right hand showing an Incomplete SVA(ulnar type, with ulnar artery supplying the medial three and a half digits and rest by the deep branch of radial artery).UA – Superficial branch of ulnar artery; dRA – Deep branch of radial artery; 2, 3, 4 – 2nd, 3rd and 4th common digital arteries; 5 – Proper digital artery; CT – common trunk for 4th common digital artery and proper digital artery for the little finger.

DISCUSSION

Thorough knowledge of the possible variations in the arterial pattern of hand is of utmost importance for the microsurgical procedures of the palm. This will reduce excessive haemorrhage. Many previous authors have reported the possible variations in the SVA [5].

It is a known fact the SVA is formed by the union of the superficial palmar branches of radial and ulnar arteries [1]. But this fact is not always true [6].

According to Adachi, 3 types of SVA are described, (a) Ulnar type – in which the major contribution was from the ulnar artery (59%); (b) Radioulnar type – in which both radial and ulnar arteries had equal contribution (32%); and (c) Medianoulnar type – in which the median and ulnar arteries contributed to the formation of SVA (9%) [2]. When compared to this study, in the present study, ulnar type was seen in two (4%) hands (Figure. 4 and Figure. 5), Radioulnar type was seen in two (4%) hands (Figure. 1) and Medianoulnar type was seen in one (2%) hand (Figure. 2).

Coleman and Anson in their elaborate study further subdivided the complete SVA from Type A through Type E and incomplete SVA from Type A through Type D [7]. In the present study, Complete SVA Type A (classical radio-ulnar type) was seen in thirty four (68%) hands (Figure. 1), Type D (radio-mediano-ulnar type) was seen in one (2%) hand (Figure. 2). Incomplete SVA Type A (superficial branches of both radial and ulnar arteries supply the palm and fingers without anastomosis between them) was seen in nine (18%) hands (Figure. 3) and Type B (Ulnar artery does not supply the adjacent sides of the thumb and index finger) was seen in five (10%) hands. Another incomplete arch (receiving a contribution from deep branch of radial artery) was not included in the classification according to Coleman and Anson.

Absence of SVA was reported by Brent et al [8] and Madhyastha et al [9]. In the present study, SVA was observed in all the fifty hands. First common palmar digital branch to the first web space was observed by Madhyastha et al [9] and Vollala et al [10]. Thus, instead of three, four common digital arteries arose from the SVA. This first common palmar digital branch further divided into princeps pollicis and radialis indicis arteries. In the present study, only one (2%) hand showed this type of variation (Figure. 1). This type of variation is of great clinical importance. Normally the first web space is supplied by the deep palmar arch.

Another type of morphological variation as reported by Bergman et al is the reinforcement of the SVA by a large median artery [3]. This median artery, which is a branch of anterior interosseous artery, usually disappears. But in some cases it persists and contributes to the formation of SVA. In the present study, was seen in one (2%) hand (Figure. 2).

CONCLUSION

The details provided in the present study, regarding the morphological variants of SVA in humans, would be enlightening for the operating hand surgeons and the orthopaedicians. The knowledge of arterial anatomy and its morphology may be of use in graft surgeries, especially when the arteries of the upper limb are harvested for the coronary artery bypass graft [11]. The variations of the SVA would also advantage in the microsurgical procedures for reconstructive hand surgeries.

In comparison to the great saphenous vein, Radial artery is mainly used as an arterial graft in Coronary artery bypass graft [12]. The radial artery forms a huge contribution in the formation of the SVA and in such techniques may be removed, in which cases the Ulnar and the persistent median arteries will furnish the arterial supply to the hand.

Techniques like Doppler ultrasound, modified Allen test, pulse oximetry and arterial angiography or a combination of the standard Allen test and ultrasonography can be used to identify the vascular pattern of the palm [13].

REFERENCES

- [1] Datta AK. The Hand. In: Essentials of Human Anatomy, 2nd edn, Vol. 3. Calcutta: Current Books International, 1995, pp. 99-100.
- [2] Adachi B. Das arteriensystem der Japaner. Kyoto, Marusen Co., 1928.
- [3] Bergman RA, Thompsons A, Afifi AK. Compendium of human anatomic variations. 1988; 74-75.
- [4] Romanes GJ. The forearm and hand. In: Cunningham's manual of practical anatomy, 15th edn, Vol. 1. Oxford: Oxford University Press. 2003, pp. 73-104.
- [5] Ikeda A, Ugawa A, Kazihara Y, Hamada N. J Hand Surg[Am] 1988;13(4): 501-509.



- [6] Loukas M, Holdman D, Holdman S. *Folia morphologica* (Warsz) 2005; 64(2):78-83.
- [7] Coleman SS, Anson BJ. *Surg Gynecol Obstet* 1961; 113: 409-424.
- [8] Brent AC, Paula Ferrada, Roger Walcott. *Brit J Surg* 2006; 60: 652-655.
- [9] Madhyastha S, Murlimanju BV, Jiji PJ, Saralaya VV, Rai A, Vadgaonkar R. *J Morphol Sci* 2011; 28(4): 261-264.
- [10] Vollala VR, Somayaji N, Bhat SM, Rodrigues V, Rao Mohandas, Pamidi N, Surendran S. *Rom J Morphol Embryol* 2008; 49(4): 585-587.
- [11] Latiff AA, Othman F, Suhaimi FH, Das S. *Arch Med Sci* 2008; 4(2):197-199.
- [12] Johnson WH 3rd, Cromartie RS 3rd, Arrants JE, Wuamett JD, Holt JB. *Ann Thorac Surg* 1998; 65(4): 1167.
- [13] Pola P, Serricchio M, Flore R, Manasse E, Favuzzi A, Possati GF. *J Thorac Cardiovasc Surg* 1996; 112(3): 737-744.