

# Research Journal of Pharmaceutical, Biological and Chemical Sciences

## Ruptured Tubal Ectopic Pregnancy with Ipsilateral Torsion Ovarian Cyst.

Iyswaria RS\*, and Saraswathi K

Department of Obstetrics and Gynaecology, Sree Balaji Medical College and Hospital, Chrompet, Chennai, 600044, Tamil Nadu, India.

### ABSTRACT

The combination of torsion of ovarian cyst with ipsilateral ruptured tubal ectopic pregnancy is a rare presentation. A 25 year old lady, regularly menstruating presented with lower abdominal pain on day 1 of her cycle. On examination, a tender mass occupying left iliac fossa was present. Per vaginal examination confirmed the abdominal findings. Our provisional diagnosis was twisted ovarian cyst. Ultrasonography was done for confirmation. To our surprise, we found ruptured left tubal ectopic pregnancy with haemoperitoneum in addition to torsion of ovarian cyst. Emergency laparotomy was proceeded with left salpingo-oophorectomy. Ruptured tubal ectopic pregnancy with ipsilateral ovarian torsion is a rare and a surgical emergency.

**Keywords:** Ovarian torsion, tubal pregnancy

*\*Corresponding author*

## INTRODUCTON

Ectopic pregnancy is implantation of the gestational sac outside the uterus. It is one of the leading causes of pregnancy related deaths during first trimester in women of childbearing age [1]. Ovarian torsion is defined as partial or complete rotation of ovarian vascular pedicle and causes obstruction to venous outflow and arterial inflow and it is the fifth common gynaecological emergency with reported prevalence of %2.7 [2, 3]. It presents as lower abdominal pain in women. It occurs mostly in the early reproductive years. Co-existence of ectopic pregnancy and ovarian torsion is rare and there are only a few case reports in the literature [4, 5].

## CASE REPORT

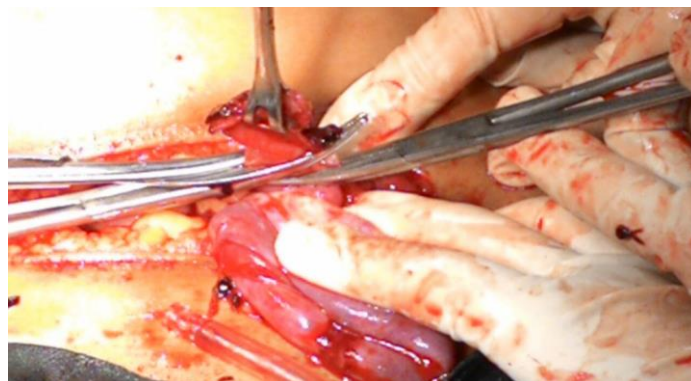A 25 year old lady with day 1 of her cycle came to the casualty with complaints of pain in the lower abdomen since morning which gradually increased in severity. Her last menstrual period was 29 days before the presentation and she had regular menstrual cycles.

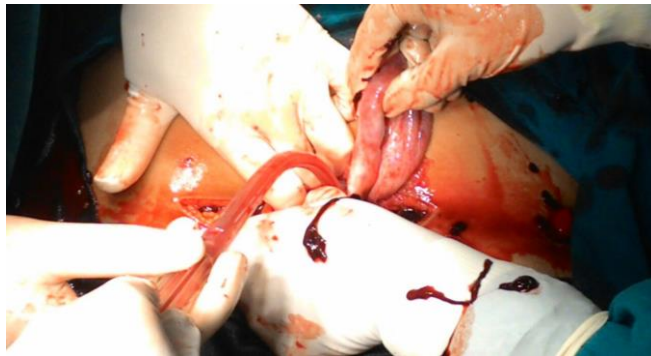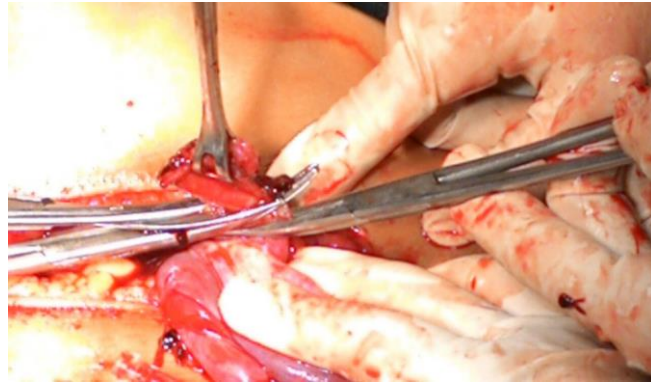
On examination, she was anxious, in pain. She was anaemic. Her BP was 100/60 mm of Hg, PR was 100/ min. On abdominal examination, tenderness in the left iliac and suprapubic region was present and a cystic tender mass was palpable in the left iliac fossa. On speculum examination, there was bleeding through os being day 1 of her cycle as elicited by the patient. Bimanual pelvic examination revealed cervix pointing upwards, uterus- retroverted, bulky, mobile with right and left forniceal tenderness and a cystic tender mass of size 6 x 5 cm in left fornix, movement of cervix was painful and blood on examining finger was seen. Therefore the provisional diagnosis was 25yr lady with torsion of left ovarian cyst for further evaluation and management. Patient was admitted and on monitoring she was found to have sustained tachycardia.

Transabdominal ultrasound revealed a left ovarian simple cyst of 6.2 x 5.2 cm, with Doppler showing no arterial and venous blood flow in the ovarian mass - evidence of torsion. To our surprise, a mixed echogenic mass was seen. In addition turbid fluid was noted in the Pouch of Douglas, bilateral paracolic gutters, Morrison's pouch, perihepatic and perisplenic regions. Endometrial thickness was 10mm. Features were suggestive of torsion of left ovarian cyst and ruptured left tubal ectopic pregnancy with moderate haemoperitoneum. Patient's haemoglobin was 9.8 g/dl and was taken up for emergency laparotomy and proceed in view of torsion of left ovarian cyst and ruptured left tubal ectopic pregnancy with haemoperitoneum.

The intra operative findings were haemoperitoneum of about 1 L – suctioned, blood clots of about 505 gm removed, ruptured ectopic site of 3 x 4 cm at ampullary end in the left fallopian tube, left ovarian cyst of about 6 x 6 cm twice twisted around its pedicle, normal right fallopian tube and ovary. Left salpingo-oophorectomy was done. After securing perfect hemostasis, abdomen was closed in layers. Two units of packed cells were transfused, one intraoperatively and the other postoperatively. Postoperative vitals were stable. Postoperative period was uneventful and she was discharged to home on the tenth postoperative day.

Histopathology report revealed simple ovarian cyst and tubal ectopic gestation.





#### DISCUSSION

Torsion of ovarian cyst and ruptured tubal ectopic pregnancy are gynaecologic surgical emergencies. This combination is extremely rare. This is the first known reported case of ruptured tubal ectopic pregnancy with ipsilateral torsion of ovarian cyst. The patient presents with lower abdominal pain and tenderness and peritoneal signs.

Ruptured ectopic pregnancy presents with abdominal pain, vaginal bleeding, and amenorrhea, dizziness or fainting and pain in the shoulder area due to haemoperitoneum. It is diagnosed from history, physical examination,  $\beta$ -hCG value and sonography.

Transvaginal ultrasound is the best to diagnose an ectopic pregnancy. The quantitative  $\beta$ -hCG levels  $<1500$  mIU/ml, combined with transvaginal ultrasound has been proposed in diagnosing ectopic pregnancy with 100% sensitivity and 99.9% specificity [6]. Treatment is salpingectomy if the fallopian tube only is affected or salpingo-oophorectomy if the ovary cannot be salvaged apart from the fallopian tube being affected.

Ovarian torsion presents with severe or dull aching unilateral lower abdominal pain, nausea, vomiting, lower abdominal tenderness on abdominal examination and adnexal tenderness or an adnexal mass on pelvic examination. Factors in favour of ovarian torsion are adnexal masses, enlargement of the corpus luteum cysts, pregnancy and ovarian hyperstimulation. In fact, 12% to 18% of ovarian torsion cases occur during pregnancy [7].

Doppler is highly specific in diagnosing ovarian torsion. All cases with absent or decreased Doppler flow had surgically confirmed ovarian torsion but normal flow by Doppler does not rule out ovarian torsion, and the diagnosis of ovarian torsion should be based on clinical suspicion [8]. On Doppler sonography - lack of intraovarian venous followed by intraovarian arterial blood flow, peripherally displaced ovarian follicles, enlarged hypoechoic or hyperechoic ovary, free pelvic fluid, Whirlpool sign of twisted vascular pedicle, slight deviation of the uterus towards the torqued ovary.

Previously, radical salpingo-oophorectomy, without prior detorsion has been performed due to concern about embolus migration from the twisted pedicle. No thromboembolic complication secondary to detorsion has been reported during recent times and Chapron et al. and Cohen et al. suggested that

conservative treatment is warranted to preserve fertility, even for adnexa that initially appear nonviable, and purple or black in coloration [9, 10]. Detorsion of the adnexa after the application of the clamps on the twisted pedicle, followed by ovarian cystectomy is the most effective treatment.

### CONCLUSION

There are several case series in the literature describing tubal ectopic pregnancies with contralateral adnexal torsion [11-14]. This is the first case of ruptured tubal ectopic pregnancy with ipsilateral torsion of ovarian cyst. These two gynaecologic surgical emergency conditions though rare, are to be diagnosed early to preserve future fertility and ovarian reserve in women of reproductive age group. It should be borne in mind that there is a possibility of ectopic pregnancy in a female who presents with pain abdomen and spotting or bleeding per vagina (as on day 1 of cycle as seen in this case) with no history of amenorrhoea.

### REFERENCES

- [1] Houry DE, Salhi BA. Acute complications of pregnancy. In: Marx JA (Ed). Rosen's Emergency Medicine: Concepts and Clinical Practice. 7th ed. Philadelphia, Pa: Mosby Elsevier; 2009: chap. 176.
- [2] Chang HC, Bhatt S, Dogra VC. Radiographic 2008; 28: 1355-1368.
- [3] Michele B, Giovanni S, Palo T, et al. Ultrasound Clin 2008; 3: 109-119.
- [4] Andrea JD, Donald BM, Claudio AB. Fertil Steril 2008; 90: e1-e3.
- [5] Hun-Shan P, Lee-Wen H, Chun-Yi L, et al. Arch Gynecol Obstet 2004; 270: 119-121.
- [6] Counselman FL, Shaar GS, Heller RA, et al. J Emerg Med 1988; 16: 699-703.
- [7] Chambers JT, Thiagarajah S, Kitchin JD. Obstet Gynecol 1979; 54: 487-490.
- [8] Lee EJ, Kwon HC, Joo HJ, Suh JH, Fleischer AC. J Ultrasound Med 1998; 17: 83-89.
- [9] Zweizig S, Perron J, Debra M, Daniel R. Am J Obstet Gynecol 1993; 168: 1791-1795.
- [10] Chapron C, Capella-Allouc S, Dubuisson JB. Hum Reprod 1996; 11: 998-1003.
- [11] Saito M, Koyama T, Yaoi Y, Kumasaka T, Yazawa K. Acta Obstet Gynecol Scand 1975;54:227-30.
- [12] Honore LH. J Reprod Med 1978;21:269-71.
- [13] Walters MD, Eddy C, Pauerstein CJ. Obstet Gynecol 1987;70:823-6.
- [14] Insunza A, de Pablo F, Croxatto HD, Letelier LM, Morante M, Croxatto HB. Acta Obstet Gynecol Scand 1988;67:433-6.