

# Research Journal of Pharmaceutical, Biological and Chemical Sciences

## Surgical Removal of an Odontome: A Case Report.

Prakash D, Vijay Ebenezer, Balakrishnan R, and Wasim Ahamed SG\*.

Department of Oral and Maxillofacial Surgery, Sree Balaji Dental College and Hospital, Chennai, Tamil Nadu, India.

### ABSTRACT

Odontomas are the most common odontogenic tumors. They are broadly classified in to Compound Odontoma and Complex Odontoma. Among them complex odontoma is a rare tumor. Occasionally this tumor becomes large, causing expansion of bone followed by facial asymmetry. Otherwise these tumors are asymptomatic and are generally diagnosed on radiographic examination. This is a case report of a male patient, 27 years old who visited the Department of Oral and Maxillofacial surgery, Sree Balaji Dental College and Hospital with a chief complaint of missing tooth in the left anterior region. A calcified mass was seen in the radiograph and was provisionally diagnosed as odontoma following which the odontoma was enucleated.

**Keywords:** Odontome, complex odontoma, compound odontoma, unerupted incisor, enucleation

*\*Corresponding author*

## INTRODUCTION

Odontoma belongs to a group of dentigerous tumors developing in jaw bones in stages of odontogenesis. The term “odontoma,” by definition alone, refers to any tumor of odontogenic origin. However, most authorities accept the view today that the odontoma represents a hamartomatous malformation rather than a neoplasm [1]. Odontomas are developmental anomalies resulting from the growth of completely differentiated epithelial and mesenchymal cells that give rise to functional ameloblast and odontoblast [2]. Odontomas have been classified as benign odontogenic tumours and are subdivided into complex or compound odontomas morphologically [3]. Compound odontomas commonly occur in the incisor-canine region of the maxilla and complex odontomas are frequently located in the premolar and molar region of both jaws [4].

Although the etiology of this malformation is not yet known, there is some evidence to show that there is a genetic basis for both complex and compound composite odontomas. Heredity is a possible factor and persistent lamina could be the hidden inherited developmental anomaly. Other theories have been proposed, including local trauma, infection, family history, and genetic mutation [5].

Odontomas generally appear as small, solitary or multiple radio-opaque lesions found on routine radiographic examination. Odontoma may cause disturbances in the eruption of teeth such as impaction, delayed eruption or retention of primary teeth [6]. There are very few reports of odontomas associated with primary teeth in the literature. In general, odontomas occur more often in the permanent dentition and are very rarely associated with the primary teeth [7,8].

### Case Report

A 27 year old male patient visited our Department of Oral and Maxillofacial surgery, Sree Balaji Dental College and Hospital with a chief complaint of missing left anterior teeth. On clinical examination a retained deciduous canine with missing permanent lateral incisor and canine was found. On radiographic examination, a 2x1cm irregular radiopaque mass (cotton wool-like appearance) occupied the left anterior maxilla region. The lateral incisor and canine were impacted.[Figure 1] A provisional diagnosis of Odontoma was made.

After all basic investigations, under local anaesthesia intraorally incision given[ Figure 2], flap raised[Figure 3], retained deciduous canine was extracted[Figure 4] and enucleation of the mass done[Figure 5,6,7]. Wound closure was done with 3-0 silk sutures. After two weeks, wound healed completely without any postoperative complications. Histopathologically, the decalcified section showed haphazard arrangement of dentin and cementum with numerous pulp spaces confirming the diagnosis as complex odontoma[Figure 8]. Patient is under follow-up on regular interval.

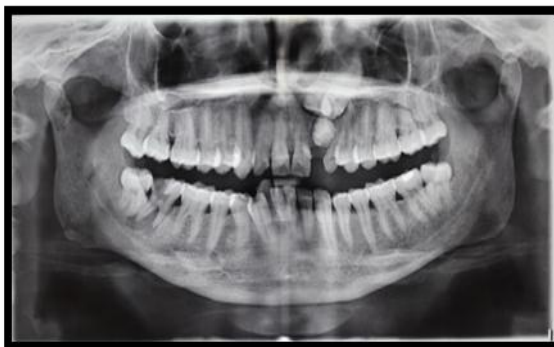

Figure 1

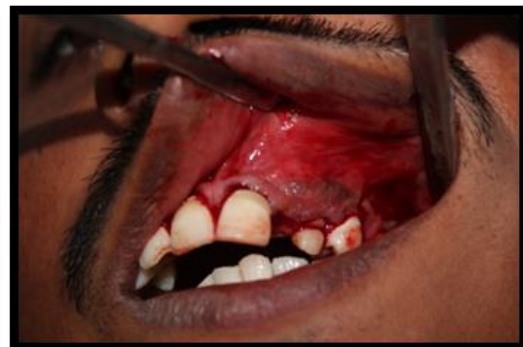

Figure 2

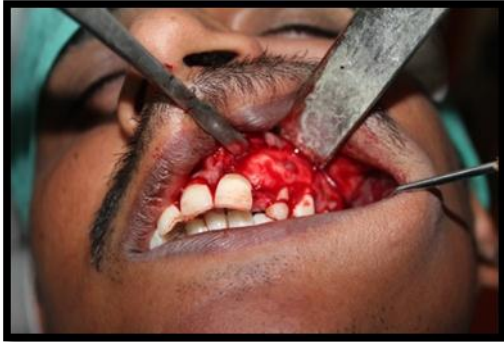

Figure 3

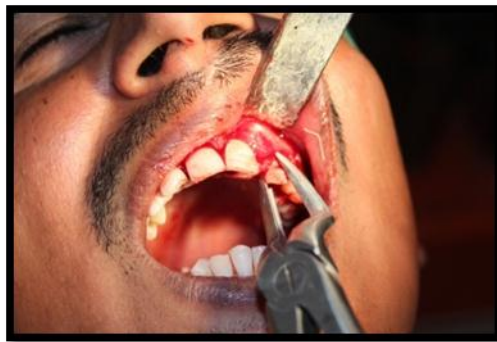

Figure 4

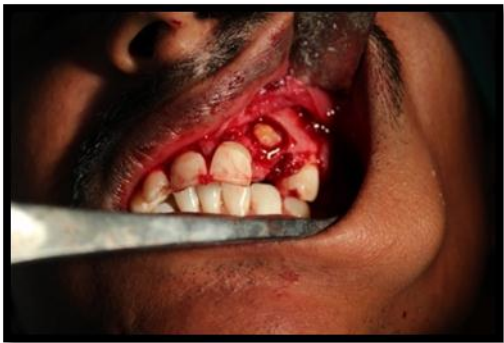

Figure 5

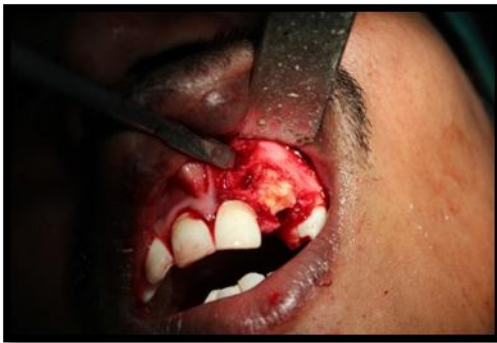

Figure 6

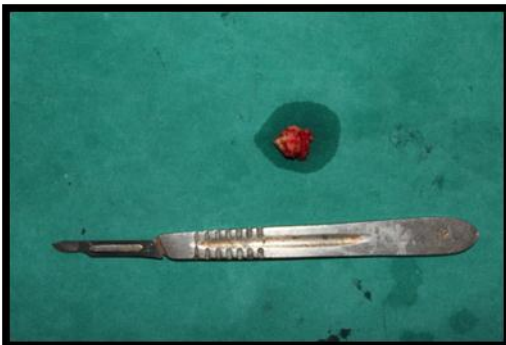

Figure 7

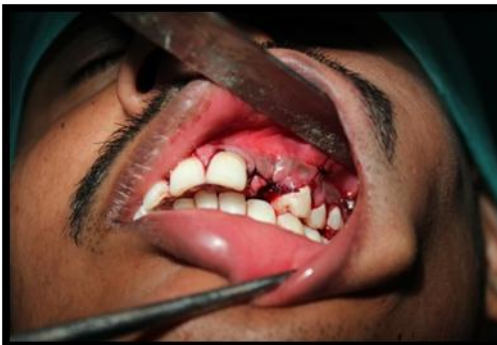

Figure 8

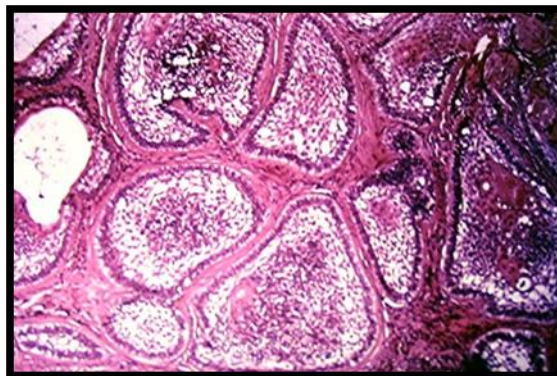


Figure 9

#### DISCUSSION

The term "odontoma," by definition alone, refers to any tumor of odontogenic origin. Through usage, however, it has come to mean a growth in which both the epithelial and the mesenchymal cells exhibit complete differentiation, with the result that functional ameloblasts and odontoblasts form enamel and

dentin. Paul Broca was the first person to use the term “odontoma” in 1867. He defined the term odontoma as “tumors formed by the overgrowth of transitory or complete dental tissues”[9].

The etiology of odontoma is not known but environmental causes such as infection, trauma, family history and genetic mutation are hypothesized [10]. The complex odontoma constitute 5-30% of all odontogenic tumors and are mostly found in the posterior mandible and anterior maxilla. They are seen with unerupted teeth in 10-44% and about 17% of them are associated with impacted maxillary lateral incisors. Females are affected marginally more than male (1.5:1). Majority of cases (84%) are seen below 30 years but are seen in any age group with peak incidence in second decade. Less than 10% are found in patients above 40 years of age [11,12].

H.M. Worth in 1937 classified odontomas as: a) Epithelial odontomas b) Composite odontomas [13]. Odontomas are also sub-classified as intraosseous and extraosseous odontomas [15,16].

Thoma and Goldman in 1946 gave a classification as: a) Geminated composite odontomas: nearly well-developed fused teeth. b) Compound composite odontomas: made up rudimentary teeth. c) Complex composite odontomas: calcified structures not resembling normal anatomical arrangement of dental tissues. d) Dilated odontomas: enlarged crown or root portion of tooth. e) Cystic odontomas: odontoma encapsulated by fibrous connective tissue in a cyst or in the wall of a cyst [14].

World Health Organization (WHO) classified odontomas into three groups: a) Complex odontoma; when the calcified dental tissues are simply arranged in an irregular mass bearing no morphological similarity to rudimentary teeth. b) Compound odontoma: composed of all odontogenic tissues in an orderly pattern, which result in many teeth-like structures, but without morphological resemblance to normal teeth. c) Ameloblastic fibro-odontome: consists of varying amounts of calcified dental tissue and dental papilla-like tissue, the later component resembling an ameloblastic fibroma. The ameloblastic fibro-odontome is considered as an immature precursor of complex odontoma. A new variant called as hybrid odontomas are quoted in few published literatures [17].

The odontoma presents as a well-defined radiopacity situated in bone, but with a density that is greater than bone and equal to or greater than that of a tooth. It contains foci of variable density. A radiolucent halo, typically surrounded by a thin sclerotic line, surrounds the radiopacity. The radiolucent zone is the connective tissue capsule of a normal tooth follicle. The thin sclerotic line resembles the corticated border seen in a normal tooth crypt. The developmental stages can be identified based on radiologic features and the degree of calcification of the lesion at the time of diagnosis [18-20]

Retention of deciduous teeth, unerupted permanent teeth, cortical expansion and teeth displacement are all indicators for a possible odontomas [5]. They are symptomatic with expansion, local and/or radiating pain and neurosensory deficit when secondarily infected [21]. Developing lesions show histological features of all stages in odontogenesis and may be difficult to differentiate from ameloblastic fibroma and ameloblastic fibro-odontoma [22].

Association of this lesion with the unerupted tooth is high and three quarters of impacted teeth related to odontomas can erupt after removal of the odontoma[23]. Looking at the association of these lesions and the potential complications associated with the cyst, odontomas should be properly evaluated and removed completely in case of any suspicion of cystic transformation [24]. In cases where smaller segments are left behind, they do not tend to grow or get infected postoperatively [25].

Removal of the odontome in the primary operation led to the eruption of the impacted tooth in 45% of cases, with a second surgical and/or orthodontic intervention giving better results. The morphology of the tooth, its location and position in the jaw and the available space in the dental arch should be examined radiographically, which will determine the treatment [23].

## CONCLUSION

Odontomas are common benign odontogenic pathologies that are accidentally discovered on routine radiography when asymptomatic. But can be a cause of concern when they grow to attain unusual dimensions,

displacing and preventing eruption of teeth, cystic transformation. When they occur in the maxilla with sinuses present can go unnoticed till they attain bigger size leading to functional problems. A routine periodic check-up along with conventional radiographs should be mandatory for early detection of benign asymptomatic bone tumors and treat to avoid future complications.

#### REFERENCES

- [1] King N, Wu I. *Dent Asia* 2002;18–23.
- [2] Shafer WG, Hine MK, Levy BM. *A textbook of oral pathology*. 4. Philadelphia: WB. Saunders Company; 1983; p. 308.
- [3] Kramar IRH, Pindborg JJ, Shear M. *World health organization international histological classification of tumours histological typing of odontogenic tumours*. Berlin Heidelberg: Springer-Verlag; 1992;p. 11.
- [4] Stajcic ZZ. *J Pedod* 1988;12:415–420. [PubMed]
- [5] Reichart PA, Philipsen HP. *Odontogenic tumours and allied lesions*. Chicago: Quintessence Pub. Co. Ltd;. Complex odontoma; 2004;pp. 141–9.
- [6] Snawder KD. *ASDC J Dent Child* 1974;41:382–384.
- [7] de Oliveira BH, Campos V, Marcal S. *Pediatr Dent* 2001;23:151–157.
- [8] Noonan RG. *Oral Surg Oral Med Oral Pathol* 1971;32:740–742.
- [9] Gurdal P, Sectin T. *Quintessence Int* 2001;32:336–7.
- [10] Mupparapu M, Singer SR, Rinaggio J. *Quintessence Int (Berl)* 2004;35:641–5.
- [11] Vengal M, Arora H, Ghosh S, Pai KM. *J Can Dent Assoc* 2007;73:169–73.
- [12] Chang JY, Wang YP, Liu BY, Sun A, Chiang CP. *J Formos Med Assoc* 2003;102:876–82.
- [13] Worth HM. *Br J Radiol* 1937;10:223–36.
- [14] Thoma KH, Goldman HM. *Am J Pathol* 1946;22:433–71.
- [15] Das UM, Nagarathna, Arathi. *J Indian Soc Pedod Prev Dent* 2002;20:98–101.
- [16] Singh S, Singh M, Singh I, Khandelwal D. *J Indian Soc Pedod Prev Dent* 2005;23:146–50.
- [17] Phillips MD, Closmann JJ, Baus MR, Torske KR, Williams SB. *J Oral Maxillofac Surg* 2010;68:470–4.
- [18] Junquera L, de Vincente JC, Roig P, Olay S, Rodriguez-Recio O. *Med Oral Patol Oral Cir Bucal* 2005; 10(3):248–51.
- [19] Wood NK, Goaz PW, Lehnert J. Mixed radiolucent–radiopaque lesions associated with teeth. In: Wood NK, Goaz PW, editors. *Differential diagnosis of oral and maxillofacial lesions*. Singapore: Harcourt Brace & Company Asia Pte Ltd; 1998. p. 289–314.
- [20] Guinta JL, Kaplan MA. *Oral Surg Oral Med Oral Pathol* 1990; 69(3):406–11.
- [21] Tüzüm MS. *Aust Dent J* 1990;35:352–4.
- [22] Soames JV, Southam JC. *Oral Pathology*. 4th ed. Oxford: Oxford University Press; 2005. *Odontomes and Odontogenic Tumours*; pp. 221–38.
- [23] Morning P. *Int J Oral Surg* 1980;9:81–91.
- [24] Wanjari SP, Tekade SA, Parwani RN, Managutti SA. *Contemp Clin Dent*. 2011;2:215–7.
- [25] Marx RE, Stern D. *Oral and maxillofacial pathology*. Quintessence: *Odontogenic tumors* 2003;pp. 678–9.