

Research Journal of Pharmaceutical, Biological and Chemical Sciences

A Rare Case of Impacted Huge Cervical Fibroid Delivered Using a Blade of Obstetric Outlet Forceps.

SK Geetha*, K Saraswathi, and S Nirupa.

Department of Obstetrics and Gynaecology, Sree Balaji Medical College and Hospital, Chrompet, Chennai – 14, Tamil Nadu, India.

ABSTRACT

Most of the fibroids are situated in the body of the uterus, but in 1 – 2% of the cases they are confined to cervix and usually to be supravaginal portion. A cervical fibroid is usually single and is either interstitial or subserous. Rarely it becomes submucous and polypoidal. Treatment for cervical fibroid is hysterectomy. The principle to be followed is enucleation followed by hysterectomy. Difficulties may be encountered during enucleation of cervical fibroid. Here is such a case in which enucleation by hand and myoma screw turned out to be difficult in which a blade of outlet forceps was used for successful enucleation.

Keywords: Cervical fibroid, Ureteric Stenting, Enucleation, Outlet forceps.

**Corresponding author*

INTRODUCTION

Fibroids arising from cervix are rare with incidence of 2% [1-3]. A central cervical fibroid is usually interstitial or submucous in origin and arises from supravaginal portion of cervix [1]. As it expands equally in all directions it displaces uterine arteries, ureters and distorts the bladder in front compresses the rectum behind. On laparotomy it can be seen as a huge mass impacted in pelvis with uterus sitting on top of it like the typical description 'LANTERN ON THE DOME OF St. PAUL'S CHURCH' [1]. The operation for removal of cervical fibroid is hysterectomy, but it can be difficult, and may at times be an extremely formidable undertaking [4]. Mostly they are dealt with hysterectomy. The principle to be followed is Enucleation followed by hysterectomy. If the fibroid is huge and soft due to degenerative changes difficulties may be encountered in enucleation. Large cervical fibroids are difficult to handle and need an expert hand to operate these cases.

MATERIALS AND METHODS

A 46 year old multiparous lady (previous 2 LSCS) came to our gynaecology OPD with complaints of difficulty in passing urine, urinary retention and lower abdominal pain for the past one month. She gives history of passing small quantities of urine on and off with retention of urine. She had regular cycles in the past with moderate flow lasting for 3 days. She was married for 19 years, underwent 2 LSCS and was sterilized. She was apparently normal in the past. Her parents were diabetics and hypertensives on treatment.

On examination, a firm mass was felt in the suprapubic region upto 14 weeks size, firm in consistency, mobile and non tender. Cervix could not be visualized on speculum examination. A mass was seen occupying the pelvis. Vaginal examination revealed a ballooned out cervix with a mass which occupies the whole of pelvis. Uterus was felt upto 14 weeks size along with the mass in the pelvis. On per-rectal examination, the same mass was felt but was not pressing on the rectum.

Ultrasonogram Abdomen & Pelvis showed a bulky uterus with endometrial thickness of 5mm. A huge fibroid of size 12.1 x 10 cm intramural in origin from the cervix. Right ovary was not imaged. Left ovary normal. Both kidneys were normal in size with normal echoes and collecting system. Impression – Cervical fibroid.

Investigations were done, all were normal except increased TSH value and the patient was started on tablet Thyroxine as per physician's advice. Patient was taken up for surgery (TAH with BSO) under epidural – spinal anesthesia. Urologist was informed beforehand for ureteric stenting. Cystoscopy was done by urologist. Trigone was found distorted. Right ureteric stenting was done. Stenting of left ureter was done with difficulty due to distorted anatomy. Abdomen was opened by midline vertical incision, uterus was bulky and was seen sitting on a huge cervical fibroid of size 12 x 9 cm exactly like the description 'Lantern On The Dome Of St. Paul's Church' (Fig.1). Both ovaries and tubes were normal.

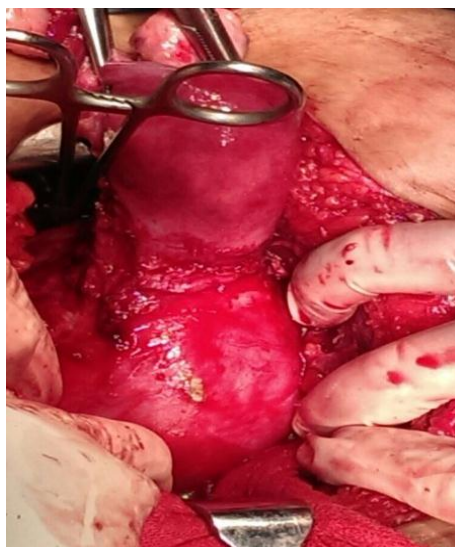

Figure 1

After clamping, cutting and ligating the round ligament, infundibulopelvic ligaments, bladder was found to be densely adherent to uterus and was dissected down by sharp dissection. Anteriorly over the fibroid, a vertical incision was made on the capsule and the fibroid was separated all around by working within the capsule. Enucleation was tried with hand. Since the fibroid was huge, delivering it out with hand was difficult. Then enucleation was tried with myoma screw. Due to degenerative changes in the fibroid, enucleation with myoma screw turned futile. Then a single blade of Wrigley's outlet forceps was brought and was used as a vectis to lever out the fibroid from its bed (Fig.2). Fibroid was easily lifted out with the blade of outlet forceps without injuring the adjacent structures as it was done within the capsule (Fig.3). The fibroid weighed around 500g. Rest of the procedure was completed in the usual way. 1 pint of blood was transfused post operatively. Urinary catheter was kept for 1 week and removed. Sutures were removed on 8th Post Operative Day and wound was healthy. The HPE report came as Leiomyoma with Hyaline degeneration.

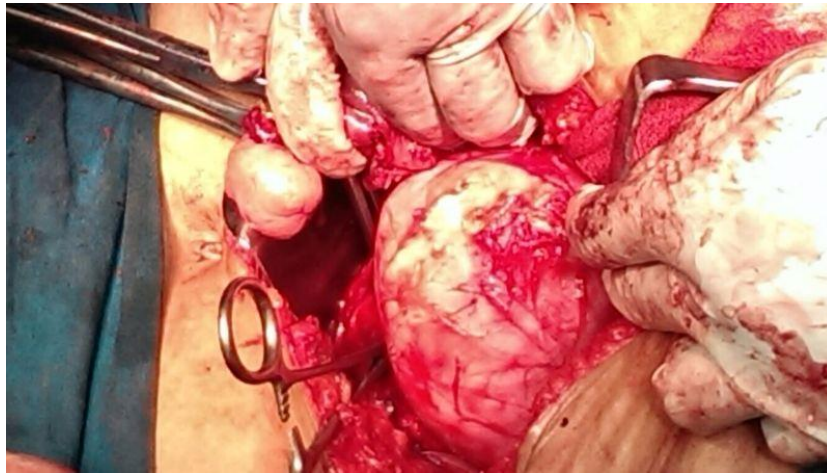


Figure 2

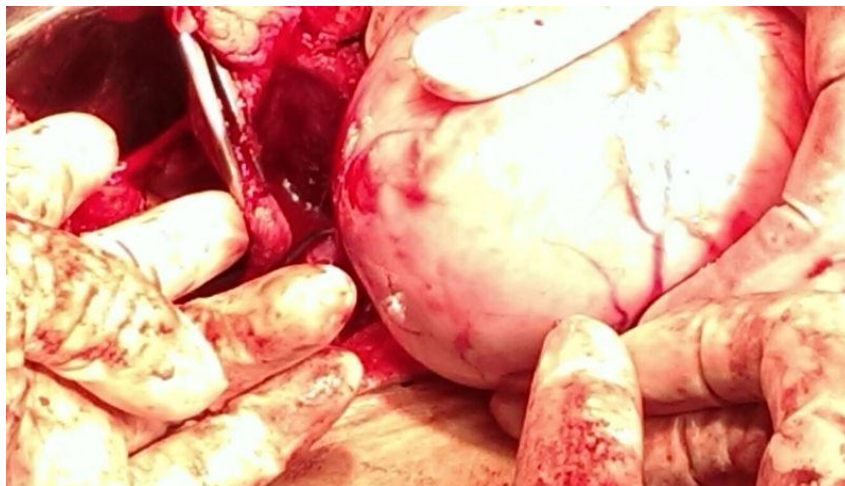

Figure 3

DISCUSSION

Cervical fibroids can arise in the supravaginal or vaginal portion of the cervix. There are several types of fibroids and each can present differently.

- 1) Anterior cervical fibroid may compress on bladder causing increased frequency or retention of urine.
- 2) Posterior cervical fibroid may compress on rectum producing constipation.
- 3) Central cervical fibroid causes bladder symptoms and displace the ureters superiorly.

- 4) Lateral cervical fibroid may compress on the vessels of lower limb causing edema.

Cervical myomas may become pedunculated and protrude through the external os. Cervical myoma can be removed by various methods like Total Abdominal Hysterectomy with enucleation of cervical myoma, laproscopic myomectomy and morcellation, vaginal myomectomy if it protrudes through os. Treatment in young females is Myomectomy but the anatomic and functional restoration of cervix is difficult to achieve a future reproduction.

Huge cervical myomas can compress on adjacent structures Since, the ureters and uterine vessels are displaced superiorly there is every chance of injury to bladder, ureter and uterine vessels. Intracapsular enucleation of Fibroid is the best approach to prevent injury to bladder and ureter⁴. So we did preoperative ureteric stenting to prevent injury to ureters during surgery. Since myomectomy was done by working within the capsule of cervical fibroid, injury to the adjacent structures like bladder, ureter, uterine vessels were avoided. Usually after separating the fibroid from its capsule it is removed by hand or myoma screw. In our case, since cervical fibroid was huge and weighed around 500g, it could not be removed by hand. Due to degenerative changes, the fibroid was soft and could not be removed by myoma screw. So we used the single blade of Wrigley's obstetric outlet forceps to lever out the fibroid from its bed without injuring adjacent structures.

CONCLUSION

In spite of the fibroid being huge, vascular and deeply impacted in the pelvis, the whole myoma was enucleated by working within the capsule. Since an obstetric tool (a blade of Wrigley's forceps) was used as an instrument in gynaecological surgery and preoperative ureteric stenting was done as a precautionary step, we wanted to highlight on these aspects. The patient got discharged without any complications. Thus, we conclude that pre operative ureteric stenting should be done as a routine in dealing with cervical myomas and huge myomas can be levered out by working within the capsule by using hand, myoma screw or a blade of outlet forceps too.

REFERENCES

- [1] Kavitha et al. – a rare case of central cervical fibroid with characteristic “ Lantern on top of St.Paul “ appearance. – IJRDH.
- [2] Tiltman, Andrew J. Int J Gynecolog Pathol 1998; 17(3):p231-4.
- [3] Kaur AP, Saini AS, Kaur D, Madhulika, Dhillon SPS. The J ObstetrGynaecol India 2002;52 (1):p164
- [4] Monaghan JM, Lopes AB, Naik R. Total hysterectomy for cervical and broad ligament fibroids. In: Huxley R, Taylor S, Chandler K, editors. Bonney's gynaecological surgery 10th ed. Blackwell Publishing; 2004. p.74-86.