

Research Journal of Pharmaceutical, Biological and Chemical Sciences

Cadaveric Study on Anatomical Variations in Lumbosacral Trunk Thickness

Hareesh R¹, Jayagandhi S^{2*}, and Rema Devi³.

¹Final Year Under Graduate Medical Student, Pondicherry Institute of Medical Sciences, Puducherry, India.

²Associate Professor, Department of Anatomy, Pondicherry Institute of Medical Sciences, Puducherry, India.

³Professor and HOD, Department of Anatomy, Pondicherry Institute of Medical Sciences, Puducherry, India.

ABSTRACT

The lumbosacral trunk is a thick nervous band formed by the anterior rami of the L4 and L5 spinal nerves. It descends over the sacral ala and merges with sacral spinal nerves to form the sacral plexus, serving as a vital connection between the lumbar and sacral plexuses. The Lumbosacral trunk provides motor and sensory innervation to the gluteal region, posterior thigh, leg, and foot through its branches, including the sciatic nerve, superior and inferior gluteal nerves, and nerves to the obturator internus and quadratus femoris muscles. This study aimed to explore variations in the thickness of the Lumbosacral trunk, which are clinically significant for diagnosing radiculopathy and optimizing lumbar plexus block techniques. Measurements were taken from 12 cadavers using a Vernier caliper at the sacral promontory. The mean thickness was 9.4 mm (SD \pm 2.02) on the right and 9.2 mm (SD \pm 1.6) on the left, with an absolute mean difference of 1.7 mm (SD \pm 1.8). One cadaver exhibited notable asymmetry, where L4 and L5 solely contributed to the trunk. Variations in thickness are linked to plexopathies, such as amyotrophy and hereditary pressure-sensitive neuropathy. Lesions of the Lumbosacral trunk, although rare, mimic L5 radiculopathy and are associated with pelvic trauma or retroperitoneal pathologies. Understanding these anatomical variations is essential for accurate diagnoses and effective anesthetic interventions.

Keywords: Lumbar plexus, Lumbosacral trunk, Plexus, Sensory innervation.

<https://doi.org/10.33887/rjpbcs/2025.16.1.15>

**Corresponding author*

INTRODUCTION

The lumbosacral trunk is a crucial anatomical structure formed by the anterior rami of the L4 and L5 spinal nerves. It descends obliquely across the sacral ala and merges with the sacral spinal nerves to contribute to the formation of the sacral plexus. This connection serves as a vital link between the lumbar and sacral plexuses, which collectively provide motor and sensory innervation to the gluteal region, posterior thigh, and distal parts of the lower limb. The Lumbosacral trunk gives rise to several important nerves, including the sciatic nerve, superior and inferior gluteal nerves, and branches innervating the quadratus femoris, obturator internus, inferior and superior gemellus [1].

Variations in the thickness and formation of the Lumbosacral trunk (LST) have been observed in cadaveric studies, highlighting the dynamic nature of its anatomy. While in most cases L4 and L5 contribute equally to the trunk, deviations such as thinner or thicker contributions from either nerve, or even contributions from other nerves like L3, have been documented. These anatomical variations can have significant clinical implications, particularly in surgical and diagnostic settings. Variations in LST thickness, for example, can influence the manifestation of plexopathies, which often mimic L5 radiculopathy. Conditions like amyotrophy and hereditary pressure-sensitive neuropathy are frequently associated with thinner Lumbosacral trunks, emphasizing the importance of understanding its anatomical variability.

The relationship of the LST to surrounding structures, such as the sacroiliac joint, is also critical in clinical practice. Studies have shown that lesions to the LST are relatively rare but can occur during childbirth (especially in cases of disproportionate fetal and pelvic size), pelvic fractures, retroperitoneal masses, or hematomas. These injuries often result in sensory deficits along the L5 dermatome and are challenging to distinguish clinically from L5 radiculopathy, necessitating electrodiagnostic studies for accurate diagnosis [2].

In the context of anesthesia, precise knowledge of the Lumbosacral trunk's anatomy is essential for performing lumbar plexus blocks and achieving effective perioperative analgesia in lower limb surgeries. As such, studying the Lumbosacral trunk's varying dimensions and anatomical nuances is of paramount importance for both clinicians and anatomists.

Aims And Objectives

To study the thickness of the Lumbosacral trunk on both sides in cadavers

MATERIALS AND METHODS

This Observational study was carried out with 12 cadaveric lumbosacral trunks (12 Right & 12 Left sides). The Cadavers with intact lumbar and sacral regions and Cadavers free from any pathological or surgical modifications in the pelvic region were included for the study. The lumbar and sacral regions of the cadavers were carefully dissected to expose the LST. Skin, subcutaneous tissues, and muscles were removed to access the nerves. Care was taken to preserve the continuity of the nerve roots and branches. The Lumbosacral trunk was identified at the level of the sacral promontory where it descends over the ala of the sacrum [Figure 1,2]. Measurements of the Lumbosacral trunk were taken bilaterally using inch tape. The thickness of the Lumbosacral trunk was recorded at its widest point for both sides in each cadaver [2,3]. The thickness of the Lumbosacral trunk was measured in millimeter (mm) for both the right and left sides of each cadaver. Observations of any anatomical variations, such as asymmetry in thickness or contributions from additional spinal roots, were documented [Figure 4].

Figure 1: The location of lumbosacral trunk shown in yellow color

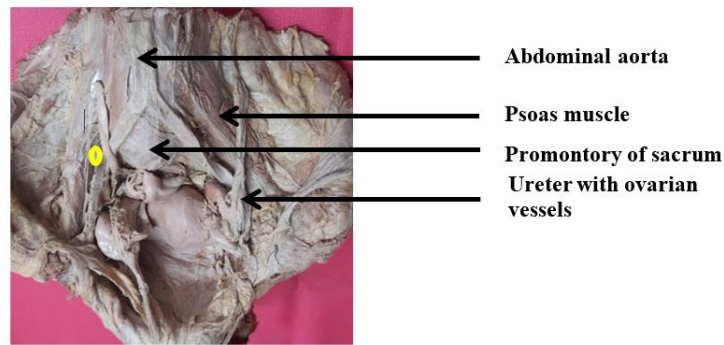


Figure 2: The right and left lumbosacral trunk in yellow color

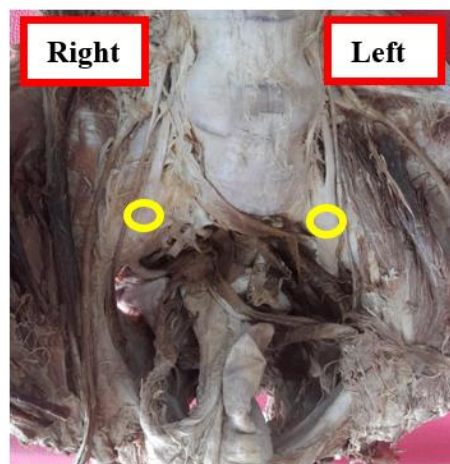



Figure 3: Measurement of lumbosacral trunk



Statistical analysis

The mean and standard deviation (SD) for the thickness of the Lumbosacral trunk were calculated separately for the right and left sides. The absolute difference in thickness between the two sides (R-L) was computed for each cadaver. Observed variations in the thickness and composition of the Lumbosacral trunk were analyzed qualitatively and compared with available literature.

RESULTS AND OBSERVATION

To enhance the study where the differences in measurements of the right and left lumbosacral trunk are plotted in a linear graph [Figure 4]

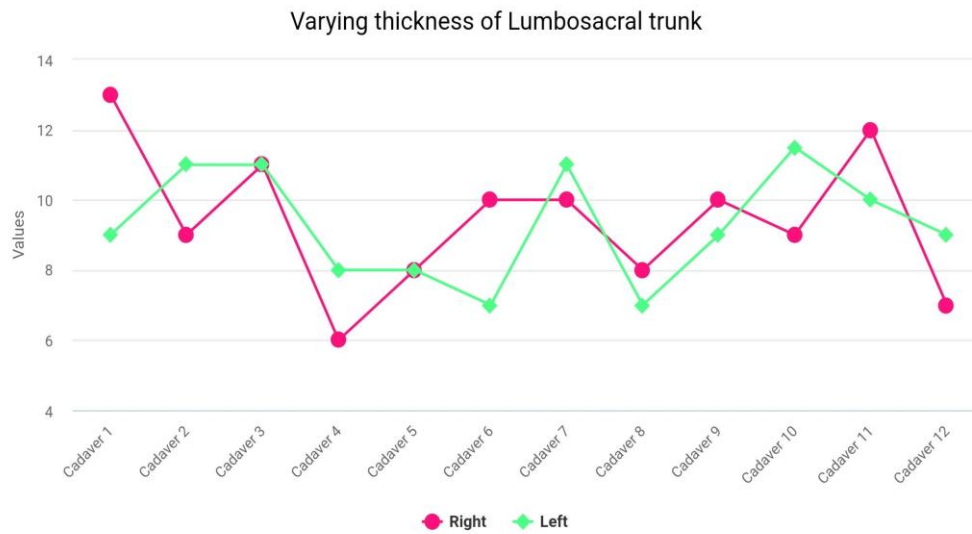


Figure 4: Graph showing varying thickness of lumbosacral trunk.

Table 1: Mean and Standard deviations between the right and left lumbosacral trunk.

| Side | Mean ± Standard Deviation(mm) |
|------------------|-------------------------------|
| Right | 9.4±2.0 |
| Left | 9.2±1.6 |
| Difference (R-L) | 1.7±1.8 |

DISCUSSION

The lumbosacral trunk is an important structure formed by the union of the L4 and L5 spinal nerves. It plays a vital role in forming the sacral plexus, which innervates the lower extremity, providing branches that supply the motor and sensory innervation for the skin and muscles of the gluteal region, thigh, leg and foot.

Variations in its thickness and anatomical course can have significant clinical implications, particularly in surgical procedures and while providing regional anesthesia involving the pelvis and lower limbs.

The study by V. Matejcik (2010) examined 100 lumbosacral plexi from 50 cadavers to investigate neural variations, focusing on root ascension, anastomoses, and branching patterns. The findings revealed significant variability, including the involvement of the 12, L4, and L5 roots. Notable variations included differences in root thickness (L1 being the thinnest, L4 the thickest), double ascension of L4, L3, and L5 roots, and anomalies in the sacral plexus, such as double ascension of S1 and S2 roots. The study also observed thickening of the lumbosacral trunk in some cases [3].

A study by Aydın et al. (2009) examined the anatomical variations of the lumbosacral plexus, highlighting that the L4 root is the thickest, while L1 is the thinnest. This variability in root thickness plays a role in the overall functionality and susceptibility to injury in clinical practice. Variations in the lumbosacral trunk’s morphology have also been documented in cases of congenital anomalies, where the

trunk may be absent, or the L4 and L5 roots may unite at different levels (Yazicioglu et al., 2018). Such deviations can lead to differences in the branching patterns of the plexus and may influence surgical strategies in nerve decompression or repair [4, 5].

In a study by Berrios et al. (2018), the course and thickness of the lumbosacral trunk were explored, showing that the diameter of the trunk and its roots increased from L1 to S1, with significant variation in thickness based on factors such as age and pathology [6].

Another detailed anatomical review by Zhang et al. (2020) emphasized the variability in the lumbosacral trunk's path, noting that these variations could affect surgical outcomes, especially in cases involving nerve grafting and spinal interventions. The study also described the terminal branches of the lumbosacral trunk, which can have altered anatomical relationships in individuals with anomalies [7].

Studies like those by Yousef et al. (2021) and Sharma et al. (2017) have reported that certain individuals exhibit considerable variations in the emergence and branching of the lumbosacral trunk, which can complicate clinical diagnoses and procedures such as spinal anesthesia and nerve block interventions [8,9].

Brull et al. (2006) discussed the relevance of understanding the lumbosacral trunk's anatomy in regional anesthesia for the lower extremities. They noted that variations in the lumbosacral trunk could affect the distribution of anesthetic agents during nerve blocks, necessitating modifications in anesthetic approaches to achieve effective regional anesthesia [10].

Suresh et al. (2014) examined the clinical implications of anatomical variations in the lumbosacral trunk, highlighting that such deviations could result in incomplete anesthesia or unintended nerve damage if not properly addressed. They recommended that anesthesiologists consider these anatomical differences when performing lumbar or sacral plexus blocks, especially for surgeries involving the lower extremities [11].

Durrani et al. (2019) emphasized the significance of recognizing lumbosacral trunk variations in regional anesthesia practice. They indicated that anatomical anomalies could impact the success of lumbar plexus and sacral plexus blocks, suggesting the need for additional imaging techniques or individualized anesthesia plans to ensure optimal outcomes [12].

Nastoulis et al. (2019) conducted a systematic review focusing on the anatomical variations of the sacrum and their clinical implications. The study highlighted that variations such as differences in the number and morphology of sacral foramina, sacral hiatus, and overall sacral structure can significantly impact clinical procedures, including regional anesthesia techniques. These anatomical differences may alter the expected pathways for needle insertion or the spread of anesthetic agents, potentially leading to complications or reduced efficacy of anesthesia [13].

Lumbosacral radiculopathy is a condition characterized by pain resulting from the compression or irritation of nerve roots in the lumbosacral region of the spine. This compression often stems from degenerative changes such as disc herniation, ligamentum flavum alterations, facet hypertrophy, and spondylolisthesis, leading to the compression of one or more lumbosacral nerve roots. Symptoms typically include low back pain radiating into the lower extremities in a dermatomal pattern corresponding to the affected nerve root. Additional symptoms may include numbness, weakness, and loss of reflexes, although the absence of these symptoms does not exclude the diagnosis of lumbosacral radiculopathy.

Understanding the precise anatomy of the lumbosacral trunk is crucial in clinical practice, particularly in the context of regional anesthesia and surgical interventions involving the lower back and pelvis. Variations or injuries to this structure can have significant implications for motor and sensory functions in the lower extremities. Plexopathies of lumbosacral trunks may be associated with nerve plexus which are thinner in width. Amyotrophy and hereditary pressure sensitive neuropathy lesions may also be associated with differences in the thickness of lumbosacral plexus. Lesions to the lumbosacral trunk component of the lumbosacral plexus are relatively rare. They occur mostly during labor (particularly by short women delivering large babies); after pelvic fractures; and with retroperitoneal hematomas, abscesses, and mass lesions. Sensory loss is in an L5 dermatomal

distribution. Lumbosacral trunk lesion clinically imitates an L5 radiculopathy, and careful electrodiagnostic studies are often essential for final diagnosis [14].

Magnetic resonance imaging (MRI) was used in a 2023 study to evaluate potential causes of lower back pain. The L5 root thickness was measured at 5.2 ± 0.57 mm on the right side and 5.25 ± 0.88 mm on the left side. Similarly, the L5 nerve root itself measured 5.32 ± 0.54 mm on the right side and 5.32 ± 0.38 mm on the left side, with the root thickness being 5.32 ± 0.45 mm. [15].

There are limited studies available on the measurement of lumbosacral trunk thickness, despite its significance in addressing back pain issues. Our study focused on measuring the thickness of the lumbosacral trunk in cadaveric specimens [Figure 1 - 4 and table], which was found to be 9.4 ± 2.0 mm on the right side and 9.2 ± 1.6 mm on the left side, with a difference of 1.7 ± 1.8 mm between the two sides. These findings may assist in pedicle screw placement and lumbar decompression surgery.

CONCLUSION

Knowledge about the varying dimensions of the lumbosacral trunk is crucial for accurately diagnosing a range of symptoms and signs associated with spinal root radiculopathy. Variations in the thickness of the lumbosacral trunk can have a direct impact on the clinical presentation of radicular pain, motor dysfunction, and sensory disturbances in the lower limbs. Additionally, this knowledge plays a vital role in the effective administration of lumbar plexus blocks, which are commonly used for perioperative analgesia and surgical anesthesia during lower limb surgeries. By recognizing the anatomical diversity of the lumbosacral trunk, it helps in the precision of nerve block procedures, enhancing their success rates. This understanding is essential for providing optimal patient care, ensuring both accurate diagnosis and effective management of pain during surgical interventions involving the lower extremities.

ACKNOWLEDGEMENTS

Dr. Renu G' Boy Varghese Director – Principal, Dr. Anil J Purty, Mr. Iyappan, and Department of Anatomy, Pondicherry institute of medical sciences.

REFERENCES

- [1] Standing S. Gray's anatomy 40th Edition. The Anatomical Basis of Clinical Practice, Churchill Livingstone: Elsevier, London 2008; 1384.
- [2] Abdallah FW, Chan VW. Proximal sciatic nerve block ultrasound guided In. Regional Nerve Blocks in Anesthesia and Pain Therapy 2015:801-809.
- [3] Matejcik V. Anatomical variations of the lumbosacral plexus. Surg Radiol Anat 2010;32(4):409-414.
- [4] Aydın N, Kocaoğlu H, Aydın C, et al. Anatomical variations of lumbosacral plexus. Clin Anat 2009;22(3):332-340.
- [5] Yazicioglu D, Gurunluoglu R, Karaoglanoglu M, et al. Absence of the lumbosacral trunk: case report and review of the literature. Anat Sci Int 2018;93(4):423-426.
- [6] Berrios R, Kumar R, Ling J, et al. Human lumbosacral root and ligamentum flavum thicknesses. Folia Morphol (Warsz) 2018;77(2):320-324.
- [7] Zhang L, Chen G, Wu X, et al. Lumbosacral trunk: origin, variations and clinical relevance. Neurosurgery 2020;87(3):515-522.
- [8] Yousef S, Rashad M, Elmazny A, et al. The lumbosacral trunk: anatomical variations and implications for spinal surgery. J Neurosurg Spine 2021;35(4):487-493.
- [9] Sharma H, Kumar M, Thakur S, et al. Anatomical variations of lumbosacral plexus and its clinical significance. Anat Physiol 2017;12(6):735-738.
- [10] Brull R, McCartney CJL, Chan VWS. The lumbar plexus and regional anesthesia of the lower extremity. Can J Anesth 2006;53(4):351-358.
- [11] Suresh S, Akhavan A, McCulloch W. Anatomical variations and clinical implications of the lumbosacral trunk in regional anesthesia. Anesth Analg 2014;119(5):999-1004.
- [12] Durrani F, Hassan H, Sherwani R, et al. Lumbosacral trunk variations and implications for anesthetic techniques. J Clin Anesth 2019; 56:58-65.
- [13] Nastoulis E, Karakasi M-V, Pavlidis P, Thomaidis V, Fiska A. Anatomy and clinical significance of sacral variations: a systematic review. Folia Morphol 2019;78(4):651-667.



- [14] Alexander CE, Weisbrod LJ, Varacallo M. Lumbosacral Radiculopathy. Treasure Island (FL): StatPearls Publishing; 2024; 27.
- [15] Khasawneh R, El-Rub EA, Allouh M. Human lumbosacral root and ligamentum flavum thicknesses: a magnetic resonance study *Folia Morphol* 2021;82 (1): 72–78.