

# Research Journal of Pharmaceutical, Biological and Chemical Sciences

## Functional And Radiological Outcome Analysis Of Clavicle Fractures Treated By Superior And Anterior Plating: A Retrospective And Prospective Study.

Senthil Sailesh<sup>1</sup>, Sivakumar Perumal<sup>2\*</sup>, and Ragavanandam Ramalingam<sup>3</sup>.

<sup>1</sup>Associate Professor, Department Of Orthopedics, Government Villupuram Medical College And Hospital, Villupuram, Tamil Nadu, India.

<sup>2</sup>Assistant Professor, Department Of Orthopedics, Government Dharmapuri Medical College And Hospital, Dharmapuri, Tamil Nadu, India.

<sup>3</sup>Senior Assistant Professor, Department Of Orthopedics, Govt Stanley Medical College And Hospital, Chennai, Tamil Nadu, India.

### ABSTRACT

Clavicle fractures are accounts for 2.6% of all fractures. There are lot of evidences shows that conservative management have higher rate of nonunion and decreased shoulder functions. Many studies show, using 3.5 mm Locking dynamic compression plates will improve functional outcome and union but it may cause implant related complications. Recent studies show using low profile reconstruction plates will give good functional outcome, higher union rate and low implant related complications. So, the aim of our study is to determine the functional and radiological outcome of superior and anterior plating of clavicle fractures and its complications. We have done a retrospective and prospective study in Department Of Orthopedics, Department Of Orthopedics, Government Dharmapuri Medical College And Hospital, Dharmapuri, Tamil Nadu, India. In the year 2023. Totally we have included 30 patients based on inclusion and exclusion criteria. We did open reduction and internal fixation with superior and anterior plating for clavicle and followed standard post operative protocol. Functional outcome analyzed using DASH score and radiological outcome analyzed using RUS for clavicle during follow up. In our study, we achieved mean postoperative DASH score of 4.2. The mean RUS score in our study was 12. In our study 3.3% patients have implant prominence. None of the patients undergone implant removal until union. Dual plating using lower profile plates can be chosen as the surgeon's choice for treating clavicle fracture as it provides multiplanar stability, excellent union rate and functional outcome. Dual plating also helps to maintain reduction even in complex fracture patterns. Dual plating does not show any symptomatic implant removal in our study. There is no evidence of wound related complications in our study.

**Keywords:** Clavicle, RUS, DASH, Dual plating.

<https://doi.org/10.33887/rjpbcs/2024.15.3.36>

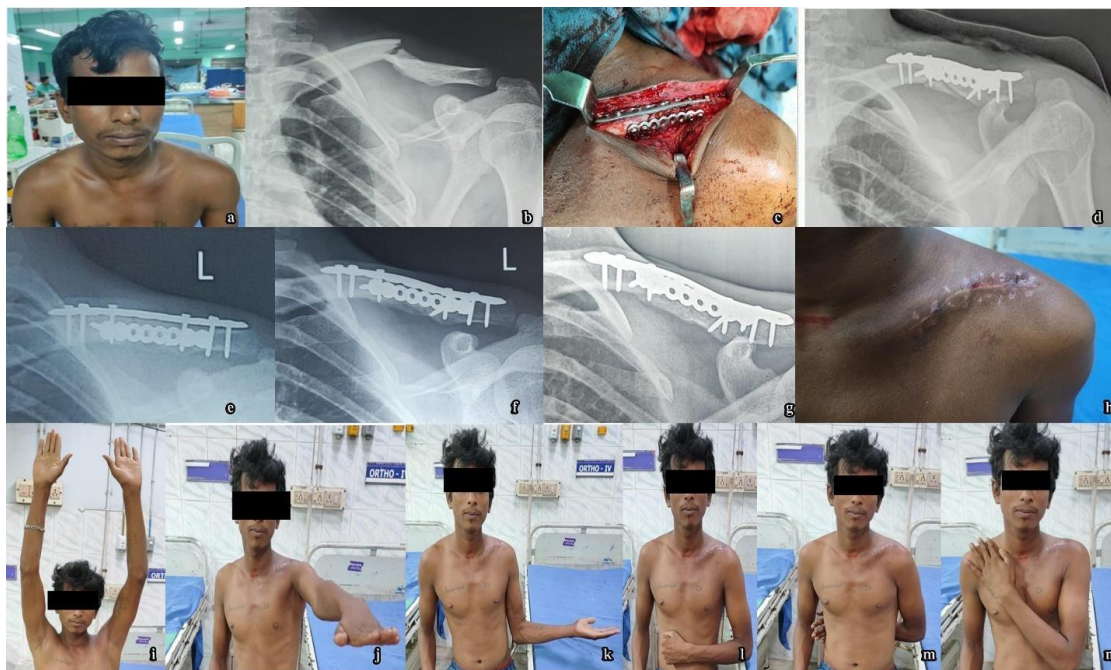*\*Corresponding author*

## INTRODUCTION

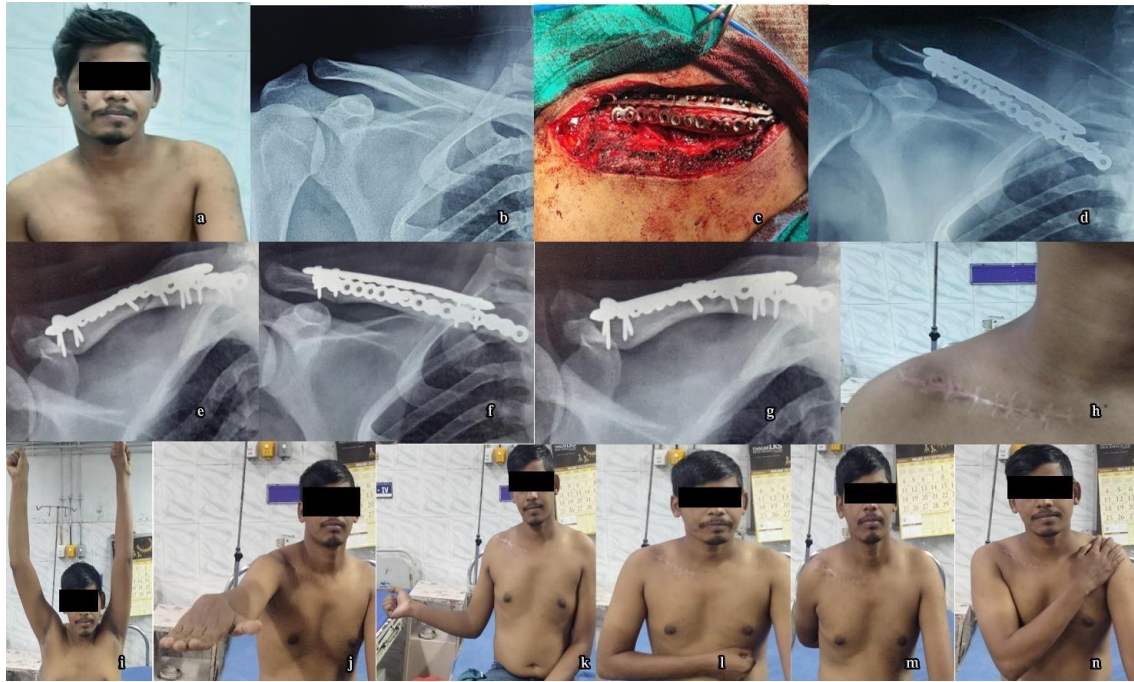
Clavicle fractures are accounts for 2.6% of all fractures [1]. Lot of studies shows that non operative management no longer gives better functional outcome. Many studies show there are more nonunion rates and decreased functions in non-operative management. Therefore, it needs to be treated by operative fixation [2, 3]. Many studies show, using 3.5 mm anatomical plates will have good functional outcome and union rate, but it may cause hardware related complications like implant prominence, infection and irritation. So, there will be higher rate of symptomatic implants removal [1]. Recent studies show, with low profile recon plate will give good functional outcome, low implant related complications and higher union rate [4]. So, the aim of our study is to determine the functional and radiological outcome of superior and anterior plating of clavicle fractures and to study the complications and symptomatic implant removal of superior and anterior plating of clavicle fractures.

## MATERIALS AND METHODS

We have done a retrospective and prospective study in Department Of Orthopedics, Department Of Orthopedics, Government Dharmapuri Medical College And Hospital, Dharmapuri, Tamil Nadu, India, In the year 2023. We included 30 patients in our study. We included patients age more than 18 years, closed fracture with various patterns like transverse, oblique, comminuted, segmental and bending wedge. We excluded patients age less than 18 years, open and pathological fractures. In our study, the patient placed in beach chair position with bolster under the shoulder. Incision site marked between sternal edge and acromion. Skin and subcutaneous tissue incision made and platysma released. Supraclavicular nerve identified and secured. Identify fracture area and minimal soft tissue release practiced and fracture reduced. 2.5mm recon plate contoured and kept over superior surface of clavicle and secured with 2.5 mm locking and non-locking cortical screws. Another 2.5 mm reconstruction plate contoured and kept over the anterior surface of clavicle and secured with 2.5 mm non locking cortical screws. Arm supported with cuff and collar for 2 weeks. Pendular movement exercise started from post-operative day 1. Weight lifting restricted until 6 weeks. Active movements started after 6 weeks. Weight holding up to a glass of water weight can be allowed after 6 weeks postoperatively. Routine weight lifting can be started after 3 months postoperatively. Patient was followed up till 2 years post operatively. Outcome analyzed using DASH score and RUS for clavicle with 45° Cephalad view (to visualize bone which may get hindered by implants) during follow up. (Figure 1 and 2).



**Figure 1: Case 1 – a) pre-operative clinical image b) Pre-operative X ray c) Intra operative image d) Immediate post-operative X ray e) X ray at 6 weeks follow up f) X ray at 3 months follow up g) X ray at 6 months follow up h) post-operative surgical scar i-n) Range of movements during follow up**



**Figure 2: Case 2 - a) Pre-Operative clinical image b) Pre-operative X ray c) Intra operative image d) Immediate post-operative X ray e) X ray at 6 weeks follow up f) X ray at 3 months follow up g) X ray at 6 months follow up h) Post-operative surgical scar i-n) Range of movements during follow up**

**RESULTS**

In our study, the age distribution were 21-30 years is 33.3%, 31-40 years is 33.3%, 41-50 years is 20.0%, 51-60 years is 6.7%, >60 years is 6.7% and Gender distribution were Female is 7.1%, Male is 92.9%. In our study, the Side distribution were Left is 56.7%, Right is 43.3%. The Mode of injury in our study were Bull gore injury is 3.3%, Fall is 16.7%, RTA is 80.0%. In our study, the associated Injury were present in 56.7% and absent is 43.3%. The Associated Injury distributions in our study were Head injury is 33.3%, Long bone fracture is 13.3%, Rib fracture is 6.7%, Vertebra fracture is 3.3%, Nil is 43.3%. The long bone fracture distributions in our study were Proximal both bone is 25.0%, Ipsilateral distal humerus fracture is 25.0%, Floating shoulder is 25.0%, Intertrochanteric femur fracture is 25.0%. In our study, the head injury distributions were Bell's palsy is 10.0%, Extradural hemorrhage is 10.0%, Frontal lobe contusion is 10.0%, Parietal lobe contusion is 10.0%, Subarachnoid hemorrhage is 10.0%, Subdural hemorrhage is 30.0%, Temporal lobe contusion is 20.0%. In our study, complications were Present in 3.3% and Absent is 96.7%. (Table 1). The number of holes plate used anteriorly in our study were 6.0 is 16.7%, 8.0 is 50.0%, 10.0 is 20.0%, 12.0 is 10.0%, 16.0 is 3.3%. The number of holes plate used Superiorly in our study were 8.0 is 36.7%, 10.0 is 43.3%, 12.0 is 16.7%, 16.0 is 3.3%. The fracture patterns observed in our study were Transverse is 26.6%, Oblique is 33.3%, Comminuted is 13.4%, Segmental is 3.3% and Bending Wedge is 23.4% (Table 2). In our study the mean DASH score postoperatively was 4.8. In Our study none of the cases have infection postoperatively. In our study, one case (3.3%) was reported with mild implant prominence. In our study none of the cases underwent implant removal.

**Table 1: Complications distribution**

Complications		
	Frequency	Percent
Present	1	3.3
Absent	29	96.7
Total	30	100.0

**Table 2: Fracture Pattern**

Fracture Pattern		
	Frequency	Percent
Transverse	8	26.6
Oblique	10	33.3
Comminuted	4	13.4
Segmental	1	3.3
Bending Wedge	7	23.4
Total	30	100.0

**DISCUSSION**

Clavicle fracture is one of the commonest fractures in shoulder girdle. Of these midshaft clavicle fracture accounts for nearly 85% of clavicle fracture. Even though non operative treatment for clavicle fracture results in good outcome, malunion, nonunion and shoulder stiffness reported in some cases [2]. Operative treatment like open reduction and precontoured superior anatomical plating is associated with early union and better functional ability [3]. But implant related complications like implant irritation and prominence may occur in precontoured superior anatomical clavicle plating [1]. So alternatively anterior precontoured plate can be used. Dual mini fragment reconstruction plates are used now a day. It is a low profile system which decreases implant related problems like irritation and prominence and reduces the need of implant removal when compared with single antero-interior plating [4]. Clavicle exhibits multiplanar motion which can be better resisted by placing two plates in two orthogonal plane. Dual plating using long superior reconstruction plate and small anterior reconstruction plate resists torsion, axial load, shear force and bending forces which are produced during movements of clavicle. Other advantages of Dual plating are that it has ability to buttress butterfly fragments in comminuted fracture pattern. In Dual plating, one plate can act as a reduction aid when other plate is applied. Even though dual plating requires more soft tissue exposure, there is higher union rate. This is due to extra periosteal placement of plates which decreases damage of small blood supply to bone which increases union rate [5]. In Toogood et al., Biomechanical study the observed that in clavicle fracture torsion and compression are better controlled with superior plate, whereas cantilever bending is better controlled by anterior plate [6]. Prasarn et al., studied both biomechanically and clinically about dual plating for clavicle fracture. In their case series they include 17 patients treated with dual mini-fragment plating [7]. Compared to our study the mean age of 37.1 years, the mean age of Prasarn et al., study was 31.3. The average Post-operative DASH score was 4.0 for Prasarn et al., and ours was 4.8 which is comparable to our study. In Prasarn et al study, 100% union rate was observed. Our study shows 100 % union rate as compared to their study. Wound dehiscence and infection complications were not observed in Prasarn et al., Study and our study also none of the cases observed these complications. Allis et al., in their comparative study studied 44 patients into 2 groups, one group being 21 patients undergone surgery using single 3.5-mm, superior plate construct and another group being 23 patients undergone surgery using dual, low profile 2.7 mm superior and 2.4 mm anterior plate construct [8]. In Allis et al study., among single plate group, 5 patients underwent implant removal due to implant related complications and 1 patient underwent reoperation due to wound infection and in dual-plate group, there were no reoperations. In our study, symptomatic implant removal was not done in any of the cases which is comparable to their study. Complications in the 3.5-mm single plate group were 4.8% and in dual-plate group, it was 4.3% observed by Allis et al., and our study was 3.3% (implant prominence) as comparable to their study. Zhuang et al., in their comparative study, compared 30 clavicles fixed with single locking plate and 17 clavicles fixed using dual locking, reconstruction low profile plates [5]. Zhuang et al., observed 8.5% of patient showed no signs of union in Single plate group and all patients achieved union (100%) in dual-plate group at 6 months postoperatively in their study. Union rates of 93.3% in single plate and 100% in dual plate groups at 1 year follow up was observed by Zhuang et al., our study shows 100% union rate at 6 months which is comparable to their study. In Chen et al., study, they compared two groups being one group of 125 patients treated by single plating another group of 34 patients treated by dual plating [9]. In Chen et al., study, 91.1% cases achieved union and no union observed in 4.0% cases at 6 months in single plate group whereas in dual plating group, all the patients attained bony union within 6 months. In our study, all the patients attained union (100%) within 6 months as compared to their study. In Chen et al study, complications occurred in 22 patients in single plate group of these 8 patients showed implant prominence whereas in dual plate group implant prominence observed in 2 patients. In our study one patient (3.3%) observed implant prominence. In Chen et al study., 10 patients undergone plate removal in

single plating group whereas no plate removal was done in the dual plating group. In our study none of the patients undergone implant removal. De Baun et al., they compared two groups, one group of 74 cases underwent Precontoured single plating and another group of 60 cases underwent dual mini fragment plating [10]. In De Baun et al study, there was 98.3% union rate in dual mini fragment group and 100% union rate in single plate group. Our study shows 100% union rate which is comparatively significant with their study. In De Baun et al study., 8.3% cases underwent symptomatic implant removal in dual mini fragment plate group when compared with 20.2% cases undergone symptomatic implant removal in single plate group. In our study none of the patients underwent symptomatic implant removal until union which is comparatively significant with their study. In Chen et al study, they retrospectively studied the safety and efficacy of dual plating for clavicle in 20 patients [11]. Compared to our mean age of 37.1 years, the average age in Chen et al., study was 40.6 years. In Chen et al study 33% cases were female. In our study 26.7 % cases were female. In Chen et al study, 36% of cases had associated chest injuries. In our study 6.7% cases were associated with chest injuries. In Chen et al., study 3 cases (15%) had symptomatic implant removal. In our study none of the cases underwent implant removal. All 36 fractures (100%) went union in Chen et al., Study. Our study shows 100 % union rate which is comparable to their study. In Chen et al., study, Occasional implant irritation was reported in 24% cases and significant implant irritation was reported by one case (6%). In our study, one case (3.3%) was reported with implant prominence which is comparatively significant with their study. In Chen et al study, one case of superficial infection (2.8%) was reported. In Our study none of the cases have infection postoperatively. In Chen et al., Study the Average Quick- DASH scores were  $5.7 \pm 9.4$ . In our study the mean DASH score postoperatively was which is comparable to their study. What we infer from our study is that low profile dual plating provides excellent stability to clavicle. It allows early mobilization in all directions. Since it is a low-profile plate implant prominence is less. Patients achieved good union rate and excellent functional outcome in patients treated with dual plating. Patients can return to work earlier in dual plating. Patients satisfied with the outcome after the procedure [12-15].

### CONCLUSION

Dual plating using lower profile plates can be chosen as the surgeon's choice for treating clavicle fracture as it provides multiplanar stability, excellent union rate and functional outcome. Dual plating also helps to maintain reduction even in complex fracture patterns. Dual plating does not show any symptomatic implant removal in our study. There is no evidence of wound related complications in our study.

### REFERENCES

- [1] Canadian Orthopaedic Trauma Society. Nonoperative treatment compared with plate fixation of displaced midshaft clavicular fractures. A multicenter, randomized clinical trial. *J Bone Joint Surg Am* 2007;89(1):1-10.
- [2] Zlowodzki M, Zelle BA, Cole PA, et al. Treatment of acute midshaft clavicle fractures: Systematic review of 2144 fractures: On behalf of the Evidence-Based Orthopaedic Trauma Working Group. *J Orthop Trauma* 2005;19(7):504-507.
- [3] McKee RC, Whelan DB, Schemitsch EH, et al. Operative versus nonoperative care of displaced midshaft clavicular fractures: A meta-analysis of randomized clinical trials. *J Bone Joint Surg Am* 2012;94(8):675-684.
- [4] Galdi B, Yoon RS, Choung EW, Reilly MC, Sirkin M, Smith WR, Liporace FA. Anteroinferior 2.7-mm versus 3.5-mm plating for AO/OTA type B clavicle fractures: a comparative cohort clinical outcomes study. *J Orthop Trauma* 2013;27(3):121-5.
- [5] Zhuang Y, Zhang Y, Zhou L, Zhang J, Jiang G, Wu J. Management of comminuted mid-shaft clavicular fractures: Comparison between dual-plate fixation treatment and single-plate fixation. *J Orthop Surg (Hong Kong)* 2020 ;28(2):2309499020915797.
- [6] Toogood P, Coughlin D, Rodriguez D, Lotz J, Feeley B. A biomechanical comparison of superior and anterior positioning of precontoured plates for midshaft clavicle fractures. *Am J Orthop (Belle Mead NJ)* 2014;43(10):E226-31.
- [7] Prasarn ML, Meyers KN, Wilkin G, Wellman DS, Chan DB, Ahn J, Lorich DG, Helfet DL. Dual mini-fragment plating for midshaft clavicle fractures: a clinical and biomechanical investigation. *Arch Orthop Trauma Surg* 2015;135(12):1655-62.
- [8] Allis JB, Cheung EC, Farrell ED, Johnson EE, Jeffcoat DM. Dual Versus Single-Plate Fixation of Midshaft Clavicular Fractures: A Retrospective Comparative Study. *JB JS Open Access*

- 20201;5(2):e0043.
- [9] Chen X, Shannon SF, Torchia M, Schoch B. Radiographic outcomes of single versus dual plate fixation of acute mid-shaft clavicle fractures. *Arch Orthop Trauma Surg* 2017;137(6):749-754.
- [10] DeBaun MR, Chen MJ, Campbell ST, Goodnough LH, Lai C, SalazarBP, Bishop JA, Gardner MJ. Dual Mini-Fragment Plating Is Comparable With Precontoured Small Fragment Plating for Operative Diaphyseal Clavicle Fractures: A Retrospective Cohort Study. *J Orthop Trauma* 2020 ;34(7):e229-e232.
- [11] Chen MJ, DeBaun MR, Salazar BP,Lai C, Bishop JA, Gardner MJ. Safety and efficacy of using 2.4/2.4 mm and 2.0/2.4 mm dual mini- fragment plate combinations for fixation of displaced diaphyseal clavicle fractures. *Injury* 2020;51(3):647-650.
- [12] Wun-jer Shen, Tsung - Jen Liu, Young - “Shung Shen. Plate fixation of fresh displaced mid shaft clavicle fractures.” *International journal of the care of the injured* 1999;30(7):497-500,
- [13] Boehme D et al. Nonunion of fractures of mid shaft clavicle. *J Bone Joint Surg (Am)* 1991; 73:1219e1226.
- [14] Mckee MD et al. Midshaft malunions of the clavicle. *J Bone Joint Surg (Am)* 2003; 85:790e797.
- [15] Zlowodzki M et al. treatment of acute midshaft clavicle fractures: systematic review of 2144 fractures; on behalf of the Evidence based Orthopaedic Trauma working group. *J Orthop Trauma* 2005; 19:504-7