

# Research Journal of Pharmaceutical, Biological and Chemical Sciences

## Cerebral Abscess With Paraplegia - A Delayed Electrical Burns Complication: A Case Report.

Rathi Sayali Bharatkumar<sup>1\*</sup>, Paturu madhu<sup>2</sup>, Junaid Minaj Shaikh<sup>3</sup>, and  
Sarojini Jadhav<sup>4</sup>.

<sup>1</sup>Gen Surgery Resident, Department of Surgery, GMC, Aurangabad, Maharashtra, India.

<sup>2</sup>Gen Surgery Resident, Department of Surgery, GMC, Aurangabad, Maharashtra, India.

<sup>3</sup>Assistant Professor, Department of Surgery, GMC, Aurangabad, Maharashtra, India.

<sup>4</sup>HOD & Professor, Department of Surgery, GMC, Aurangabad, Maharashtra, India.

### Abstract

Electrical burns present unique challenges in diagnosis and management due to their potential for hidden deep tissue damage. We presented a case of a 30-year-old male who sustained an accidental electrical burn to the head, resulting in an exit wound on the left thigh. Despite initial stability, the patient developed bilateral lower limb weakness on post-burn day 5, attributed to paraspinal edema in the cervical region. Corticosteroid therapy led to partial improvement. However, on post-burn day 38, the patient experienced seizures, prompting brain imaging revealing a cerebral abscess. Aggressive antibiotic therapy was initiated, resulting in resolution of seizures and reduction in abscess size. This case underscores the insidious nature of electrical burns, which can manifest delayed neurological complications such as abscess formation even in the absence of initial overt symptoms. Clinicians should maintain a high index of suspicion for such complications, especially in cases involving high voltage exposures, to facilitate early diagnosis and intervention.

**Keywords:** cerebral abscess, electrical burns, paraplegia, delayed complications.

<https://doi.org/10.33887/rjpbcs/2024.15.2.56>

*\*Corresponding author*

## INTRODUCTION

Electrical burns can be the most devastating type of burn injury. Although other etiologies of burn injury can be quantified by a careful evaluation of the skin, electrical burns can be difficult to diagnose the exact extent of the injury [1]. These types of burns are also often associated with other traumatic injuries or secondary flash or blast injuries from the superheated air surrounding the electrical current. In an electrical burn, electricity travels along the path of least resistance which in human tissue corresponds directly with the water content of that tissue. Wet or lacerated skin offers much less resistance to electricity and allows current to flow to deeper structures [2]. Nerve tissue typically has the least resistance to electrical energy, and may be damaged even when current is of low voltage and no cutaneous or musculoskeletal manifestations are present [3]. Blood and vascular tissue have low resistance to current, and muscle and viscera have slightly higher resistance. Bone and fat have the highest resistance to current. The consequence of higher resistance is that more energy is lost to higher-resistance tissue in the form of heat, causing coagulation necrosis and burns both in the high-resistance tissues and in surrounding tissues. This poses a challenge for the emergency clinician, as the extent of surface burns may not reveal the extent of burns to visceral and deep muscular tissues, especially when the skin of the patient is wet or there is skin breakdown, lacerations, and / or abrasions.

## CASE PRESENTATION

Herewith we reported, a case of 30 year old male patient came with alleged history of accidental electrical burn injury over a head while working over an electrical pole. The patient on examination was vitally stable. Conscious and oriented to time, place and person. The entry wound was over left occipital region initially not as well appreciated and exit wound was present on left thigh 5 cm above patella. On admission ECG was done and normal sinus rhythm was noted. Patient was admitted in burns wards underwent basic resuscitation and entry as well as exit wounds were debrided. On post burn day 5 patient was noticed to have bilateral lower limb weakness with power 0/5 in bilateral lower limb. MRI spine was done which revealed mild paraspinal edema in cervical region. He was given 5 days of course of corticosteroids which showed improvement in power up to 3/5 was appreciated. On post burn day 38 patient suddenly started having multiple generalised tonic clonic seizures and was given loading dose of Dilantin followed by maintenance dose. Emergency CECT brain was done to revealed peripherally enhancing subdural collection of 20 cc in left parietal and occipital lobe with adjacent leptomeningitis with small peripheral enhancing lesion of 2 cc s/o intraparenchymal abscess. 14 days of injectable vancomycin, ceftriaxone and metronidazole was given. No episodes of generalised tonic clonic seizures were noted. On 14th day of antibiotic treatment patient was subjected to NCCT brain which revealed collection of 11 cc. Patient was discharged and called for follow up for flap surgery.

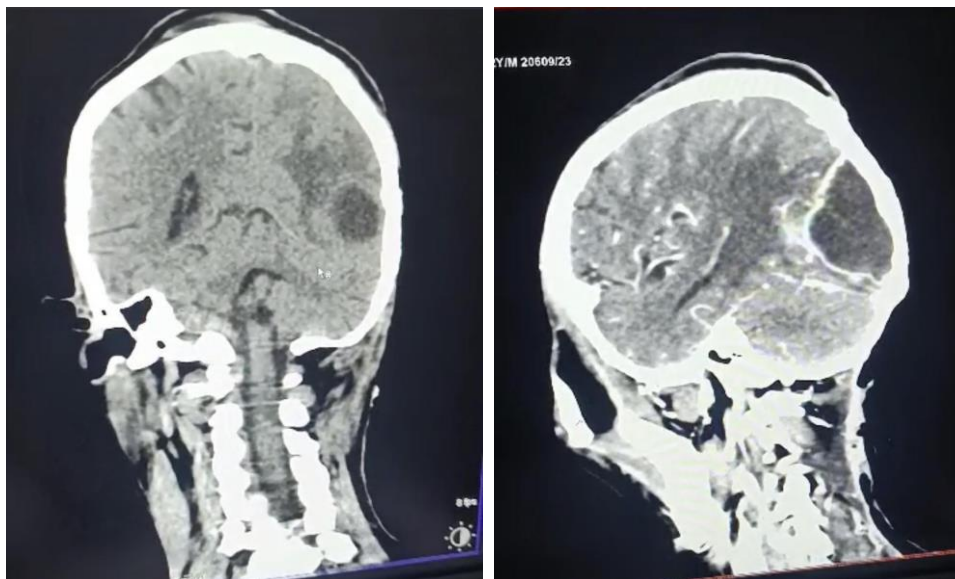
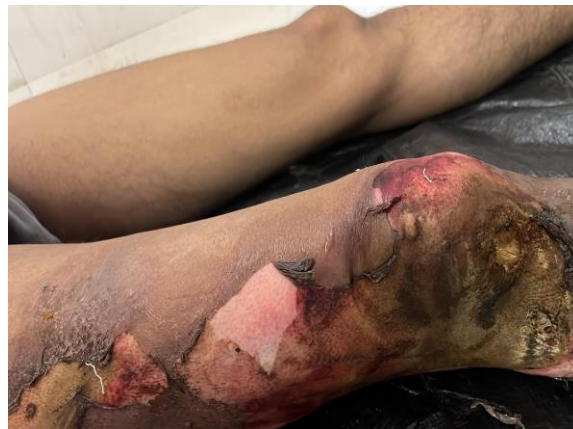
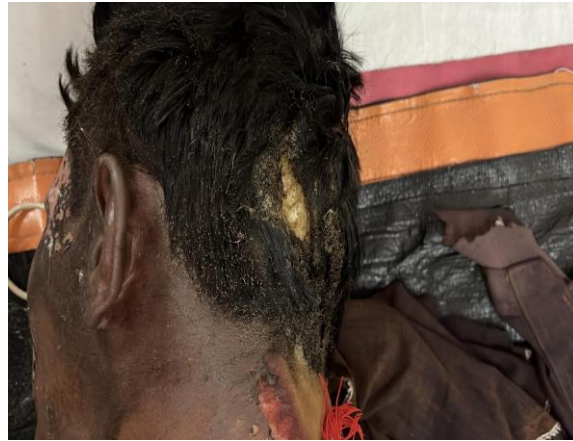
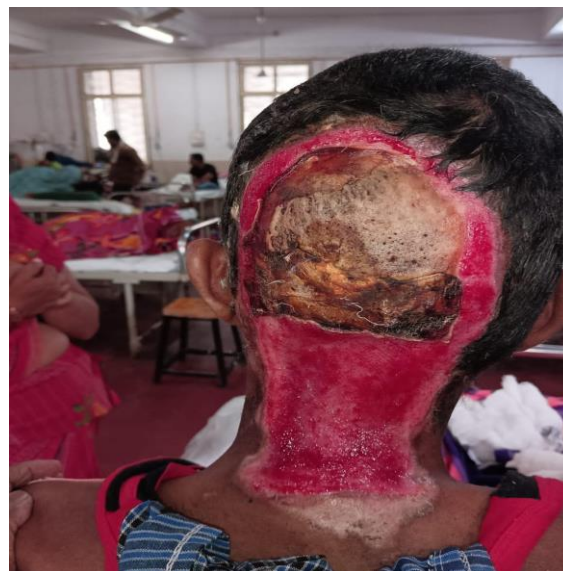Figure 1 and 2: CT scan



**Figure 3 and 4: On admission**



**Figure 5: On discharge with serial debridements**

#### **DISCUSSION**

Nerve tissue is highly conductive, and neurological injury after electric shock is common. This can be due to direct thermal damage to nerve tissue or from electroporation, which is especially damaging to nerve cells that are dependent on establishing electrolyte gradients for proper functioning. The most common neurological complaint after electric shock is loss of consciousness [4].

In a survey study of a cohort of both high- and low-voltage exposures, over 80% of patients had delayed neurological complaints, including numbness, weakness, paresthesia, and difficulty concentrating.<sup>5</sup> A prospective cohort study established a 28% incidence of neurologic injury in a primarily low-voltage exposure group, 40 similar to the 25% found in a study by Arnoldo et al. Injury pattern is important, as many patients complain of paresthesia or permanent numbness at the entrance and exit sites, and a pathway that traverses the spinal cord (i.e., from one limb to another) puts a patient at risk for spinal cord lesions. The amount of current and the voltage are relatively less predictive of the types and severity of neurologic injury. Immediate symptoms often resolve and have a better prognosis than late sequelae.

Patients may also develop secondary neurological injury from hypoxia and subsequent ischaemia after cardiac arrest or spinal cord injury due to spinal artery vasospasm. There is a higher incidence of spinal cord injury in high voltage trauma. These are most often reported as transverse lesions with posterior cord syndrome.

### CONCLUSION

This case highlights the complex nature of electrical burn injuries and their potential for delayed, life-threatening complications. Despite initial stabilization and apparent improvement, the development of bilateral lower limb weakness and subsequent seizures led to the discovery of a cerebral abscess, underscoring the importance of thorough evaluation and ongoing monitoring in these patients. Prompt recognition and intervention are crucial in mitigating the impact of such complications, as evidenced by the successful resolution of seizures and reduction in abscess size with aggressive antibiotic therapy.

### REFERENCES

- [1] Gandhi G, Parashar A, Sharma RK. Epidemiology of electrical burns and its impact on quality of life - the developing world scenario. *World J Crit Care Med* 2022;11(1):58-69.
- [2] Opara KO, Chukwuanukwu TO, Ogbonnaya IS, Nwadinigwe CU. Pattern of severe electrical injuries in a Nigerian regional burn centre. *Nigerian J Clinical Practice* 2006; 9:124-127
- [3] Taha MM, Elbadawy MK, Azzam AMN, Taha MM, Alkheder A, Abualkhair KA. Delayed brain abscess as a complication of cerebral infarction: A rare case report and review of the literature. *Int J Surg Case Rep* 2024; 117:109500.
- [4] La Russa R, et al. Post-Traumatic Meningitis Is a Diagnostic Challenging Time: A Systematic Review Focusing on Clinical and Pathological Features. *Int J Mol Sci* 2020; 21:4148.
- [5] Kanitkar S, Roberts AH. Paraplegia in an electrical burn: a case report. *Burns Incl Therm Inj* 1988 Feb;14(1):49-50.