

Research Journal of Pharmaceutical, Biological and Chemical Sciences

Role Of PET-CT Scan In Staging And Predicting Outcome In Cases Of Newly Diagnosed Breast Carcinoma.

Akshaya Ravichandran¹, and Padmasen V Ranbagle^{2*}.

¹Resident, Department of Surgery, Byramjee Jeejeebhoy Government Medical College and Sassoon General Hospital, Maharashtra, India.

²Padmasen Vishnu Ranbagle, Associate Professor, Department of Surgery, Byramjee Jeejeebhoy Government Medical College and Sassoon General Hospital Pune, Maharashtra, India.

ABSTRACT

Recently, molecular imaging techniques for tumor detection have gained interest such as FDG-PET scan. The primary objective of the study was to study how PET-CT scan affects staging of newly diagnosed breast cancer. The secondary objective was to study impact of PET-CT scan on subsequent management in newly diagnosed cases of breast carcinoma and to study the impact of PET-CT on prognosis of newly diagnosed cancer. A Prospective Observational study was conducted at Sassoon General Hospital Pune in Western Maharashtra from January 2020 to June 2021 among patients having palpable breast lumps (>2cm) and diagnosed and confirmed as primary breast cancer by triple assessment i.e. clinical examination, radiological assessment and histopathology. All patients fitting the inclusion criteria were assessed by the triple assessment containing history and clinical examination- inspection and palpation of bilateral breast and axilla and supraclavicular fossa, Tissue diagnosis -trucut/FNAC and Radiological imaging -USG and PET/CT: FDG PETCT was done in all the patients. All the scans were performed using a Siemens Biograph dual source mCT20 Excel PET/CT, equipped with 128 slices CT. The Comparison of change in TNM Staging between Initial and restaging after PETCT scan revealed that there was overall change in 44% cases whereas 56% cases remained at the same staging. Among 50 enrolled cases FDG Uptake was positive in all primary breast masses. At axillary lymph node FDG Uptake was positive in 92 % cases. Distant Organ involvement was seen in 16% cases based on FDG uptake. Average SUV max Breast (SUVbt) (N = 50) was 08.89 ± 05.80 whereas average SUV max ipsilateral axillary lymph node (SUVln) (N = 47) was found to be 04.85 ± 03.84 . In the initial stage assessment, preoperative FDG-PET/CT has a substantial impact on staging and on clinical management and we suggest that PET/CT could be considered in the initial assessment of patients with newly diagnosed early-stage breast cancer.

Keywords: PET-CT, breast carcinoma, tumor.

<https://doi.org/10.33887/rjpbcs/2024.15.1.31>

**Corresponding author*

INTRODUCTION

According to WHO, in 2020, there were 2.3 million women diagnosed with breast cancer and 685 000 deaths globally. As of the end of 2020, there were 7.8 million women alive who were diagnosed with breast cancer in the past 5 years, making it the world's most prevalent cancer [1]. There are more lost disability-adjusted lifeyears (DALYs) by women to breast cancer globally than any other type of cancer. Breast cancer occurs in every country of the world in women at any age after puberty but with increasing rates in later life. Many risk factors are well-known; however, the exact causes of breast cancer have not been identified. Family history of breast cancer, mutations such as BRCA (1 and 2) and p53 are considered to convey a very strong risk of developing the disease [2]. Mammography, ultrasound (US), and magnetic resonance imaging (MRI) are employed as diagnostic tools for several years. Recently, molecular imaging techniques for tumor detection have gained interest such as FDG-PET scan. Extensive and growing evidence suggests that FDG PET/CT identifies previously unsuspected distant metastases in patients with locally advanced breast cancer [3]. The detection of distant metastases has a substantial clinical effect, changing the patient's stage from one reflecting only locoregional disease to stage IV. This converts patient management from curative-intent therapy by surgery with or without neoadjuvant therapy to palliative systemic therapies.

This study summarizes the evidence about the role of 18F-FDG PET/CT in breast cancer staging and the therapeutic and prognostic impact.

Aims and Objectives

The primary objective of the study was to study how PET-CT scan affects staging of newly diagnosed breast cancer. The secondary objective was to study impact of PET-CT scan on subsequent management in newly diagnosed cases of breast carcinoma and to study the impact of PET-CT on prognosis of newly diagnosed cancer.

METHODOLOGY

A Prospective Observational study was conducted at Sassoon General Hospital Pune in Western Maharashtra from January 2020 to June 2021. The study population were patients having palpable breast lumps. The inclusion criteria consisted of patients >18years with palpable breast lumps(>2cm) and diagnosed and confirmed as primary breast cancer by triple assessment i.e. clinical examination, radiological assessment and histopathology. The exclusion criteria were patients with recurrent breast carcinoma, pregnant patients (PET is a relative contraindication), patients with deranged blood sugar levels. (Except controlled BSL with HBA1C <7) and patients not willing for procedures and follow up. The sample size was 50 cases of newly diagnosed Carcinoma breast during the specified duration. Institutional Ethical committee clearance was obtained. After informed consent, patients were enrolled and data was documented on pre-validated case record sheet. Data source were patients case record sheet and indoor admission files. The demographic data was recorded in addition to clinical and laboratory and radiological findings. Variables documented were History: Complaint, II. Age, family history, menstrual history-Age at menarche, age at menopause, parity, age at first child birth, lactation, use of hormonal therapy or contraceptives. On clinical examination- inspection and palpation of bilateral breast and axilla and supraclavicular fossa details were documented. Tissue diagnosis Trucut/ core biopsy was done for confirmation of diagnosis. The Trucut biopsy provided full histology as opposed to FNAC which only provided cytology, allowing differentiation between invasive and in-situ carcinoma. This gave tumor staging and grading and had higher sensitivity and specificity than FNAC for detecting breast cancer. Further ER,PR, Her2 NEU and KI67 status of the lump was also classified. The PET/CT – 2 F-FDG PETCT was done in all the patients after taking consent from the patients and their relatives. All the scans were performed using a Siemens Biograph dual source mCT20 Excel PET/CT, equipped with 128 slices CT. Patients were instructed to stay nil oral for about 6 h before the injection time. Serum glucose levels were measured before injection to confirm prescribed normal glucose levels and to exclude hyperglycemia / hypoglycemia status (required blood glucose level < 160 mg/ dL). Then, 370–550 MBq of 18F-FDG was injected with a saline infusion in the antecubital vein depending on the patient's weight. Whole body PET/CT scans were performed approximately 1 hour post injection. Scanning was performed in a supine position with patient's arms rested above the head. A low-dose CT scan, for attenuation correction and anatomical mapping. The acquisition was performed in helical mode from the base of skull to midthigh region, using 150 kV, 50 mAs, and a 512 × 512 matrix size, acquiring a field of view (FOV) of 780 mm in

about 20 s. The emission PET scan was acquired, after the low dose CT, from the skull base to mid-thigh region in a three-dimensional mode (3D). Imaging was performed, using sequential overlapping bed positions with the acquisition time of 3 minutes per bed position. The number of bed positions depends on the patient's height with one-slice overlap at the borders of the FOV. The low-dose CT images were rescaled to produce attenuation correction values for the PET scan. Image reconstruction was based on point-spread function (PSF) together with time of flight (TOF). The projection data were reconstructed by 3-mm slice thickness. Gaussian filter (FWHM, 2mm) was used for the reconstructed data. Finally, the low-dose CT was reconstructed using a convolution kernel B20f body filter. Following PET imaging, volumetric contrast-enhanced CT scanning was performed from the base of skull to mid-thigh on the same PET/CT machine using the helical 120-slice multidetector CT system of the PET/CT scanner.

Intra-venous contrast was given at a rate of 1.5 ml/kg with overall dose ranging from 80 to 100 ml. The CT acquisitions were performed using a 1.2- pitch and 20 × 0.6 mm collimation for detector configuration. The gantry rotation time was 0.5 s, field of view of 78 cm, and reconstruction matrix of 512 × 512. Images were reconstructed and viewed on workstation which provided multi-planar reformatted PET, CT, and fused PET/CT images as well as MIP PET images in video mode.

The statistical analysis was performed as follows. Primary data was collected in paper based proforma and the data was then entered in Microsoft Excel spreadsheets 2016. Statistical analysis was done on IBM SPSS STATISTICS VERSION 20. Categorical variables were taken in the form of frequencies and proportions and cross tabulations were done for the chosen parameters and column proportions were compared using Chi square test. Continuous variables were expressed in the descriptive statistics tables as means, standard deviation, maximum and minimum value. P value < 0.05 was considered significant and p value < 0.01 was considered highly significant.

RESULTS

Average age of the patients studied was 54.3 ± 13.09 years. The youngest patients was 30 years old and the eldest was 81 years old. There was only 1 male (2%) enrolled in the study. Rest 49 (98%) were females. Average weight of the patients studied was 56.06 ± 9 kg and average height was 158.02 ± 4.52 cms. 3(6%) patients were found underweight. 6(12 %) patients were overweight whereas 2(4%) were obese. Majority of the patients 42(84%) were married. 30(60%) of the females had active menstruation whereas remaining females were menopausal. (Table 1) Obstetric history majority of the females 44(88%) were multiparous and 5(10%) were nulliparous. Associated comorbidities and history 14(28 %) patients had comorbidities. 11(22 %) had associated hypertension and 3(6%) had Bronchial Asthma . Positive breast cancer history in family was present in 9(18 %) cases whereas history of surgery in the past was present in 11(22 %) cases. (Table 2).

27(54%) cases had lump on the left side whereas 23(46%) had it on right side. The large majority of the tumour was Invasive ductal carcinoma (IDC) which was found in 40(80%) cases on histopathological diagnosis. The second common type observed was Ductal carcinoma in situ (DCIS) with 07(14%) cases. Lobular Ca was found in 2(4%) cases whereas mucinous Ca was found in 1(2 %) cases. Lump size and Volume 14(28 %) tumour had volume < 10 Cm³. 16(32 %) tumours had total volume between 10-40 cm³. 11(22 %) cases had volume of 40-80 cm³. 9(18 %) tumours has volume > 80 cm³. Primary Method of diagnosis For the Primary diagnosis, Trucut biopsy was used in 36(72 %) cases whereas 14(28%) were performed using FNAC. (Table 3).

TNM Staging and Comparison one case was found in T1N0M0 grade. Initially only 2 cases were placed in T1N1M0 stage which was increased to 3 cases after restaging. Initially 5 cases were staged T2N0M0 which were reduced to 2 after restaging. 23(46%) cases were staged at T2N1M0. The number was reduced to 19 after restaging. 7 cases were classified as T3N1M0 initially. After restaging the number reduced to 6. There was only one case in T3N1M1 class initially but after restaging the number was 4. 4 cases were classified as T4aN1M0 in the initial staging but the number in restaging reduced to 2.(Table 4).

The comparison of change in TNM Staging between Initial and restaging after PET-CT scan revealed that there was overall change in 22(44%) cases whereas 28(56%) cases remained at the same staging. (Table 5) FDG Uptake was positive in all primary breast masses. At axillary lymph node FDG Uptake was positive in 46(92 %) cases. Distant Organ involvement was seen in 32(16%) cases based on FDG uptake. At internal mammary lymph node FDG uptake was positive in 7(14%) cases. At

supraclavicular lymph nodes it was found positive in 5(10%) cases only. SUV max Average SUV max Breast (SUVbt) (N = 50) was 08.89 ± 05.80 whereas average SUV max ipsilateral axillary lymph node (SUVln) (N = 47) was found to be 04.85 ± 03.84 Recommendation of management based on PET-CT Breast-conserving surgery (BCS) was recommended to overall 4(8%) cases found in 2A stage. Modified radical mastectomy (MRM) was recommended in 19(38%) cases of IIB, 7(14%) cases of IIIA stage, 3(6%) cases of IIIB stage and 1(2%) case of IIA stage. Chemo radiation was recommended for 9(18%) cases in grade IV. Neoadjuvant chemotherapy (NAC) was recommended to 1(2%) case of grade IV. Palliative care was recommended to 4(8%) cases of grade IV. Toilet mastectomy was recommended to 1(2%) case each of grade IV and grade IIIB. (Table 6,7,8)

DISCUSSION

In our study almost all the breast primary lesions showed FDG uptake. The FDG avidity of a breast cancer lesion was thought to be multifactorial dependent. One of these factors is the histological type of the tumour, with highest uptake noted in Invasive Ductal Carcinoma and relatively low in other histopathology groups, however this variable affinity has little effect on the clinical utility of PETCT. In our study the large majority of the tumours diagnosed were of Invasive ductal carcinoma (IDC), found in 80% cases on histopathological diagnosis. The second common type observed was Ductal carcinoma in situ (DCIS) with 14% cases. Lobular Carcinoma was found in 4% cases whereas mucinous carcinoma was found in 2 % cases. FDG uptake was positive in all primary breast masses. Average SUV max Breast (SUVbt) (N = 50) was 08.89 ± 05.80 . It was postulated that larger tumors, high-grade tumors, and tumors with the triple-negative profile tend to have higher FDG uptake. Our results were consistent with that of Jung et al., and Dong et al., which showed Invasive lobular carcinomas demonstrate lower SUVmax than IDCs.^(4,5) The lower FDG uptake in ILC may account for decreased detection rates on FDG PET [4, 5]. Differences in SUVmax values are mainly due to the enormous biological heterogeneity of breast carcinoma, even among tumors of the same molecular phenotype, although differences in PET acquisition i.e. prone or supine and in the way the region of interest was selected either automatically or manually may also contribute to variation among the studies.

In our study, PETCT showed FDG avidity in 92% of the axillary nodes suggesting nodal metastases while 4% of the axillary nodes didn't show any uptake which was statistically significant. Extraaxillary lymph nodal involvement was diagnosed in Internal mammary nodes and supraclavicular lymph nodes. 14% of the internal mammary nodes were positive on PETCT and only 10 % of the supraclavicular lymph nodes were positive both were statistically significant. The average SUV maximum in ipsilateral lymph node was found to be 04.85 ± 03.84 . Several studies have found that 18f FDG PETCT is more accurate than conventional imaging in the detection of axillary and extra axillary lymph node metastases and distant metastases [6-8]. Distant organ involvement was seen in 16% cases in PETCT changing the overall TNM staging. Majority of the organs involved consisted brain, vertebrae and liver. According to these results, the fused PET/CT examination shows high sensitivity and specificity in detecting lymph nodes, distant organ metastasis in cases of breast cancer.

In this study all the patients were staged under TNM initially and restaged with FDG PETCT scan results. 18f -FDG PETCT scan results were interpreted and the maximum standardized uptake value (SUVmax), reflecting the degree of FDG uptake within a lesion, was calculated. This interpretation criteria for local and distant metastases showed agreement with few studies and in discordance with another few studies. In our study, 2 cases were initially found to be T1N1M0 and after restaging with PETCT scan the number increased to 3 cases. Similarly, 5 cases of T2N0M0 were reduced to 2 after restaging; 23 cases were initially staged as T2N1M0 were reduced to 19 after restaging. 7 cases were initially classified as T3N1M0 were reduced to 6 on restaging. There was only one case in T3N1M1 class initially but after restaging the number was 4. 4 cases were classified as T4aN1M0 in the initial staging but the number in restaging reduced to 2. These observations show that the comparison of change in TNM Staging between initial and restaging after PET-CT scan revealed that there was overall change in 44% cases whereas 56% cases remained at the same staging. Our results were correlating with the observations mentioned by Bernsdorf et al [9]. In studies with a 44% change of stage, a substantial part of the changes was due to axillary lymph node and distant organ metastases detected by PET/CT only. Few studies were not in supportive of recommending PETCT in clinically negative axilla. Study by Caresia Aroztegui et al also supported the similar studies, however our study has shown the utility of PETCT in identifying lymph nodes those were clinically negative and changing of the overall staging [10].

The therapeutic impact of 18 f FDG PETCT in early-stage breast cancer remained still under research till now. Jeong et al [11] reported that PETCT doesn't show significant impact in the treatment of patients with early Breast cancer with clinically negative axillary nodes, however our study results are agreeing with the results of the study by Bernsdorf et al which found a substantial impact on the initial staging and on the clinical management in patients with early stage breast cancers and tumours more than 2 cm [9]. Future studies addressing the treatment decision making using PETCT in Carcinoma breast to evaluate whether or not a change in disease stage or treatment at initial assessment leads to a survival benefit.

Table 1: Demographic Data

Parameters	N = 50
Age (Years) Mean SD	54.30
Range	13.09 30 - 81
Gender N (%)	01 (02.0)
Male Female	49 (98.0)
Weight Mean SD	56.06
Range	09.00 38 - 84
Height Mean SD	158.02
Range	04.52 146 - 167
BMI N (%)	
<18	03 (06.0)
18-25	39 (78.0)
25-30	06 (12.0)
>30	02 (4.0)
Marital Status N (%)	42 (84.0)
Married Unmarried	03 (06.0)
Widowed	05 (10.0)
Menstruating/ menopausal N (%) Menstruating	30 (60.0)
Menopausal	19 (38.0)
Not applicable	01 (02.0)

Table 2: Profile of Obstetric History and Comorbidities

Obstetric History (N = 50)	No.	%
Nulliparous	05	10.0
Multipara	44	88.0
Not applicable	01	02.0
Comorbidities (N = 50)		
HTN	11	22.0
BA	03	06.0
None	37	74.0
Positive breast cancer history in family (N = 50)		
Yes	09	18.0
No	41	82.0
History of surgery (N = 50)		
Yes	11	22.0
No	39	78.0
Lump position (N = 50)		
Left	27	54.0
Right	23	46.0

Table 3: Profile of Lump Size and method of diagnosis

Lump size (Volume)(CM ³) (N = 50)	No.	%
<10	14	28.0
10 – 40	16	32.0
40 - 80	11	22.0
>80	09	18.0
Method of diagnosis(N = 50)		
FNAC	14	28.0
Trucut Biopsy	36	72.0
Diagnosed Carcinoma (N = 50)		
Left breast carcinoma	27	54.0
Right breast carcinoma	23	46.0

Table 4: Profile of TNM Staging

TNM	Initial Staging(N = 50)		Restaging(N = 50)	
	No.	%	No.	%
T1N0M0	01	02	-	-
T1N1M0	02	04	03	06
T2N0M0	05	10	02	04
T2N1M0	23	46	19	38
T2N1M1	-	-	03	06
T2N2M0	-	-	01	02
T3N1M0	07	14	06	12
T3N1M1	01	02	04	08
T4aN1M0	04	08	02	04
T4aN3M1	-	-	01	02
T4bN1M0	05	10	01	02
T4bN1M1	-	-	05	10
T4bN2M1	-	-	01	02
T4cN2M0	01	02	01	02
T4cN3M0	01	02	-	-
T4cN3M1	-	-	01	02

Table 5: Comparison of change in TNM Staging between Initial and restaging after PET-CT scan

Changes in Staging (N =50)	No.	%
Change	22	44.0
No change	28	56.0

Table 6: Profile of Staging

Stage	Initial Staging (N = 50)		Restaging (N = 50)	
	No.	%	No.	%
IA	01	2.0	-	-
IIA	07	14.0	05	10.0
IIB	23	46.0	19	38.0
IIIA	07	14.0	07	14.0
IIIB	10	20.0	04	8.0
IIIC	01	2.0	-	-
IV	01	2.0	15	30.0

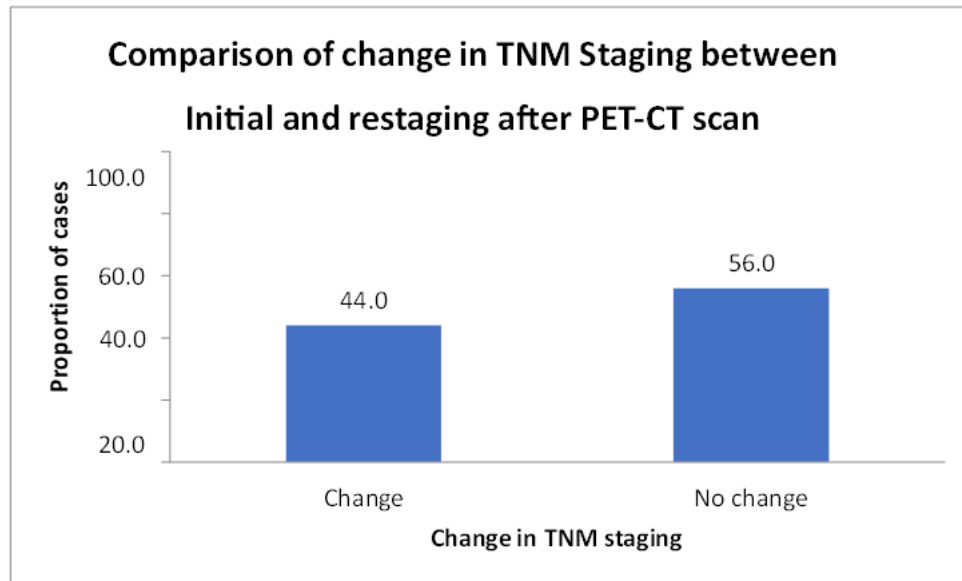


Table 7: Comparison of FDG Uptake

FDG Uptake(N = 50)	PositiveN (%)	NegativeN (%)	P values
At internal mammary lymphnode	07 (14.0)	43 (86.0)	<0.001
At breast mass	50 (100.0)	-	-
At axillary lymph node	46 (92.0)	04 (08.0)	<0.001
At supraclavicular lymph Node	05 (10.0)	45 (90.0)	<0.001
At other sites	13 (26.0)	37 (74.0)	<0.001
Distant Organ involvement	16 (32.0)	34 (68.0)	<0.001

Table 8: Average SUV Max

SUV max	Mean ± SD
SUV max Breast (SUVbt) (N = 50)	08.89 ± 05.80
SUV max ipsilateral axillary lymph node (SUVln) (N = 47)	04.85 ± 03.84

CONCLUSION

PET/CT is a valuable tool to provide information on extra-axillary lymph node involvement, distant metastases and Restaging of Carcinoma breast. In the initial stage assessment, preoperative FDG-PET/CT has a substantial impact on staging and on clinical management and we suggest that PET/CT could be considered in the initial assessment of patients with newly diagnosed early-stage breast cancer.

REFERENCES

[1] WHO. Breast cancer 12July 2023 <https://www.who.int/news-room/fact-sheets/detail/breast-cancer#:~:text=In%202020%2C%20there%20were%202.3,the%20world's%20most%20prevalent%20cancer>. Accessed on 04/01/2024

[2] Mehrgou A, Akouchekian M. The importance of BRCA1 and BRCA2 genes mutations in breast cancer development. Med J Islam Repub Iran 2016;30:369.

[3] Hadebe B, Harry L, Ebrahim T, Pillay V, Vorster M. The Role of PET/CT in Breast Cancer. Diagnostics (Basel) 2023;13(4):597.

[4] Jung NY, Kim SH, Kim SH, Seo YY, Oh JK, Choi HS, et al. Effectiveness of Breast MRI and (18)F-FDG PET/CT for the Preoperative Staging of Invasive Lobular Carcinoma versus Ductal Carcinoma. J Breast Cancer 2015;18(1):63-72.

[5] Dong A, Wang Y, Lu J, Zuo C. Spectrum of the Breast Lesions With Increased 18FFDG Uptake on PET/CT. Clin Nucl Med 2016;41(7):543-57

- [6] Kamal, A.M., Kamal, O.A., Sakr, H.M. et al. Role of 18F-FDG PET/CT in evaluation of recently diagnosed breast cancer patients. *Egypt J Radiol Nucl Med* 2022;53:178.
- [7] Almuhaideb A, Papathanasiou N, Bomanji J. 18F-FDG PET/CT imaging in oncology. *Ann Saudi Med* 2011;31(1):3-13.
- [8] Yararbas U, Avci NC, Yeniay L, Argon AM. The value of 18F-FDG PET/CT imaging in breast cancer staging. *Bosn J Basic Med Sci* 2018;18(1):72-79.
- [9] Bernsdorf M, Berthelsen AK, Wielenga VT, Kroman N, Teilum D, Binderup T, et al. Preoperative PET/CT in early-stage breast cancer. *Annals of Oncology* 2012;23(9):2277-82.
- [10] Caresia Aroztegui AP, García Vicente AM, Alvarez Ruiz S, Delgado Bolton RC, Orcajo Rincon J, Garcia Garzon JR, et al. 18F-FDG PET/CT in breast cancer: Evidence based recommendations in initial staging. *Tumour Biol* 2017;39(10):1010428317728285.
- [11] Jeong YJ, Kang D-Y, Yoon HJ, Son HJ. Additional value of F-18 FDG PET/CT for initial staging in breast cancer with clinically negative axillary nodes. *Breast Cancer Res Treat* 2014;145(1):137-42.