

# Research Journal of Pharmaceutical, Biological and Chemical Sciences

## Prospective Study On Efficacy Of Mastectomy Flap Quilting Sutures In Reducing Post Modified Radical Mastectomy Seroma Formation.

T Bharani Dharan<sup>1\*</sup>, and Umesh Raj<sup>2</sup>.

<sup>1</sup>Assistant Professor, Department Of Surgical Oncology, Government Medical College, Villupuram, Tamil Nadu, India.

<sup>2</sup>Associate Professor, Department Of General Surgery, Melmaruvathur Adiparasakthi Institute Of Medical Sciences & Research, Melmaruvathur, Tamil Nadu, India.

### ABSTRACT

Seroma formation is one of the most common complications post modified radical mastectomy. The incidence documented ranges from 15-81%. Seroma formation increases chances of infection, delays wound healing, flap necrosis, persistent pain, dehiscence of the wound and thus increases the convalescence period. Ideal closure of the Modified radical mastectomy flaps aims at decreasing the lymphatic spillage and serum oozing, should obliterate the dead space and also allow enhanced removal of the fluid which is formed. Considering this, several techniques of flap fixation have been tried and trialed to minimize the local wound complications. The aim of the present study was to study the efficacy of mastectomy flap quilting sutures to the underlying chest wall, on the volume and duration of the fluid drained and also seroma formation posts modified radical mastectomy. In the study group; the mastectomy flap quilting sutures were put between the flap and the pectoral fascia and muscle at different parts of the flap and at the flap edge with absorbable sutures (polyglactin 3-0). In the control group; the flaps were approximated by the conventional method at the edges. Closed suction drains were placed in both the groups. Patients, tumor characteristics and operative related factors were documented. The volume and colour of the fluid drained were recorded every day. The drains were removed when the amount became less than 30 cc in a 24-hour period. The total volume and duration (number of days) of fluid drained and the complications were recorded and compared. In the study group, the drain was removed much earlier when compared to the control group ( $p < 0.001$ ). The total amount of fluid drained was much lower in the study group ( $p < 0.001$ ). The study group showed a much lower frequency of seroma formation when compared to the control group. The mastectomy quilting suture technique is an effective procedure that considerably reduces the incidence of seroma formation in patients undergoing modified radical mastectomy.

**Keywords:** Flap, Mastectomy, Quilting, Seroma.

<https://doi.org/10.33887/rjpbcs/2023.14.3.38>

*\*Corresponding author*

## INTRODUCTION

Seroma formation and its sequelae including infection, flap necrosis, delayed wound healing and patient discomfort form one of most commonly encountered complication following mastectomy and axillary dissection varying in incidence from 3 to 85 % [1]. Seroma formation after breast cancer surgery is a persistent problem much to the annoyance of surgeon and patient alike, in spite of advances in surgical techniques and hemostasis [2]. Pathophysiology of seroma is not clear and it is widely discussed in literature. Seroma is formed by acute inflammatory exudates in response to surgical trauma and acute phase of wound healing or fibrinolytic activity in serum or lymph drainage [3]. Seroma is influenced by large dissection area, dead space under the skin flaps and axillary region, shoulder movement which affects attachment of skin flaps [4]. The incidence of seroma is correlated with obesity, hypertension, breast volume, early shoulder exercise, and use of heparin, tamoxifen [5]. Seroma accumulation elevates the flaps from the chest wall and axilla there by hampering their adherence to the tissue bed. It thus can lead to significant morbidity such as wound hematoma, delayed wound healing, wound infection, wound dehiscence, prolonged hospitalization, delayed recovery and initiation of adjuvant therapy.[6] Number of techniques have been employed in an attempt to reduce or prevent seroma formation among mastectomy patients using mechanical and chemical approaches. However, there is heterogeneity in their benefits and there is paucity of uniform evidence for their use [7]. Mechanical closure of dead space by flap fixation is a simple surgical procedure that eliminates dead space after mastectomy [8]. The objective of this study is to evaluate the effect of mechanical closure of dead space after mastectomy in prevention of seroma formation.

## MATERIALS AND METHODS

This prospective study was carried out in the Department of Surgical Oncology in collaboration with the Department of Pathology, Government Medical College, Villupuram, Tamil Nadu, India in the year November 2018 to August 2019.comprising 80 patients of carcinoma breast over a period of six months.

**Inclusion criteria:** All the patients admitted in general surgical ward, aged more than 18 years with carcinoma breast requiring modified radical mastectomy. Patients consented for inclusion in the study according to the designated proforma.

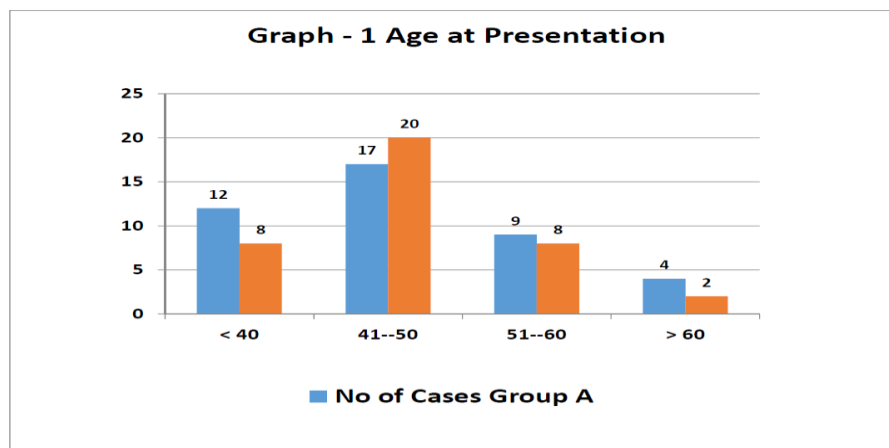
**Exclusion criteria:** Patients with carcinoma breast undergoing breast conservation surgery Patients with carcinoma breast undergoing radiotherapy. Patients with carcinoma breast undergoing modified radical mastectomy after neo-adjuvant chemotherapy. Patients with carcinoma breast undergoing palliative surgery/toilet mastectomy Patients with carcinoma breast undergoing completion mastectomy. The data collected in prescribed Proforma where in it contains, particulars of the patient, clinical history, clinical examination and diagnosis, relevant investigations, and details of surgery. The patients were followed for three weeks in post-operative period, Day 1 drain volume, total drain volume, drain removal day, seroma and wound complication were all recorded.

### Statistical Analysis

In this study, the results of the two groups were compared and analyzed by using Chi-square test.

## RESULTS

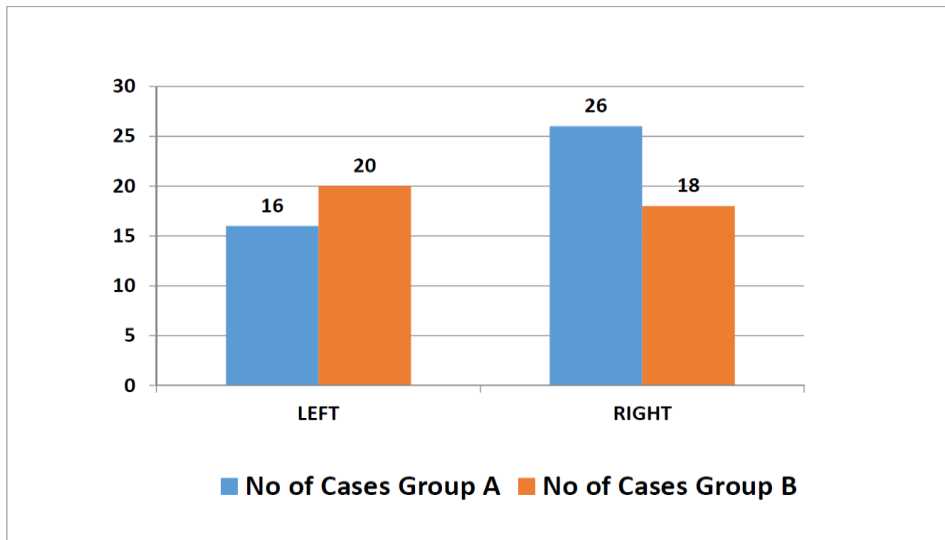
Graph 1: Age at Presentation



In this “Prospective Study on Efficacy of Mastectomy Flap Quilting Sutures in Reducing Post Modified Radical Mastectomy Seroma Formation” Total of 80 patients of Carcinoma Breast who underwent Modified Radical Mastectomy were included in this prospective study, and randomized into two groups based on in-patient number. 42 patients with odd IP no in conventional simple wound closure (Group A) and 38 patients with even IP no in Flap fixation (Group B) were considered for the study.

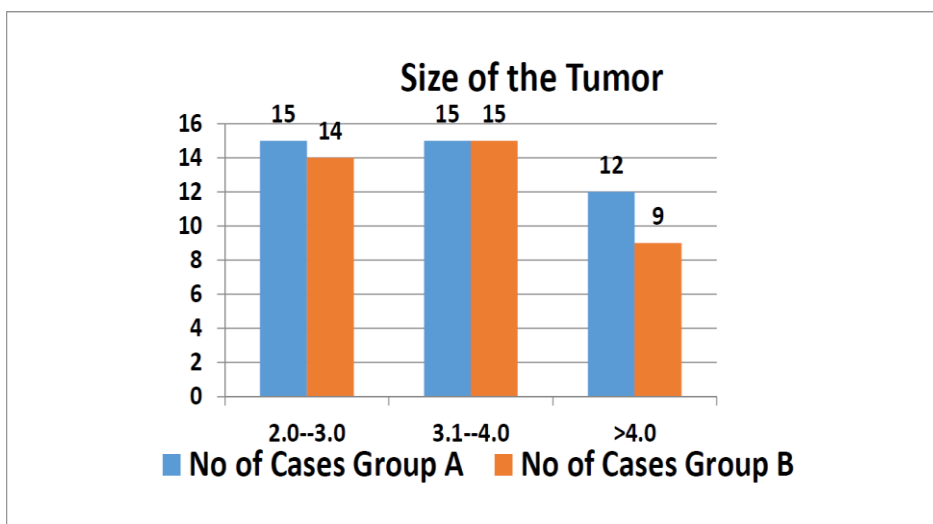
In this study, age of the patients were more than 18 years. The youngest patient included in this study series was 30 years, and the eldest was 69 years old. Almost 46% of the patients were in 41-50 age group. This includes 40% in group A and 52% in group B. Average age in this study series is 47 years.

**Graph 2: Location of Tumor**



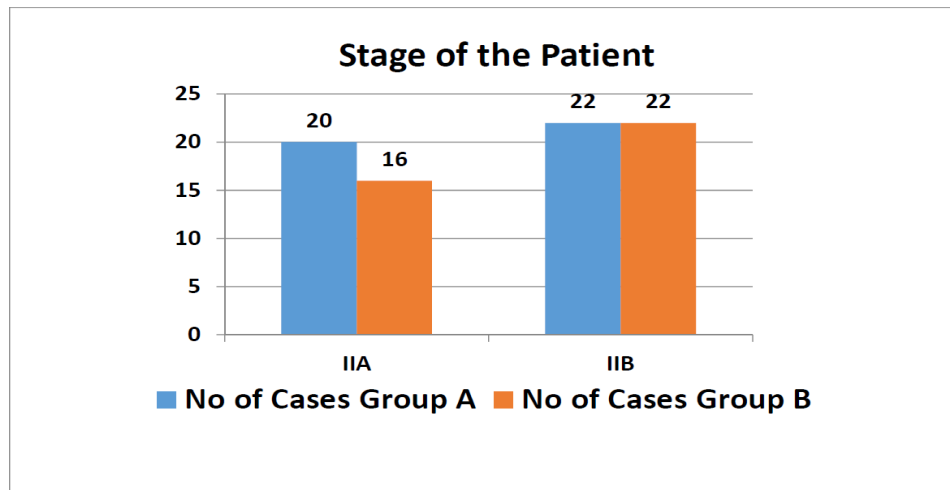
The present study showed that carcinoma affects both side breast equally, with slight preponderance for right side.

**Graph 3: Size of the Tumor**



In the study, the size of tumor at presentation varied from 2cm to 4.8cm with average size being 3.4cm.

**Graph 4: Stage of the Patient**



In the study, 36 women presented with Stage IIA disease and 44 women presented with stage IIB disease.

**Table 1: Comparison of study groups**

Comparison of study groups	Flap Non Fixation Group A (n=42) (%)	Flap Fixation Group B (n=38) (%)
Demography		
Mean Age	48±9	46±7
Location		
Right	26 (62)	18 (47)
Left	16 (38)	20 (52)
Tumor Size		
Mean Tumor Size	3.46	3.43
Stage of the Patient		
IIA	20 (47)	16 (42)
IIB	22 (52)	22 (58)

In the present study, modified radical mastectomy with conventional simple wound closure was performed in 42 women with mean age 48±9 years. Of the 42 women, 26 (62%) had Right sided breast carcinoma and 16 (38%) had left sided breast carcinoma. Average size of the tumor at presentation was 3.46±0.8 cm. Of the 42 women, 20 (47%) women belonged to stage IIA at presentation and 22 (52%) women belonged to stage IIB. Modified radical mastectomy and wound closure with flap fixation was performed in 38 women with mean age 46±7 years. Of the 38 women, 18 (47%) had Right sided breast carcinoma and 20 (52%) had left sided breast carcinoma. Average size of the tumor at presentation was 3.43±0.8 cm. Of the 38 women, 16 (42%) women belonged to stage IIA at presentation and 22 (57%) women belonged to stage IIB.

**Post-Operative Follow Up**

Post-operative drain volume on day 1, total drain volume, day of drain removal, seroma formation and wound complications has been compared between two groups (A&B). The results were compared with p value using Chi Square test.

**Table 2: Day 1 Drain Volume**

Day 1 Drain Volume (ml)	No of Patients		Total
	Group A	Group B	
<100	4	5	9
100-150	7	10	17
>150	31	23	54
Mean Volume (ml)	170.2	163.8	
p' value=0.41 NS			

In the present study, the drain volume in first post-operative day in Group A (Flap Non-Fixation) was compared with Group B (Flap Fixation) after Modified radical mastectomy. Drain volume in first post-operative day varied from 100 to 200ml with average of 170ml in group A and 163ml in group B. There was no statistically significant difference in the drain volume in first post-operative day ( $p > 0.05$ ).

**Table 3: Total Drain Volume**

	Mean Total Volume (ml)	SD
Group A	1426	240
Group B	932	216
p' value<0.001 S		

In the present study, the total drain volume in the post-operative period in Group A was compared with Group B. The average total drain volume in the post-operative period in group A was 1426ml and 932ml in group B. p value was found to be significant ( $< 0.001$ ).

**Table 4: Drain Removal Day**

	Mean Day of Removal	SD
Group A	13	2.3
Group B	8	1.6
p' value<0.001 S		

In the present study, drain removal day in Group A was compared with Group B. The average day of drain removal in group A was 13 days and 8 days in group B. p value was found to be significant ( $< 0.001$ ).

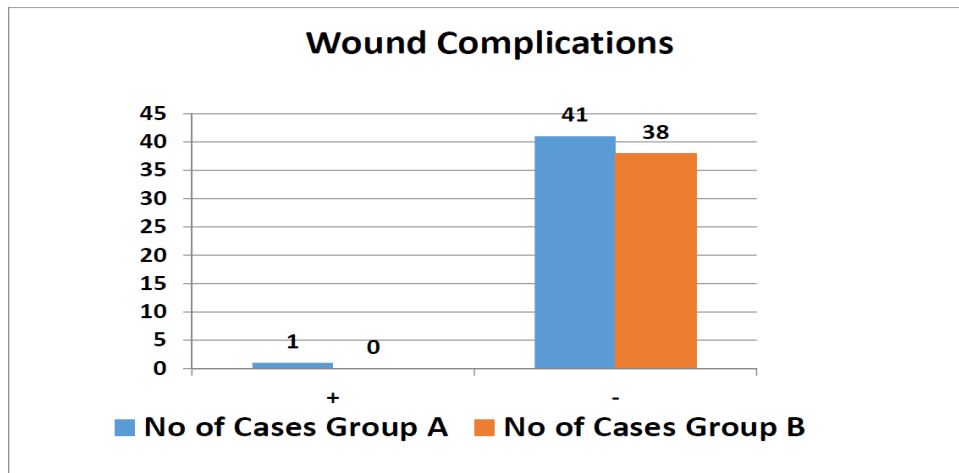
**Table 5: Incidence of Seroma**

Seroma	Group A	Group B	Total
Present	8	0	8
Absent	34	38	72
p' value=0.027 S			

In the present study, the incidence of seroma formation in Group A was compared with Group B. 8 patients developed seroma in group A vs none in group B. p value was found to be significant ( $> 0.05$ ).

In the present study, wound complications in Group A was compared with Group B. One patient developed wound complication (cellulitis) vs none in group B. There was no statistically significant difference in the incidence of wound complications in both groups.

**Graph 5: Incidence of Wound Complications**



**DISCUSSION**

Seroma is a significant problem following axillary dissection for breast cancer, which is now considered as sequelae rather than complication [9]. Mechanical obliteration of dead space by flap fixation in an attempt to reduce incidence of seroma formation has been proposed by many studies with inconsistent results. So the present study was undertaken to evaluate the effect of mechanical obliteration of dead space by flap fixation in reducing incidence of seroma formation. In this study, 80 women with Breast cancer, who underwent modified radical mastectomy, were evaluated for total drain volume, drain removal time, seroma formation and wound complications in two study groups (group A – 42 women, and group B – 38 women). There were no significant differences between the two groups with regard to age, stage, and tumor size. In group A, 42 women who underwent modified radical mastectomy had their wound closed in two layers – subcutaneous tissue with 2/0 vicryl and skin with 2/0 ethilon [10]. In group B, 38 women who underwent modified radical mastectomy had their wound closed by fixation of skin flap to underlying pectoralis major muscle with multiple rows of intermittent 2/0 vicryl followed by skin closure with 2/0 ethilon. In all the patients, 2 14F suction drain were kept in axilla and in front of pectoral muscles. Drain volume on first post-operative day was recorded [11]. Drain was removed when the output was less than 30ml for 24 hours. Total drain volume was recorded. The patients were followed for three weeks. The patients who developed seroma by clinical examination were recorded. Wound was observed for any complications like infection, cellulitis, and necrosis [12]. Our mean number of days for drain removal was 8 days in the flap-fixation group versus 13 days in the no-flap-fixation group; this disagrees. In the present study, we found that the flap-fixation technique significantly decreased the total amount of fluid drained ( $P < 0.001$ ; highly significant) [13]. The mean amount of serous fluid drained was 932 ml in the flap-fixation group versus 1426 ml in the no-flap-fixation group, whereas the mean amount of serous fluid drained was 262.2 ml in the flap-fixation group versus 763.5 ml. The overall clinical incidence of seroma in the whole study was about 10% (8/80). Our study showed that the flap-fixation technique was associated with no incidence of clinically symptomatic seroma (0%) after mastectomy, as compared with the control group (19%), with P value less than 0.001, which was highly significant [14]. In our study, one patient’s developed cellulitis in the no flap-fixation technique vs none in flap fixation technique, which was treated medically and improved later on. probably by decreasing movement of flap over the chest wall and thereby reducing the exudate [15].

**CONCLUSION**

The present prospective study demonstrated that the mechanical obliteration of dead space by flap fixation significantly decreases the incidence of seroma formation. However, the sample size in the current study is relatively smaller, so a larger study sample may be needed before any further conclusion can be made. Although the study sample is small in this present study, it is still wise to recommend mechanical obliteration of dead space by flap fixation in patients undergoing modified radical mastectomy. So when performing modified radical mastectomy, the flap-fixation technique is a valuable technique for reducing seroma formation allowing early drain removal and increased patient satisfaction.

**REFERENCES**

- [1] Kumar S, Lal B, Misra MC. Post-mastectomy seroma: a new look into the aetiology of an old problem. *J R Coll Surg Edinb* 1995; 40:292– 294.
- [2] Bryant M, Baum M. Postoperative seroma following mastectomy and axillary dissection. *Br J Surg* 1987; 74:1187
- [3] Willett WC, Rockhill B, Hankinson SE, Hunter DJ, Colditz GA. Epidemiology and nongenetic causes of breast cancer. In: Harris JR, Lippman ME, Morrow M, Osborne CK, editors. *Diseases of the Breast*. 2nd ed. Philadelphia: Lippincott Williams & Wilkins; 2000. pp. 175– 220.
- [4] Watt-Boolsen S, Nielsen VB, Jensen J, Bak S. Postmastectomy seroma. A study of the nature and origin of seroma after mastectomy. *Dan Med Bull* 1989;36:487–489.
- [5] Oertli D, Laffer U, Haberthuer F, Kreuter U, Harder F. Perioperative and postoperative tranexamic acid reduces the local wound complication rate after surgery for breast cancer. *Br J Surg* 1994;81:856–859.
- [6] Fischer's mastery of Surgery, sixth edition, Lippincott Williams & Wilkins, 2012.
- [7] Halsted WS. The results of operations for the cure of cancer of the breast performed at the Johns Hopkins Hospital from June 1889 to January 1894. *Arch Surg* 1894; 20:497.
- [8] Meyer W. An improved method for the radical operation for carcinoma of the breast. *Med Rec NY* 1894; 46:746.
- [9] Bland KI, Chang HR, Prati R, et al. Modified radical mastectomy and total (simple) mastectomy. In: Bland KI, Copeland EM, eds. *The Breast: Comprehensive Management of Benign and Malignant Diseases*.
- [10] Bland KI, Menck HR, Scott-Conner CE, et al. The National Cancer Data Base 10-year survey of breast carcinoma treatment at hospitals in the United States. *Cancer* 1998;83(6):1262-73.
- [11] Nahabedian, Maurice. Oncoplastic surgery of the breast 618.1'90592
- [12] Fisher B, Anderson S, Bryant J, et al. Twenty-year follow-up of a randomized trial comparing total mastectomy, lumpectomy, and lumpectomy plus irradiation for the treatment of invasive breast cancer. *N Engl J Med* 2002;347: 1233–1241.
- [13] Veronesi U, Cascinelli N, Mariani L, et al. Twenty-year follow-up of a randomized study comparing breast-conserving surgery with radical mastectomy for early breast cancer. *N Engl J Med* 2002; 347:1227– 1232.
- [14] Anderson SJ, Wapnir I, Dignam JJ, et al. Prognosis after ipsilateral breast tumor recurrence and locoregional recurrences in patients treated by breast conserving therapy in five National Surgical Adjuvant Breast and Bowel Project protocols of node-negative breast cancer. *J Clin Oncol* 2009;27: 2466–24.
- [15] Gabka CJ, Maiwald G, baumeister RG. Expanding the indications spectrum for breast saving therapy of breast carcinoma by oncoplastic operations. *Langenbecks Arch Chir suppl Kongressbd* 1997; 114:1224–1227.