

# Research Journal of Pharmaceutical, Biological and Chemical Sciences

## Multi Ligamentous Knee Reconstruction Outcome Analysis Following Staged Reconstruction.

K Senthilkumar<sup>1\*</sup>, M Dhanagopal<sup>2</sup>, and A Siva Senthil<sup>3</sup>.

<sup>1</sup>Dept of Orthopaedics, Thanjavur Medical college Hospital Thanjavur, Tamil Nadu, India

<sup>2</sup>Dept of Orthopaedics, Thanjavur Medical college Hospital Thanjavur, Tamil Nadu, India

<sup>3</sup>Dept of Orthopaedics, Thanjavur Medical college Hospital Thanjavur, Tamil Nadu, India

### ABSTRACT

Multiligament knee injury (MLKI) is a complex orthopedic knee injury leading to the tear of at least two cruciate or one cruciate and one collateral ligaments of knee.

**Keywords:** MLKI, Staged repair, outcome, complications.

<https://doi.org/10.33887/rjpbcs/2023.14.2.6>

*\*Corresponding author*

**INTRODUCTION**

Multi ligamentous knee injury is a complex orthopaedic injury occurring as a result of traumatic knee dislocation. The MLKI is referred to the tear of at least two of the four major knee ligaments, including anterior cruciate ligament (ACL), posterior cruciate ligament (PCL), posteromedial corner including the medial collateral ligament (MCL), and posterolateral corner (PLC) including the lateral collateral ligament (LCL) [1]. This may be further associated with neurovascular compromise as a result of posterior knee dislocation leading to loss of limb if left unnoticed. 18 % of MLKI is associated with vascular injuries [2]. Hence careful examination of the distal vascularity and neurological status on presentation is mandatory to prevent such disasters. The present study was conducted to report the outcomes of staged multiligament reconstruction surgery using functional Lysholm knee score.

**MATERIALS AND METHODS**

This prospective study was carried out in the Department of Orthopaedics, Medical college hospital Thanjavur, India from September 2021 to November 2022. In the study, 10 patients with multiligamentous knee injuries were included and patients with isolated cruciate and meniscal injuries were excluded. All patients were evaluated clinically and radiologically using plain radiographs to find any bony avulsion fractures , stress views [3] were taken to get an insight on ligament status and proceeded with MRI of the involved knee to know about the ligaments involved and grade of tear. There were 7 males and 3 females in the study. All patients were treated by repair/reconstruction of the torn collateral ligaments by open and cruciate ligaments reconstructed by arthroscopic methods.

**Table 1: Mode of injury**

Mode of injury	Number of patients(%)
RTA	7(70%)
Sports injury	3(30%)

**Table 2: Gender distribution**

Gender	Number of patients(%)
Male	7(70%)
Female	3(30%)

**Table 3: Shenck classification [4]**

Types	Ligaments involved
KD- 1	Either of two cruciates (ACL/PCL)
KD - 2	Two cruciates (ACL & PCL)
KD - 3M	Two cruciates with MCL
KD - 3L	Two cruciates with LCL
KD - 4	Two cruciates & Two collaterals with PLC
KD - 5	Pan ligament with peri articular #

**Table 4: Graft options**

Semitendinosis
Gracilis
Bone patellar tendon bone
Peroneous longus

**Surgical Methods**

Patients were taken up for surgery after anaesthetic fitness under spinal anaesthesia with pre-op IV antibiotics 30 mins before tourniquet inflation. Average time duration between injury to 1<sup>st</sup> stage of

surgery was 6 days and time to next stage was 2 weeks once the soft tissue injury heals. Average tourniquet time was 1 hour 45 minutes.

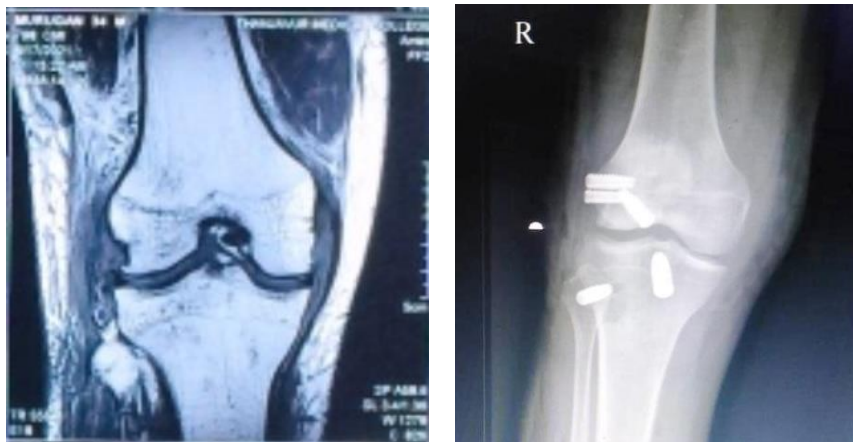Graft selection can be challenging in multiligament knee reconstruction. Surgeons have the option of using autograft, allograft or synthetic graft. Each of these options has its advantages and disadvantages. The decision [5] on graft choice usually depends on the number of ligaments requiring reconstruction/augmentation, graft availability, surgeon preference and the chosen surgical technique for reconstruction [6]. In our study we harvested Semi-T and Gracilis for collateral ligament injuries and BTB/Peroneus longus for cruciate reconstruction fixed with interference screws. In one case we repaired MCL & LCL using 3mm anchor with fiber wire.

Post operatively patients were assessed for distal pulse and any neurological deficits. IV antibiotics were continued for 48 hours and all patients were put on thrombo-embolic prophylaxis in the post operative period. Post operative assessment with plain radiographs and Lysholm score and was done.

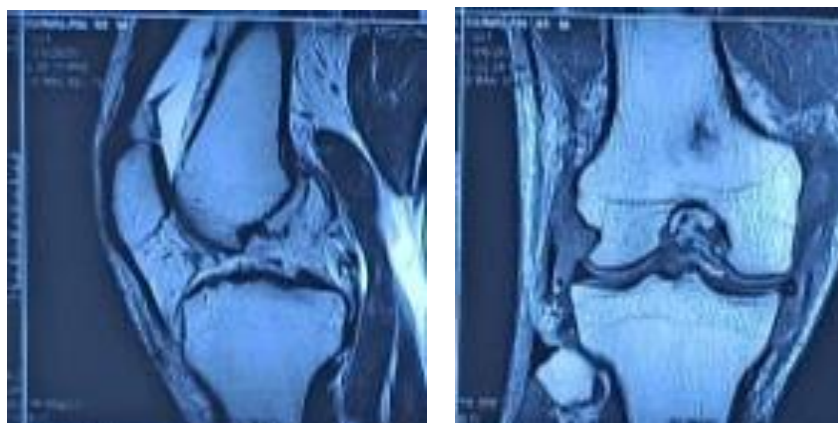
### RESULTS

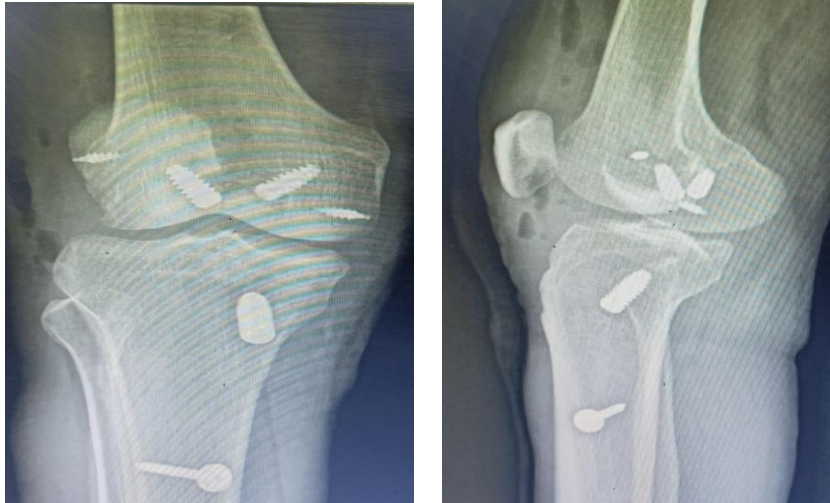Patients who underwent collateral ligament repair/reconstruction were mobilized with knee brace from the 3<sup>rd</sup> post operative day and range of motion was started after two weeks , followed by cruciate reconstruction and further regaining of range of movements was advised . Patients were followed up at monthly interval for a minimum duration of 3 months and maximum of 6 months with clinical assessment using Lysholm knee score and mean score was found to be 72% [7]. Out of 10 patients 6 patients regained 100 degrees of ROM, 2 patients had 80 degrees of knee ROM and remaining 2 patients had 70 degrees.

#### Case 1: KD-3L

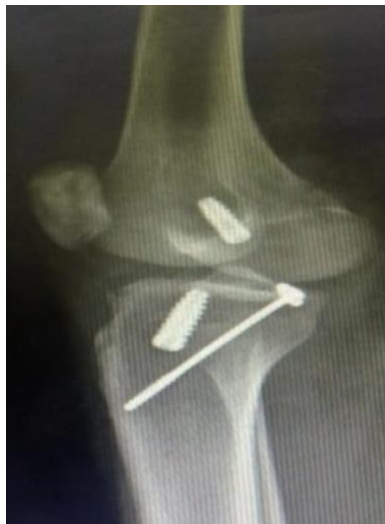
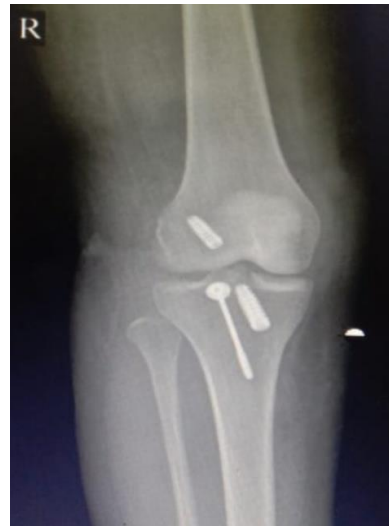
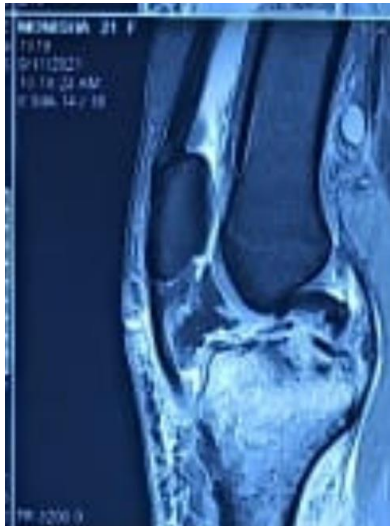#### Case 2: KD- III





Case 3: KD - II



## DISCUSSION

In our study staged multiligament reconstruction gives good results with mean Lysholm score of 72%. Staged reconstruction has the advantage of allowing the lesser degrees of collateral injuries to heal on its own thus avoiding the surgical repair or reconstruction. In our study we preferred staged reconstruction of the cruciates as collateral ligaments were addressed immediately as it needs immobilization for a shorter period of time to allow the soft tissues to heal. The cruciates were reconstructed once the knee range of motion of about 110 – 120 degrees was achieved. In one case we had a common peroneal nerve neuropraxia which recovered as early [8] as at 3 months till then foot drop splint was given.

## CONCLUSION

Multiligament knee injuries are complex and devastating which requires careful clinical assessment and radiographic imaging methods for accurate diagnosis and pre-operative planning so that patient will have a stable knee with good functional range of movements to return to his daily activities as early as possible. Staged reconstruction has the advantage of better ROM of knee, avoiding unnecessary repair or reconstruction of lesser degrees of collateral injuries to heal on its own thus avoiding arthrofibrosis if done in a single stage surgery.

## REFERENCES

- [1] Jack Porrino MD , Annie Wang MD , Kimia Kani MD ,Christopher Y Kweon MD , Albert Gee MD doi: <https://doi.org/10.1067/j.cpradiol.2019.02.004>
- [2] Manske RC, Hosseinzadeh P, Giangarra CE. Multiple ligament knee injury: complications. *N Am J Sports Phys Ther.* 2008; 3(4):226-33.
- [3] James EW, Williams BT, LaPrade RF. Stress radiography for the diagnosis of knee ligament injuries: a systematic review. *Clin Orthop Relat Res.* 2014; 472(9):2644-57.
- [4] Schenck rC. Classification of knee dislocations. In: Fanelli GC, ed. *The multiple ligament injured knee: a practical guide to management.* New York, NY: Springer, 2004:37–49.
- [5] Levy BA, Dajani KA, Whelan DB, Stannard JP, Fanelli GC, Stuart MJ, et al. Decision making in the multiligament injured knee: an evidence-based systematic review. *Arthroscopy.* 2009; 25(4):430-8
- [6] Levy BA, Dajani KA, Whelan DB, Stannard JP, Fanelli GC, Stuart MJ, et al. Decision making in the multiligament injured knee: an evidence-based systematic review. *Arthroscopy.* 2009; 25(4):430-8.
- [7] Fanelli GC, Orcutt DR, Edson CJ. The multiple-ligament injured knee: evaluation, treatment, and results. *Arthroscopy.* 2005; 21(4):471-86.
- [8] EFORT Open Rev 2020;5:145-155.DOI: 10.1302/2058-5241.5.190012