

Research Journal of Pharmaceutical, Biological and Chemical Sciences

Evaluation Of Liver Fibrosis In Liver Biopsy Of Alcoholic Liver Disease Cases, With Reticulin Stain And CD31 Immunostain.

Narmatha M¹, and A Abu Arshad^{2*}.

¹Assistant Professor, Department of Pathology, Government KAPV Medical College, Tiruchirappalli. Tamil Nadu, India.

²Assistant Professor, Department of Pathology, Government Mohan Kumaramangalam Medical College, Salem. Tamil Nadu, India.

ABSTRACT

Alcoholic liver disease (ALD) remains a major cause of morbidity and mortality world - wide. Liver biopsy is the gold standard method to assess the presence of liver fibrosis , and is useful in determining the staging and severity of hepatic injury. To interpret Liver fibrosis in liver biopsies, Reticulin stain, and CD31, an immunohistochemical marker, which plays an important role in determining the degree of fibrosis in Alcoholic liver disease, were used in the evaluation of it. The aim of our study is to evaluate liver fibrosis, with Reticulin stain and to correlate the staging of Liver fibrosis with CD 31, obtained from the biopsy studied in Alcoholic Liver Disease (ALD) patients. Here, we evaluated the fibrotic stage with the help of Reticulin staining , and correlated the expression of CD31 with that of the fibrotic stage. 50 Alcoholic Liver Disease patients, were evaluated for Liver fibrosis, with H&E stain and Reticulin stain, and were correlated with the staging of Liver fibrosis with CD 31 immunostaining expression by statistical analysis. Strong positive correlation with CD31 and Reticulin staining was seen among 34 cases (68%), moderate positive correlation in 8 cases (16%), mild positive correlation in 2 cases (4%), negative correlation in 6 cases (12%). The existence of strong correlation, between CD31 immunostaining and fibrosis seen with Reticulin stain, revealed that the immunohistochemical methods are very much applicable in assessing prognostic and therapeutic strategies.

Keywords: Liver Fibrosis, Reticulin stain, CD31.

<https://doi.org/10.33887/rjpbcs/2022.13.4.21>

**Corresponding author*

INTRODUCTION

Alcoholic liver disease (ALD) remains a major cause of morbidity and mortality world - wide. According to WHO, Alcoholic Liver Disease (ALD), accounts for about 3.8 % of deaths (2.5 million) and 9.2 % of disability adjusted life years (DALYs) [1]. The incidence of liver cirrhosis due to excessive alcohol abuse in Alcoholic Liver Disease (ALD) is approximately 20– 25 % .The continuous use of alcohol consumption of > 40 g / day will increase the risk of progression of fibrosis or cirrhosis to 37% [2, 3]. The most important predisposing factor for causing serious liver disease, depends on the duration, type and amount of alcohol consumption. Alcoholic Liver Disease (ALD) comprises a spectrum of morphological features which includes steatosis ,chronic hepatitis , perivenular fibrosis and frank cirrhosis. Liver fibrosis occurs as a result of imbalance between degradation of extracellular matrix (ECM) compounds and synthesis of collagen [4, 5]. The ECM is the main functional support of the parenchyma.If liver injury persists, due to oxidative stress, hepatic stellate cell gets activated , induces an inflammatory response, resulting in failure of liver regeneration and production of abundant fibrillary collagen [6].

Liver biopsy is the gold standard method to assess the presence of fibrosis , etiological factors , and is useful in determining the staging plus severity of hepatic injury and evaluating the therapeutic response. Even in high-risk patients, it may be done successfully through transjugular approach [7]. To interpret liver biopsies, many histochemical stains have been proposed, of which, Reticulin stain, is the most appropriate one to assess fibrosis. Silver impregnation by Gordon and Sweet method, highlights the ECM components from Disse's space and centrilobular venules [8]. Studies showed that Reticulin stain is very helpful in demonstrating the architecture of the liver, which highlights type III collagen fibres, hepatocyte cord thickness and integrity of the reticulin framework. The next step in confirming diagnosis and staging of liver fibrosis are the immunohistochemical methods. Several studies have shown that CD31, a 130 kDa transmembrane glycoprotein also designated as PECAM-1(platelet endothelial cell adhesion molecule) plays an important role in determining the degree of vascular distribution in chronic alcoholic hepatitis ,transmigration of inflammatory cells during inflammation and proves that its positivity increases with the progression of fibrosis [9-20].

MATERIALS AND METHODS

This prospective study was conducted in 50 Alcoholic liver disease (ALD) patients. The age group of the patients ranges from 49 -65 years with a median age of 55 years at the time of presentation. They had a clinical history of right hypochondrial pain for a period of 3-5 months up to 1year, along with abdominal distension and vomiting in some of them. Clinically and radiologically, hepatomegaly was found in all of them. Laboratory studies such as Complete Blood Count, Random Blood Sugar, Coagulation profile, Liver Function Tests, and Platelet count, all were within normal limits. After undergoing Liver biopsy, all patients were normal with no evidence of complications. Ethical committee clearance was also obtained.

Inclusion criteria

- Age from 46 to 65 years.
- Patients with Alcoholic Liver Disease diagnosed by histopathological study.

Exclusion criteria

- Primary liver disorders of nonalcoholic aetiology
- Non-Neoplastic diseases of liver due to viral etiology.

Histopathological examination

All formalin fixed, Liver Biopsy specimens were processed using automatic tissue processor. Hematoxylin & Eosin stained biopsy sections, were reviewed and evaluated for the presence of fibrosis, with respect to stages of it, Minimal (F1), Moderate (F2), Marked (F3), Cirrhosis (F4) as per the revised Ishak and Knodell scoring system. Gordon and Sweet's Reticulin stain, were done for all the cases, and graded 1+ to 4+, and correlated accordingly with the F grade (F1 TO F4). Immunohistochemistry with CD31 was performed for all the cases, and as per the system developed by Scmitt-Graff et al [23] , the number of +ve CD31 Endothelial Cells, were scored in each biopsy in 3 different fields i.e., zone 1, 2 & 3. It is as follows. Score 0 = Negative (no staining), 1+ is the staining of few blood vessels with 2-10% of the Sinusoidal

Endothelial Cells (SEC), 2+ is the staining of atleast 25 -50% of the vasculature with 11 -30% of Sinusoidal Endothelial Cells (SEC), 3+ is the staining of highly vascularised area with more than 30% of Sinusoidal Endothelial Cells (SEC).

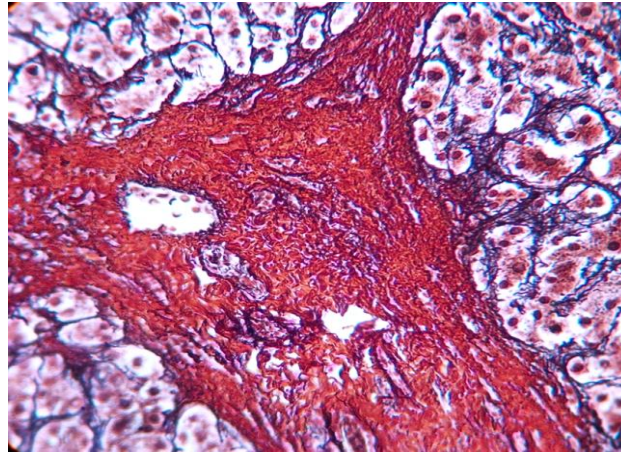


Figure 1: Reticulin stain, displaying the intense Periportal fibrosis with adjacent liver parenchyma highlighting two cell thick plates identified by brownish black colour under 40x.

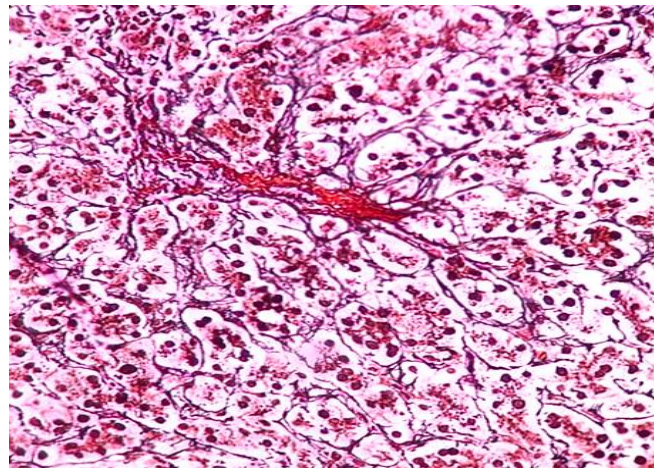


Figure 2: Reticulin stain, displaying the pericellular and sinusoidal fibrosis with steatosis and few degenerated hepatocytes.40x

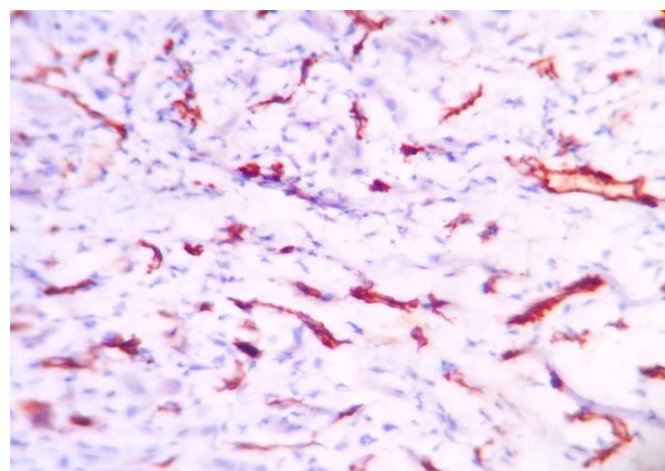


Figure 3: Shows CD 31- Score 2+ . Note the increase in the intensity of staining of blood vessels and sinusoidal endothelial cells.40x

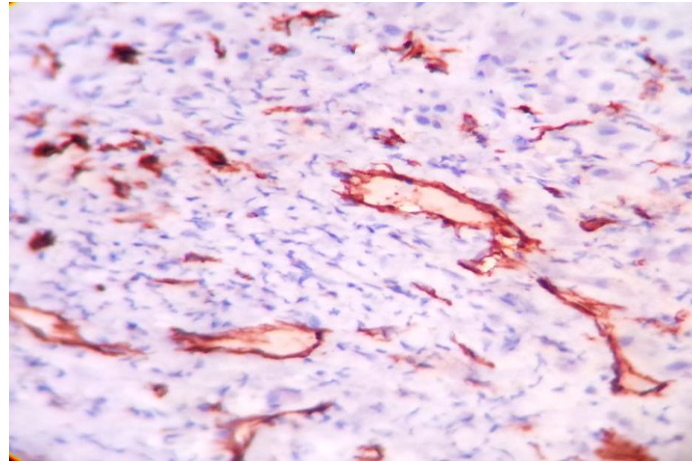


Figure 4: Shows CD 31- Score 3+, marked expression of staining of blood vessels as well as increased microvasculature.40x

Statistical Analysis

The collected data was statistically analysed, and the correlation between Reticulin staining pattern, and CD31 expression in the sinusoidal endothelial cells were studied. ‘p’ values of less than 0.05 were considered significant, and Pearson correlation of co-efficient (‘r’ values) were taken into consideration.

RESULTS

As per the revised Ishak and Knodell scoring system [21 - 24], they are graded as F1, F2, F3 & F4 . It was correlated it with that of the histopathological picture and fibrotic stage which is shown in Table.1

Table 1: Correlation Of Histopathology With The Fibrotic Stage:

HPE Diagnosis	Stage	Number Of Patients
Minimal Fibrosis	F1	8 (16%)
Moderate Fibrosis	F2	21(42%)
Marked Fibrosis	F3	17(34%)
Cirrhosis	F4	4(8%)
Total		50

Most cases were seen in F2 and F3 stage, showing the increased activity of the disease, with F stage progression. Statistical analysis showed , ‘p’ value = 0.04961 (p < 0.05), indicating a significance between the number of patients with histopathological change and F Staging.

On evaluating the F stage with that of the Reticulin score. Type 3 collagen was found not only in the portal , periportal areas, but also in the space of Disse, sinusoidal wall and around the terminal hepatic venules, mainly in the zone 3 . It showed, that the F stage was directly proportional to the score of Reticulin , with focal to diffuse intensity of the staining, which is shown in Table 2. On assessing the ‘p’ value, it was clear that there was a strong evidence of correlation between the Reticulin and F staging, ‘p’ value = 0.046192 (p <0.05).

Table 2: Correlation Between Reticulin And F Staging

No. Of Patients	Reticulin Score	F Stage
8	1+	F1
21	2+	F2
17	3+	F3
4	4+	F4
Total 50		

Immunostaining of sinusoidal endothelial cells was determined by CD31, as shown in Table-3.

Table 3: Number Of CD31 Positive Cases:

CD31 Positivity	No. Of Biopsies
Negative	6
Mildly positive	2
Moderately positive	8
Strongly positive	34
TOTAL	50

The results showed maximum positivity occurred in zone 3. With this data, the F stage was compared with the CD31 positivity and scoring. This detects the activity of the disease. It is estimated that the rates of positively stained CD31 cases, were high with the progression of fibrosis. Also, the percentage of CD 31 positive cells, was calculated by counting the number of cells in 3 different fields of Liver biopsy, and estimating the mean of all 3 values. It was seen in 20% of positive cells in F1, 51% in F2, 76% in F3 and 78% in F4 stages.

Table 4: Number Of CD31 Positive Cells In F Stage.

CD31 Positive Cells	F1	F2	F3	F4
Percentage	20%	51%	76%	78%

Reticulin with CD 31 staining patterns were compared, and it was observed, that cases with 1+ Reticulin score (RS) showed negative correlation with CD31 positivity, out of which only 2 cases coincided with focal positivity, whereas 8 cases of 2+ Reticulin score coincided with moderate positivity, 13 cases of 2+ score, 17 cases of 3+ score, and 4 of 4+ score, highly coincided with intense CD31 positivity. This showed there exists a direct strong relationship between these two stains, as seen in Table -5. Both the p value ($p < 0.05$) and 'r' value were found to be significant and confirmed that angiogenesis is directly proportional to the fibrosis and reticulin.

Table 5: Correlation Of Reticulin With CD31

Reticulin Score With CD31 Positivity						
	0	1+	2+	3+	4+	TOTAL
Negative	6	0	0	0	0	6(12%)
Mild	0	2	0	0	0	2(4%)
Moderate	0	0	8	13	0	8(16%)
Strong	0	0	0	17	4	34(68%)
Total						50

'p' value = 0.04286 ($p < 0.05$) was significant, 'r' value using Pearson correlation co-efficient = 0.9976 was highly correlated between both the stains.

On correlating the F Stage with Reticulin and F Stage with CD 31 as shown in Table -6, it did prove that intensity of CD 31 staining increases, due to high vessel density and Endothelial cells, as the degree of fibrosis increases, 'p' and 'r' value showed direct correlation, which was significant. Pearson's Correlation co-efficient was ('r' value) = 0.9936.

Table 6

Fibrosis With CD31 Positivity	Fibrosis With Reticulin
2	8
8	17
30	21
4	4

DISCUSSION

Reticulin silver stain and Masson Trichrome stain, are commonly used to assess fibrosis. There are two types of Reticulin stain – Gordon & Sweet's stain and Gomori's stain. It stains, the type 3 collagen fibres black in a light pink background. Reticulin fibres are nothing but collagen type 3 and it forms the delicate framework of the stroma in many organs particularly in the liver. Thus this stain highlights clearly the liver microarchitecture [24]. In liver injury, the hepatocytes undergo necrosis with focal cell loss, collapse and condensation of the reticulin framework. In case of regeneration, it stains 2-3 cell thick. Our study showed perivenular and perisinusoidal fibrosis of about 80% in Liver Biopsies of Alcoholic Liver Disease, in which, the site of injury is endothelial cells [25]. The intensity of reticulin stain is directly proportional to the amount of fibrosis. It also gave a clue to the extent of fibrosis. The most commonly used staging and grading systems in various clinical trials are Knodell, Metavir, and Ishak system. They have very minimal interobserver variation. In our study, we noted that the results with maximum biopsies were in F2 and F3 stage i.e., bridging type of fibrosis of porto-central and porto-portal, and incomplete nodules. As described previously, angiogenesis i.e., formation of new blood vessels increases during the course of fibrosis by Hepatic stem cells, in damaged liver, with release of growth factors and profibrotic agents like VEGF, Fibronectin and TGF- β . This is best visualized by CD31 immunostaining. It also quantitatively estimates the microvessel density. In acute and chronic liver injury, the role of CD31 is found to be downregulated. In a study done by Asanza et al., 1997 [26]; he reveals that its expression is absent in the biliary epithelium, lymphocytes and periportal areas, but highly positive in portal vessels, perivenules or zone 3 and ECs of the sinusoids even in chronic hepatic injury, a similar finding emphasized in studies done by Garcia et al., 1998 [27]; Chosay et al., 1998 [9]; and Neubauer et al., 2008 [28]; They also suggested that CD31 is important in transmigration of leucocytes and inflammatory cells. The capillarization in sinusoids, is accompanied by the structural changes in endothelial cells. This is easily scored from 0 to 3 which ranges from absence of microvessels (0) to a highly vascularised tissue (3+). It grades the disease activity. As the disease progresses, vasculature or microvessel proliferation increases and both angiogenesis and fibrosis goes hand in hand. Scoazec & Feldmann., 1991; in their study showed that CD 31 distribution in murine liver is the same as in human liver [29]. It shows a parallel increase in the number of blood vessels and capillaries suggesting that they are hypoxic due to insufficient nutrient supply to them.

Our study showed, strong positivity of CD31 in about 68% (3+) of Liver biopsy samples, moderate positivity in 16% (2+), focal positivity in 4% (1+) and totally negative in 12%, in the same regions. This when correlated with the F stage, it was found, that the intensity and rates of CD31 positive cases, was very high in fibrotic and cirrhotic stages, whereas in NAFLD, steatosis was the predominant manifestation, when compared to fibrosis. Surprisingly CD31 expression was found to be very high. CD31 with 3+ score is detected in 100% of all cases and were in F3 & F4 stages, with more than half of cases in F2 stage 64%. 2+ score was found in approximately of about 36% in F2 and 25% in F1 stages. Also total number of CD31 positive cells are high in F3 and F4 stages (76% & 78% respectively). Studies illustrated that this CD 31 marker can be used for prognosis, since it has got an increased propensity of expressiveness from fibrosis to Hepatocellular carcinoma. It is used as an indirect tumor marker and has a prognostic value. So as the results showed, that both, Reticulin fibrosis and CD 31, were strongly correlated ($p < 0.05$), this can be considered as a prognostic indicator in chronic liver disease. If the end point is fibrosis, it must be assessed accurately and reliably with the help of adequate Liver biopsy samples. Our opinion about Reticulin stain is, that it was found to be very sensitive in detecting the fibrosis, and CD 31, was a good marker in identifying patients at risk of progression of stage, and can be used in prognostic strategies and provide proper treatment to the patient.

CONCLUSION

Histological assessment of Liver Biopsies by Reticulin staining, assessing degree of fibrosis with appropriate scoring system, and evaluating the density of microvessels by CD31, and its strong correlation with Reticulin staining pattern, are of important diagnostic, therapeutic and prognostic value in Alcoholic Liver Disease.

REFERENCES

- [1] World Health Organization. Global Status Report on Alcohol and Health. Geneva, Switzerland: World Health Organization; 2011.

- [2] Yoon Y-H, Yi HY. Liver Cirrhosis Mortality in the United States 1970-2007. Bethesda, MD: National Institute on Alcohol and Alcoholism; 2010.
- [3] Teli MR, Day CP, Burt KD, Bennett MK, James OF. Determinants of progression to cirrhosis or fibrosis in pure alcoholic fatty liver. *Lancet* 1995; 346:987-990.
- [4] Becker U, Gronbaek M, Johansen D, Sorensen TI. Lower risk for alcohol induced cirrhosis in wine drinkers. *Hepatology* 2002;35 868-875
- [5] Wang LT, Zhang B, Chen JJ. Effect of anti-fibrosis compound on collagen expression of hepatic cells in experimental liver fibrosis of rats. *World Journal Gastroenterology* 2000;6(6):877-880.
- [6] Bataller R & Brenner DA. Liver fibrosis. *Journal of Clinical Investigation* 2005; 115:209-218.
- [7] Trejo R, Alvarez W, Garcia - Pagan JC. The applicability and diagnostic effectiveness of transjugular liver biopsy. [Article in Spanish.] *Med Clin (Barc)* 1996;107:521-3.
- [8] Cornianu M, Lazar E, Dema A, Taban S, Lazar D. 2007. Interpretarea biopsiei hepatice, Edit. Eurobit, ISBN 978-973-620-335-0, Timisoara, Romania.
- [9] Chosay JG, et al. Role of PECAM-1 (CD31) in neutrophil transmigration in murine models of liver and peritoneal inflammation. *American Journal Physiology Gastrointestinal Liver Physiology*, 1998;274:776-782,.
- [10] Matsumara T, Wol K, Petzelbauer P. *Journal of immunology* 1997;158:3408-3416.
- [11] Kiernan F. The anatomy and physiology of the liver. *Philos Trans R Soc Lond* 1833; 123: 711-770.
- [12] Rappaport AM, Borowy ZJ, Loughheed WM, Lotto WN. Subdivision of hexagonal liver lobules into a structural and functional unit. Role in hepatic physiology and pathology. *Anat Rec* 1954; 119: 11- 34.
- [13] Philips MJ, Satir P. The cytoskeleton of the hepatocyte organization, relationships and pathology. In : Arias IM, Jakoby WB, Popper H, Schacter D, Shafritz DA. eds *The liver: biology and pathobiology*. New York: Raven Press, 1988: pp 11- 27.
- [14] Mac Donald RA. Life span of liver cells, *Arch Int Med* 1981;10:335- 343.
- [15] Chen TS, Chen PS. *Understanding the liver*. Greenwood press: Westport, 1984.
- [16] Silverman I. A new biopsy needle. *Am J Surg* 1938; 40 : 671-672
- [17] Menghini G. One -second needle biopsy of the liver. *Gastroenterology* 1958;35:190-199
- [18] Hegarty JE, Williams R. Liver biopsy: techniques, clinical applications and complications, *Br Med J* 1984;288:1254-1256.
- [19] Bancroft JP, Stevens A, eds. *Theory and practice of Histological techniques*, 4th edn. Edinburgh: Churchill Livingstone, 1996.
- [20] Proplet EB, Mills B, Arington JB, Sobin LH, eds. *Laboratory methods in Histotechnology*. Washington, DC: American Registry of Pathology 1992.
- [21] Pusztaszeri MP, Saelantaz W, Fred T Bosmon. Immunohistochemical Expression of Endothelial Markers CD31, CD34, Von Willibrand Factor, and Fli-1 in Normal Human Tissues *Journal of Histochemistry & Cytochemistry* 2006;54(4):385-395.
- [22] Wu GD, Shintaku IP, Chien K, Galler SA. A comparison of routine light microscopy immunohistochemistry, and in situ hybridization, for the detection of cytomegalo virus in gastrointestinal biopsies. *Am J Gastroenterol* 1989;84:1517-1520.
- [23] Ishak KM. Pathologic features of chronic Hepatitis, *American Journal of Clinical Pathology* 2000;113:40-55.
- [24] Knodell R G, Ishak K G, Black W C. et al Formulation and application of a numerical scoring system for assessing histological activity in asymptomatic chronic active hepatitis. *Hepatology* 1981;1431-435.
- [25] Gordon H and Sweet HH. 1936. A simple method for silver impregnation of reticulin. *American Journal of Pathology* 1936;12:545.
- [26] Asanza CG, et al. Immunohistochemical Evidence of Immunopathogenetic Mechanisms in Chronic Hepatitis C Recurrence After Liver Transplantation. *Hepatology* 1997;26:755-763.
- [27] Garcia-Monzon C, et al. Chronic Hepatitis C in Children: A Clinical and Immunohistochemical Comparative Study With Adult Patients. *Hepatology* 1998;28(6):1691-1701.
- [28] Neubauer K, et al. Decrease of PECAM-1-gene-expression induced by proinflammatory cytokines IFN- γ and IFN- α is reversed by TGF- β in sinusoidal endothelial cells and hepatic mononuclear phagocytes. *BMC Physiology* 2008;8:9.
- [29] Scoazec JY, Feldmann G. In situ immunophenotyping study of endothelial cells of the human hepatic sinusoid: results and functional implications. *Hepatology* 1991;14:789-797.