

Research Journal of Pharmaceutical, Biological and Chemical Sciences

A Hospital Based Study On Capecitabine Induced Palmar Plantar Erythrodysesthesia.

Sharmi VJ, Parthiban P*, and Nagamani N.

Government Vellore Medical College, Vellore, Tamil Nadu, India.

ABSTRACT

Palmar Plantar Erythrodysesthesia (PPE), also called Hand-foot syndrome or acral erythema is an adverse drug reaction of certain cancer chemotherapy. Various drugs implicated in causation of palmar plantar erythrodysesthesia are 5 Fluorouracil, liposomal Doxorubicin, Cytarabine and Capecitabine. Case reports of Palmar plantar erythrodysesthesia following cancer chemotherapy are being made since 2003. Capecitabine is approved to be used singly or in combination, for colorectal, gastric and metastatic breast cancer. Hand-foot syndrome has been proven to be the dose limiting toxicity of Capecitabine, leading to significant morbidity. Though many case reports and few systematic reviews are available for Capecitabine induced Palmar plantar erythrodysesthesia, there is limited data available on prevalence of Capecitabine induced palmar plantar erythrodysesthesia and its severity. Hence this study was conducted to estimate the prevalence and severity of Capecitabine induced palmar plantar erythrodysesthesia, among colorectal, gastric, and metastatic breast cancer patients receiving Capecitabine in a regional cancer institute in Tamilnadu.

Keywords: Capecitabine, palmarplantar erythrodysesthesia, cancer.

<https://doi.org/10.33887/rjpbcs/2022.13.1.36>

**Corresponding author*

INTRODUCTION

Palmar Plantar Erythrodysesthesia (PPE), also called Hand-foot syndrome or acral erythema is an adverse drug reaction of certain cancer chemotherapy [1]. It is characterised by redness, swelling, pain and sometimes blisters on the palms of the hands and/or the soles of the feet, rarely occurs on the skin of the knees or elbows [2]. The overall prevalence of PPE was found to be 2.01% [3]. Various drugs are implicated in causation of palmar plantar erythrodysesthesia. Common drugs are 5-Fluorouracil, Docetaxel, liposomal Doxorubicin, Cytarabine and Capecitabine [4].

Capecitabine is a prodrug of 5-Fluorouracil, an antimetabolite. Capecitabine has improved tolerability and higher intratumor drug concentrations through tumor-specific conversion to the active drug [5]. Exact mechanism of Capecitabine producing hand foot syndrome is unknown. Capecitabine is activated inside the tumor cells by thymidine phosphorylase enzyme. This enzyme along with dihydropyrimidine dehydrogenase, which causes breakdown of 5-fluorouracil is implicated in the causation of Palmar-plantar erythrodysesthesia [6].

Capecitabine is approved to be used singly or in combination, for colorectal, gastric and metastatic breast cancer [7]. Hand-foot syndrome has been proven to be the dose limiting toxicity of capecitabine, leading to significant morbidity [1]. About 28-74% patients treated with Capecitabine develop PPE [8]. Severity of hand foot related events are graded by National Cancer Institute as mild (Grade 1), moderate (Grade 2), severe (Grade 3), and life-threatening (Grade 4). Minimal skin changes, erythema, and peeling (Grade 1); moderate skin changes, swelling, and edema (Grade 2); painful erythema and swelling in the palms and soles (Grade 3); or pain with bloating, deep peeling, and ulceration (Grade 4) [9]. Though many case reports and few systematic reviews are available for Capecitabine induced Palmar plantar erythrodysesthesia, there is limited data available on prevalence of Capecitabine induced palmar plantar erythrodysesthesia and its severity. Hence this study was conducted to estimate the prevalence and severity of Capecitabine induced palmar plantar erythrodysesthesia, among colorectal, gastric, and metastatic breast cancer patients receiving Capecitabine in a regional cancer institute in Tamilnadu.

Objective

To estimate the prevalence and severity of capecitabine induced palmarplantar erythrodysesthesia (PPE) among colorectal, gastric, and metastatic breast cancer patients on Capecitabine.

METHODOLOGY

A retrospective study was done at Arignar Anna Memorial Cancer Hospital and Research Institute, Karapettai, Kanchipuram district for a period of 1 year. The study subjects were individuals diagnosed with colorectal, gastric, and metastatic breast cancers who were on treatment with capecitabine. The data for occurrence, severity and management of PPE, were obtained from medical records of these patients. Data were analysed by Statistical Package for Social Sciences (SPSS 21.0 software)

Study design

Retrospective observational study.

Study area

Arignar Anna Memorial Cancer Hospital and Research Institute, Karapettai, Kanchipuram, Tamilnadu

Study duration

1 year (Jan 2015 to Dec 2015).

Study population

383 Individuals diagnosed with colorectal, gastric, metastatic breast cancer on treatment with Capecitabine.

Study tool

Medical records of these patients.

Standard dose of Capecitabine

825mg/m² body surface area twice a day orally for 14 days in each cycle of 3 weeks for 6 cycles.

Statistical analysis

Data was analysed using SPSS Software 21.0 version.

RESULTS AND DISCUSSION

Of the 383 persons who were prescribed capecitabine, 53% had colorectal cancer, 30% had gastric cancer and 17% had metastatic breast cancer (fig 1). The frequency of occurrence of PPE in capecitabine prescribed individuals was found to be 2.8 %. That is, 3.5% of gastric cancer, 3% of colorectal and 1.5% of breast cancer individuals on capecitabine, developed PPE (fig 2). They were graded for severity from 1 to 3 as per National Cancer Institute guidelines with frequency of grade 1, 2, 3 severity being 45%, 36% and 18% respectively (fig 3). Grade 1 were treated symptomatically with steroid cream and NSAIDS, grade 2 with dose reduction and grade 3 PPE necessitated stoppage of capecitabine and treatment with Urea/steroid cream, oral pyridoxine plus steroids, cold compresses, and NSAIDS.

Figure 1: Individuals prescribed with Capecitabine

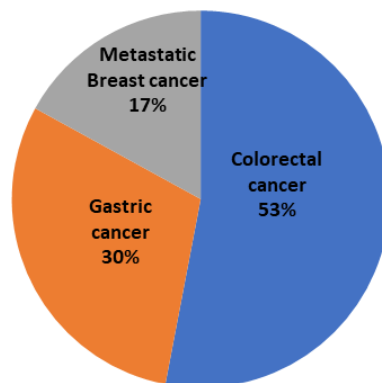


Figure 2: Palmarplantar Erythrodysesthesia occurrence in study population

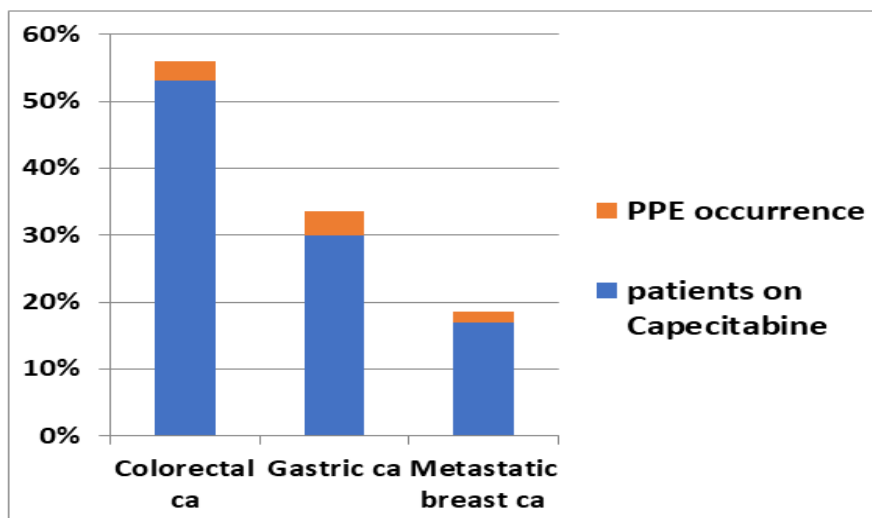
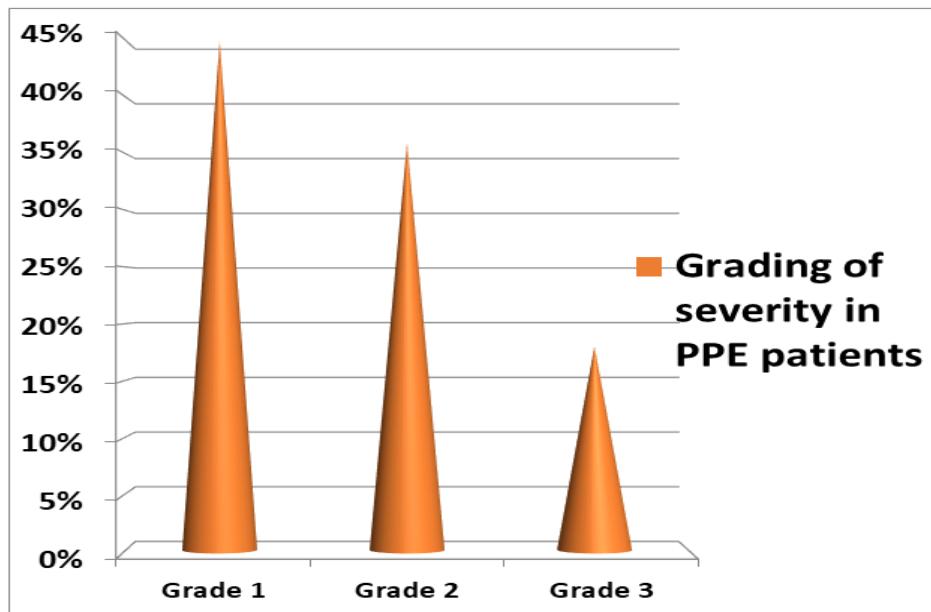


Figure 3: Severity grading of PPE in study population



CONCLUSION

This study provides limelight on the prevalence and severity of Capecitabine induced Palmar plantar erythrodysesthesia and its management modalities, in a regional cancer institute in Tamilnadu. Further studies estimating the prevalence of Palmar plantar erythrodysesthesia in Capecitabine treated cancer patients of other regions are necessary to predict the overall prevalence of this syndrome.

Concomitant initiation of PPE prophylactic therapy along with capecitabine may delay the onset and decrease the severity of this adverse drug reaction, enabling the administration of chemotherapy without decreasing the quality of life.

REFERENCES

- [1] Surjushe A, Vasani R, Medhekar S, Thakre M, Saple DG. HAND-FOOT SYNDROME DUE TO CAPECITABINE. *Indian J Dermatol.* 2008;53(1):43-4.
- [2] Hand-Foot Syndrome or Palmar-Plantar Erythrodysesthesia [Internet]. *Cancer.Net.* 2012 [cited 2016 Jul 2]. Available from: <http://www.cancer.net/navigating-cancer-care/side-effects/hand-foot-syndrome-or-palmar-plantar-erythrodysesthesia>
- [3] Palaniappan M, Srinivasamurthy S, Dubashi B, Chandrasekaran A. Anticancer Drug Induced Palmar Plantar Erythrodysesthesia. *J Clin Diagn Res JCDR.* 2014 Oct;8(10):HC01-3.
- [4] Webster-Gandy JD, How C, Harrold K. Palmar-plantar erythrodysesthesia (PPE): a literature review with commentary on experience in a cancer centre. *Eur J Oncol Nurs Off J Eur Oncol Nurs Soc.* 2007 Jul;11(3):238-46.
- [5] Walko CM, Lindley C. Capecitabine: a review. *Clin Ther.* 2005 Jan;27(1):23-44.
- [6] Kigen G, Busakhala N, Njiru E, Chite F, Loehrer P. Palmar-plantar erythrodysesthesia associated with capecitabine chemotherapy: a case report. *Pan Afr Med J [Internet].* 2015 Jul 30;21. Available from: <https://www.ncbi.nlm.nih.gov/pmc/articles/PMC4607982/>
- [7] Capecitabine [Internet]. National Cancer Institute. [cited 2016 Jun 11]. Available from: <http://www.cancer.gov/about-cancer/treatment/drugs/capecitabine>
- [8] Kara IO, Sahin B, Erkisi M. Palmar-plantar erythrodysesthesia due to docetaxel-capecitabine therapy is treated with vitamin E without dose reduction. *The Breast.* 2006 Jun;15(3):413-23.
- [9] Aras E, Yücel KT, EkiNciOğlu AB, Güllü İ. Capecitabine Induced Hand-Foot Syndrome: A Systematic Review of Case Reports. *Clin Exp Health Sci [Internet].* 2019 Jun 30 [cited 2023 Jan 6]; Available from: <https://dergipark.org.tr/en/doi/10.33808/clinexphealthsci.469538>.