

# Research Journal of Pharmaceutical, Biological and Chemical Sciences

## A Novel Method Of Human Cadaver Embalming, Dissection And Preparation Of Museum Specimen

Shilpa Karkera<sup>1\*</sup>, and Priya Ranganath<sup>2</sup>.

<sup>1</sup>Assistant professor, Department of Anatomy & Neuroscience, Trinity school of Medicine, St Vincent & Grenadines, West Indies.

<sup>2</sup>Professor and Head, Department of Anatomy, Bangalore Medical College, Bangalore, Karnataka, India.  
India.

### ABSTRACT

Embalming is the art and science of preserving human remains by treating them to forestall decomposition. Dissection and demonstration of the specimens have high importance in teaching learning process especially in disciplines like human anatomy where it is essential for medical students to have visual experience and understanding of three dimensional relationships of the structures. Since, these specimens are used for decades, fungal growth on them is one of the commonly faced problems in the labs and museums. Hence, a revised fixation technique which will prevent the fungal growth is the need of the hour. Keeping these in mind, we are reporting an instant yet long lasting method of embalming, and easy dissection techniques where all the structures can be visually clear and easy of identification which can be preserved for years in museums or can be used in a dissection hall during teaching learning sessions. In this article we have discussed about anatomical consideration of embalming, embalming fluid, and procedure of embalming in detail along with conventional methods of incision.

**Keywords:** Anatomy, Embalming, Chemicals, Type of embalming, Neural tube defects (NTD).

<https://doi.org/10.33887/rjpbcs/2021.12.1.27>

*\*Corresponding author*



## INTRODUCTION

Definition of embalming – A process of chemically treating the dead human body to reduce the presence and growth of the micro-organism which causes decomposition and restore acceptable physical appearance of the dead body<sup>1</sup>.

Within the framework of medical education, anatomists use human bodies to teach students, either by demonstrating prosected specimens or by dissection done by students themselves. The bodies are therefore used as educational tools.

One of the most important prerequisites for the use of human bodies in educational settings is the appropriate preservation of cadaver. Preservation is considered appropriate when the cadaver is kept safe from harm, destruction or decomposition. This is achieved by treating the cadaver with special chemicals, i.e. embalming. One of the most important chemicals used for this purpose is formaldehyde.

Teaching of anatomy of human body is an integral part of the study of medicine. Dissection of the dead is the best method to study the human anatomy of different body parts. The dissection of the body is lengthy procedure and dissected parts of the body are displayed for longer duration without decomposition and dehydration. Therefore proper preservation of the cadaver is necessary. There is a difference between anatomical embalming and funeral embalming. The main criteria for anatomical embalming are proper preservation and sterilization and suitability for dissection. For this purpose venous drainage and cavity treatment is not necessary.

The aim of this study is therefore to give a short overview of the embalming, summarize anatomical embalming procedures, identify and briefly describe most important chemicals and finally different incisions during dissection.

### Types of embalming <sup>[2]</sup>

- I. Arterial embalming – it involves injection of embalming chemical into the blood vessel usually via the right common carotid artery. Blood is drained from right jugular vein. The embalming solution is injected using an embalming machine and the embalmer massage the cadaver to ensure a proper distribution of the embalming fluid. In case of proper circulation other injection paint are used.
- II. Cavity embalming – injecting embalming chemical in the cavity such as thoracic, abdominal, cranial etc. as needed.
- III. Hypodermic embalming – is injecting embalming chemical under the layer of skin as needed.
- IV. Surface embalming – supplement to other method especially for visible, injured body parts.

### Chemicals used in embalming <sup>[3]</sup>

Embalming fluid is a mixture of various chemical which helps to retard decomposition of body, which are enlisted below –

- I. Preservative – these arrest the decomposition by altering enzyme and lysins of the body. These are mixture of formaldehyde, glutaraldehyde, and phenol. Generally, formalin refer specifically from 5% - 37% of aqueous formaldehyde and the methanol content may range from 9 – 56%. Methanol is used to hold the formaldehyde in solution.
- II. Water conditioner – these are meant to balance the “hardness” of water, as the presence of traces of other chemical that changes water’s PH neutrality and to help reduce the deceased’s acidity, a by-product of decomposition as formaldehyde works best in an alkaline environment . Additionally, water conditioner helps to neutralize chemotherapy drugs, antibiotics, which may bind to and render ineffectual the preservative chemical.

- III. Cell conditioner– these chemical act to prepare cell for absorption of arterial fluid and help break up clots in the bloodstream.
- IV. Dyes – active dyes are used to restore body’s natural coloration and counter stain against condition such as jaundice as well as to indicate distribution of arterial fluid. Inactive dyes are used by the manufacturer of the arterial fluid to give a pleasant color to the fluid in, but do nothing to the appearance of the embalmed body. Ex – ponceau red, erythrosine, Amaranth.
- V. Modifying agents– this includes buffer humectants and inorganic cells. These agents influence the chemical reaction produced by preservative solution and function in embalming fluid to control the action of main preservative agents.
- VI. Buffers- help to maintain acid base balance. Ex – EDTA
- VII. Inorganic salts– they are important in determining osmotic qualities of the embalming solution.
- VIII. Humectants– these are added to dehydrated and emaciated bodies to help to restore issues to a more natural and hydrated level.
- IX. Anti-edema chemicals- these are opposite to the humectants, these are designed to draw excessive fluid from body.
- X. Anti-coagulants– they retard the post-mortem tendency of blood to become more viscous. Ex- Sodium Citrate, Sodium Oxalate and Sodium Salt of EDTA.
- XI. Surfactants– these are chemicals that excludes the molecular cohesion of a liquid so, that it may flow through smaller apertures ex-sulfonates, alkyl sulfonates, alkyl aryl sulfonates, and sodium luryl sulfate.

All chemical in the embalming fluid are designed to preserve and sanitize the body. The factor considered in selection and preparation of an embalming fluid are age, sex, status of body, weather condition, type of embalming (anatomical or funeral). The composition of the chemical in embalming fluid varies in most of the medical colleges.

#### **MATERIALS AND METHODS**

This is a prospective, observational study conducted in Bangalore Medical College & Research institute (BMCRI), Bangalore; during the period of December 2011 to April 2018. The study included 20 adult cadavers, 20 normal fetuses and 60 fetuses with NTD. Before the embalming begins the body was disinfected with disinfection solution followed by soap and water for washing of the body. Nasal, oral and orbital cavities were cleaned. Eye caps or cotton pads were inserted under the lids to effect eye closure. Limbs are massaged to relieve the stiffening of the joints and muscles and mouth was closed prior to embalming by the use of adhesive.

#### **Fluids used**

##### **Arterial fluid**

It is injected into extremities of the body through vascular system. Mainly through right common carotid artery and right femoral artery. Its content and concentration differs as per the condition of body.

**Embalming of adult cadavers:**

Incision in carotid triangle was performed to locate for common carotid artery for embalming head and neck along with brain. Takes 2 hours for infusion of arterial fluid.

Incision in femoral triangle to locate femoral artery to embalm abdomen, thorax and extremities. Takes 4 hours for infusion of arterial fluid.

**Table 1: Arterial fluid for obese cadavers.**

Preservative	Formalin	10%
	Methanol	55%
Buffer	Sod. Borate	15%
Anticoagulant	Sod. citrate	15%
Wetting agent	Glycerine	15%
Germicide	Phenol	5%
Vehicle	Water	15%
Fungicide	Thymol	Few crystal
Dye	Eosin	1%
Perfume		10ml

**Table 2: Arterial fluid for lean and fetal cadaver.**

Preservative	Formalin	10%
	Methanol	55%
Buffer	Sod. borate	15%
Anticoagulant	Sod. Citrate	15%
Wetting agent	Glycerin	20%
Germicide	Phenol	5%
Vehicle	Water	10%
Fungicide	Thymol	Few crystal
Dye	Eosin	1%
Perfume	Winter green	10ml

Above concentration is needed to prepare 1 liter of arterial fluid; glycerin should be reduced in fatty body and in warm countries formalin concentration should be doubled.

**Embalming of fetal bodies**

Embalming requirement of an infant is not the same as the adult. (Table 2)

Several important factors should be considered before embalming the fetus.

- Infant skin is very delicate and can easily distend and wrinkle after arterial infections.
- The vessels in the infant are extremely small and delicate.
- Embalming solutions are the same as in the adult but slightly reduced in strength

**Cavity treatment for fetal cadavers**

Aspiration and cavity embalming was done by an infant trocar. It is about 12 inches in length with an inside diameter of ¼ inches. Right and left inguinal regions of abdominal cavity were used as entry points for trocar.

**Insertion of trocar for aspiration**

**Right side of heart:** along a line from left anterosuperior iliac spine and right ear lobule.

**Stomach:** directed towards intersection of fifth intercostal space and left midaxillary line until the trocar entered the stomach.

**Cecum:** To a point three fourth of the distance on a line from pubic symphysis to right anterosuperior iliac spine.

**Urinary bladder:** Towards pubic symphysis in the median line until it touched the bone.

Next cavity embalming was done immediately along the same line using the infant trocar. The fetus can be kept in formalin tank for few days before dissecting.

### Quantity of fluid required for embalming

Number of factor determines the strength and amount of fluid required for effective embalming of a body. It includes weight, age, Obesity, Moisture content of body time between death and preparation. There is 6 to 7 liters of blood in the vascular system of an average body. This account for approximately 8% of total body weight. Usually the amount of the arterial fluid injected should be equal to the blood volume of the deceased to ensure effective embalming.

Once the body is embalmed it is stored in a tank filled with formalin for 1 to 3 months.

**Table 3: Content of Tank**

Formalin	15%
Glycerin	20%
Phenol	5%
Water	60%

### Methods of Dissection

#### Positioning of the body

The body was kept in the supine position with a wooden block under the shoulder to keep the neck in extended position. These cadavers were dissected and few specimens were preserved as museum specimens.

To make the dissection easier and for visualizing and location of the structures we have followed conventional methods of incision. Below are the types of incision in which we have followed a fourth incision.

**Types of Incisions:** [4,5,6,7,8,9,10]

#### "I" – shaped incision

It starts from symphysis menti and extends straight to symphysis pubis right or left to umbilicus. Disadvantages of this incision is the prominent stitch mark in front of neck, thorax, abdomen and also the neck structures especially in the back of neck are not visualized.

#### "Y" – shaped incision

Starts at a point close to the acromion process extending downwards below the breast and across to the xiphoid process in both sides, then from the xiphoid process, the incision is extended downwards to the symphysis pubis. Here, visualization of neck structure is very poor but in this incision the stitch mark in front of the neck is absent.

#### Modified "Y" – shaped incision

Starts behind the user to mid clavicular point bilaterally, then carried out over the clavicle to supra sternal notch and then a straight incision to symphysis pubis in midline. Disadvantage here is also the

prominent stitch mark in front of neck and poor visualization of back of neck though exposure of the neck structure in front of neck and to some extent the side of neck is better.

#### **Fourth incision**<sup>11,12,13,14</sup>

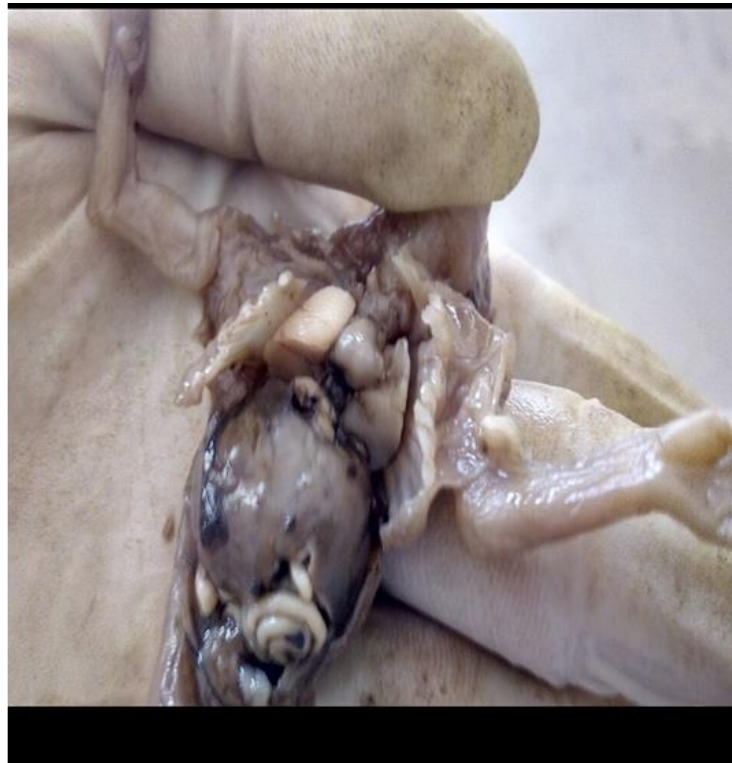
To overcome the problems in the first three types of incision where the neck structures were not properly exposed, the fourth incision was done to make maximum possible exposure of the whole circumference of the body.

A curved incision was made bilaterally from the acromion process through the medial border of shoulder joint to mid-axillary line laterally, this continued to the iliac crest over the inguinal ligament to meet pubic symphysis. The skin with the superficial tissue flap was reflected up the root of the neck, then to the inferior margin of mandible bilaterally, taking care not to injure the neck structures and rectus sheath. This way whole of the front of the neck, chest and abdomen was exposed.

**Opening abdominal cavity:** A paramedian incision was made on rectus near pubic symphysis up to xiphoid process.

**Opening thoracic cavity:** Sternum was removed by cutting at costochondral junction and then separating sternoclavicular joint.

By this way we can reflect the whole flap of skin from the pubic symphysis up to the root of neck and then to the inferior margin of mandible bilaterally. The whole of the anterior aspect of neck, chest and abdomen can be visualized and examined in this way (Figure1, 2 and 3).



**Figure 1: Dissected NTD fetus of 25 weeks using fourth incision**

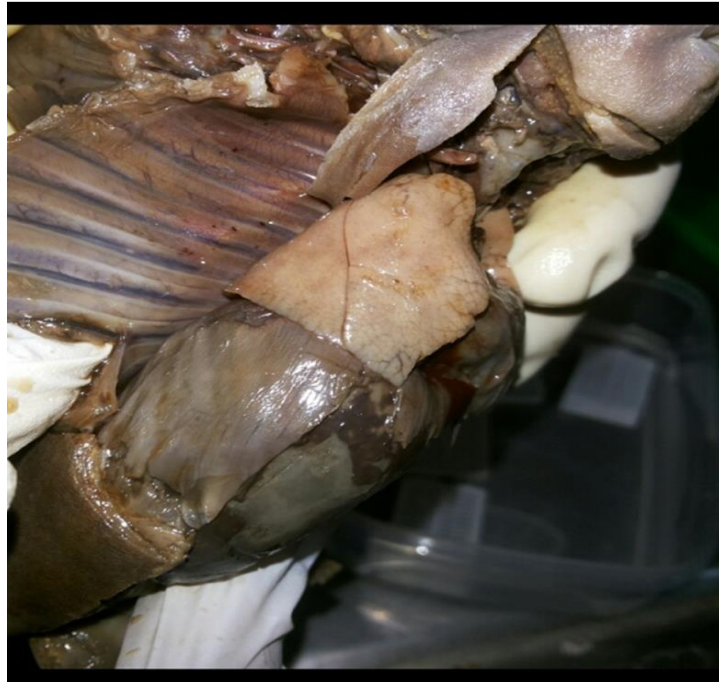

Figure 2: Dissected 30 weeks fetus using fourth incision

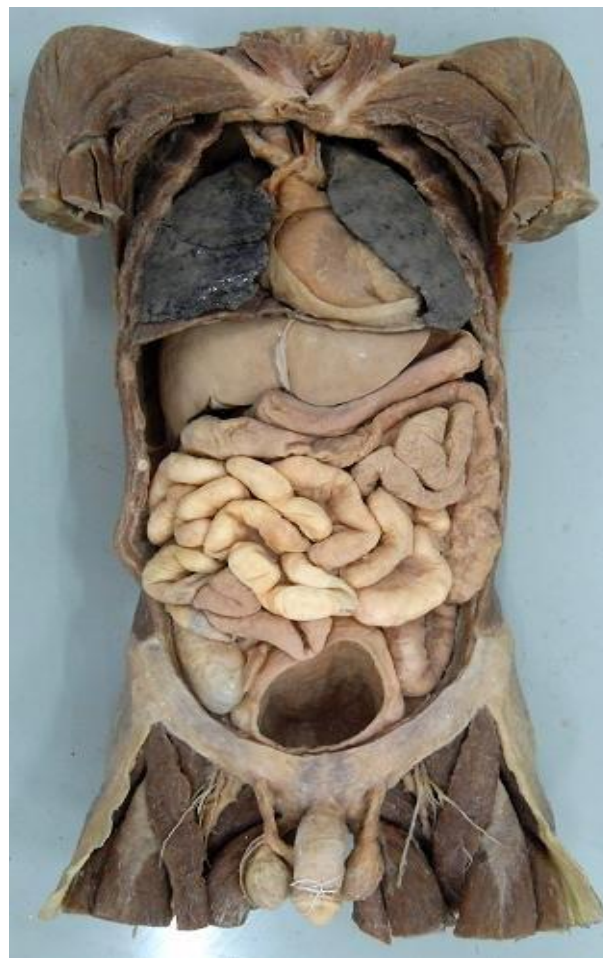

Figure 3: Dissected adult male cadaver using fourth incision

## CONCLUSION

Embalming procedure is a mixture of science and physics. Along with arterial embalming method other supplementary methods are used to protect body against putrefaction. Dilution or concentration of embalming fluid is decided as per the condition of the body. Though the standard procedures to embalm body are same but a close consideration is always required while choosing an appropriate method and concentration of fluid for embalming.

This study emphasizes whole circumference of the body is exposed in the cosmetic autopsy incision. A conventional method which we used in the present study is better for dissection and visualizing anatomical variation. While using the conventional methods to expose the spinal cord in some cases, we have to make a separate incision. But if we use the fourth incision, it can be done while the body is in prone position after reflecting the skin flap.

## REFERENCES

- [1] ML Ajmani, Embalming Principle and law, Reprint 2009, Jaypee Brother and publisher, pg.no-4.
- [2] ML Ajmani, Embalming Principle and law, Reprint 2009, Jaypee Brother and publisher, pg. no-26.
- [3] Arvinder Pal Singh Batra et al, Embalming and other method dead body preservation, International Journal of Medical Toxicology and Legal Medicine, Vol12, No.3, June-Mar 2010.
- [4] Vij Krishan. Text book of forensic medicine and toxicology. 5th ed. New Delhi: Elsevier; 2011. p. 17-23, 160-8.
- [5] Camps Francis E, Gradwohl legal medicine. 3rd ed. Bombay K.M. Varghese company; 1976. p. 70-77, 356-60
- [6] Laaksonen H, Parikh CK. Dissection of neck in medico legal postmortems in India. 1st ed. Bombay: Dr. CK Parikh medical publication; 1985. p. 42-43.
- [7] Parikh CK. Parikh's text book of medical jurisprudence and toxicology. Bombay Medical centre; 1990. p. 93-104.
- [8] Reddy KSN. The essentials of forensic medicine and toxicology. 29th ed. Hyderabad: K. Suguna Devi; 2010. p. 91-111, 284-93.
- [9] Knight B, Forensic pathology. 3rd ed. London: Arnold; 1996. p. 16-30 312-24.
- [10] Mathiharan K, Patnaik Kamrit. Modi's medical jurisprudence and toxicology. 23rd ed. Haryana: Lexis Nexis; 2009. p. 357-80, 629-42.
- [11] Patowary AJ. The fourth incision a cosmetic autopsy technique. The American Journal of Forensic Medicine and Pathology 2010; 31(1):37-41.
- [12] Patowary AJ. The fourth incision – a few modifications in the autopsy incision technique. The Journal of Indian Academy of Forensic Medicine 2010; 32(3):234-8.
- [13] Pillay VV. Text book of forensic medicine and toxicology 16th ed, Hyderabad, New Delhi, Paras medical publisher, 2011. p. 139-43, 225-35.
- [14] Patowary AJ, Mahanta Putul. Autopsy. In: Mahanta Putul, editor. Modern Text Book of Forensic Medicine and Toxicology. New Delhi: Jaypee Brothers Medical Publishers (P) Ltd; 2014. p. 205-210.