

Research Journal of Pharmaceutical, Biological and Chemical Sciences

Therapy Endocardiosis Mitral Valve Heart In Dogs.

Evgeniy M Marin^{1*}, Kristina A Umnova¹, Oksana N Marina¹, Valeriy A Ermolaev¹,
Igor V Nenashev², and Victor V Zemlyankin².

FSBEI HE Ulyanovsk State Agrarian University named after P.A. Stolypin 432017, Ulyanovsk, Novyy Venets Boulevard, 1.

²FSBEI HE Samara State Agricultural Academy, 446442, Russia, Samara, Ust-Kinelskii, Uchebnaya st. 2

ABSTRACT

The article presents data on the prevalence of mitral valve endocardiosis in dogs. On the basis of the survey were formed experimental groups of animals who were prescribed the following treatment of endocardiosis of the mitral valve of the heart in dogs: experimental group: vasotop P - 0.125 mg/kg 1 time per day constantly (orally); furosemide - 2 mg/kg 1 time per day 3 days (intramuscularly); veroshpiron - 2 mg /kg 1P per day 1 month; therapeutic diet - Hills h\d; control group: fortekor 5 mg /kg 1 p in day constantly (orally); veroshpiron 2 mg / kg 1 time per day 1 month (orally); furosemide 2 mg / kg 1 once a day for 3 days (intramuscularly); therapeutic diet Hills h\d. The conservative treatment of endocardiosis of the mitral valve of the heart in dogs showed the most favorable course of the disease in the experimental group, which was confirmed not only by the clinical condition of the sick animals, but also by echocardiography and radiography.

Keywords: heart, endocardiosis, dwarf breeds of dogs, mitral valve, auscultation, heart murmurs

**Corresponding author*

INTRODUCTION

Among many non-communicable diseases of cats and dogs, cardiovascular diseases are the most common. In cats, there is a incidence of cardiomyopathy, hypertension [10, 13, 15, 17]. In dogs, the incidence of endocardiosis of atrioventricular valves and hypertension is more common [3, 7, 19, 21]. Endocardiosis of atrioventricular valves is a fairly common disease among dogs of the older age group. In the scientific literature there is a lot of information on the study of this pathology [5, 9, 12, 18]. The disease of atrioventricular valves occurs in 70% of all cardiac diagnoses with signs of congestive heart failure, characterized by progressive myxomatous degeneration of the valves of the atrioventricular heart, during ventricular systole causes the appearance of mitral or tricuspid regurgitation (reverse injection of another portion of blood into the left or right atrium) [1, 7, 12, 16].

Endocardiosis is a degeneration of the valves of non-inflammatory nature. Leading to deformation and development of insufficiency of the valve. Infecting mitral (MK) and rarely tricuspid (TSC) valve [4, 6, 14, 18]. The most common site of lesion is the mitral valve, characterized by the formation of thickening and deformation of valve flaps, starting from the free edges and ending with the involvement of the entire surface of the flaps and tendon threads [2, 8, 11, 17, 20].

The aim of this work is to study the comparison of drugs "Vasotope" and "Fortekor" in the medical treatment of endocardiosis of the mitral valve in dogs.

MATERIALS AND METHODS OF RESEARCH

The work was carried out in a veterinary clinic "cat and Dog" Penza. We conducted a retrospective analysis of patients who underwent echocardiography. Two groups of animals were formed, the selection was carried out on the principle of paired analogues, taking into account the age category, as well as with the same degree of mitral valve damage. All animals were kept in approximately the same conditions with the same feeding. With the same degree of mitral valve damage.

To confirm the diagnosis, animals underwent electrocardiography using veterinary electrocardiograph Neurosoft poly-Spector 8 / V. x - Ray examination was performed on a digital x - ray system (Donqmun tube, low-dose receiver with digital processing alpha-P-4000). ECHO - cardiography was performed using the apparatus ALPINION ECUBE 9 phased-array transducer (SP 3-8).

On the basis of the conducted examination, experimental groups were formed and the following treatment of endocardiosis of the mitral valve of the heart was prescribed:

Experienced group: Wastop R - 0.125 mg/kg, 1 time a day continuously (oral); Furosemide 2 mg/kg, 1 times daily 3 days (intramuscular); Verospiron - 2 mg /kg 1P a day 1 month; therapeutic diets - Hills h\d;

Control group: Fortekor 5 mg / kg 1 p per day constantly (pen-ralno); Veroshpiron 2 mg/ kg 1 time per day 1 month (orally); Furosemide 2 mg/kg 1 time per day 3 days (intramuscularly); therapeutic diet Hills h\d.

A General examination was carried out: the temperature of the animal's body was measured, the animals were examined for the General condition, the presence of cough and shortness of breath, the color of the visible mucous membranes, conjunctiva, the presence of noise during auscultation, and the frequency of respiratory movements per minute was measured. Ultrasound of the abdominal cavity was not carried out, since endocardiosis of the mitral valve has no diagnostic value. It is carried out to detect splenomegaly, hepatomegaly and ascites in right-sided chronic insufficiency.

RESEARCH RESULTS

The results of monitoring of morbidity showed that of the total number of dogs of all breeds older than 5 years, the incidence of endocardiosis of the mitral valve is 32% at n=130. This disease prevails in groups of small and medium-sized dogs (up to 15 kg), dogs from 5 to 8 years (10%), from 8 years to 10 years (20%), older than 10 years (30%), older than 13 years (40%).

Visual inspection of dogs suffering from mitral valve endocardiosis noted a pronounced, painful cough, increased thirst, if not a normal amount of urination. Peripheral edema and ascites were not recorded. Appetite stored, vomiting is absent, the activity is saved. When auscultation of the heart, the correct rhythm was noted, the heart tones were clear. Murmur: systolic at MK 1, noise of friction of pericardium absent. In auscultation of the lungs, bronchial respiration was recorded, with percussion of the chest - a clear pulmonary sound.

Endocardiosis instrumental diagnostics of mitral valve of the heart in dogs before treatment are shown in figures 1-5.

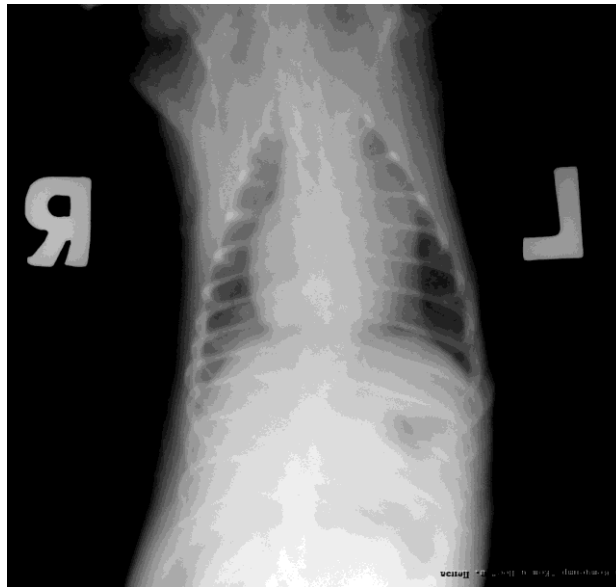


Figure 1. - Chest x-ray: signs of left atrial hypertrophy. Compression of the trachea is not expressed. Stagnation: is missing. Pleural cavity without features.

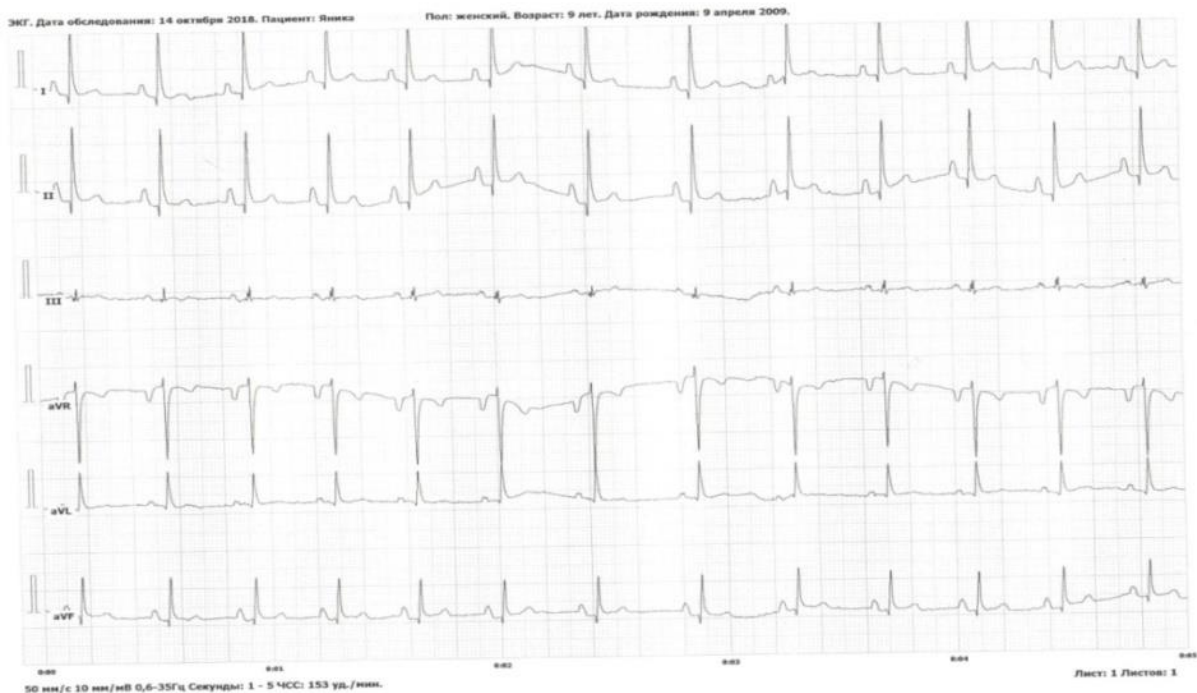

Figure 2. - Electrocardiogram of a patient with chronic mitral valve insufficiency. Signs of sinus tachycardia, increased left atrium.

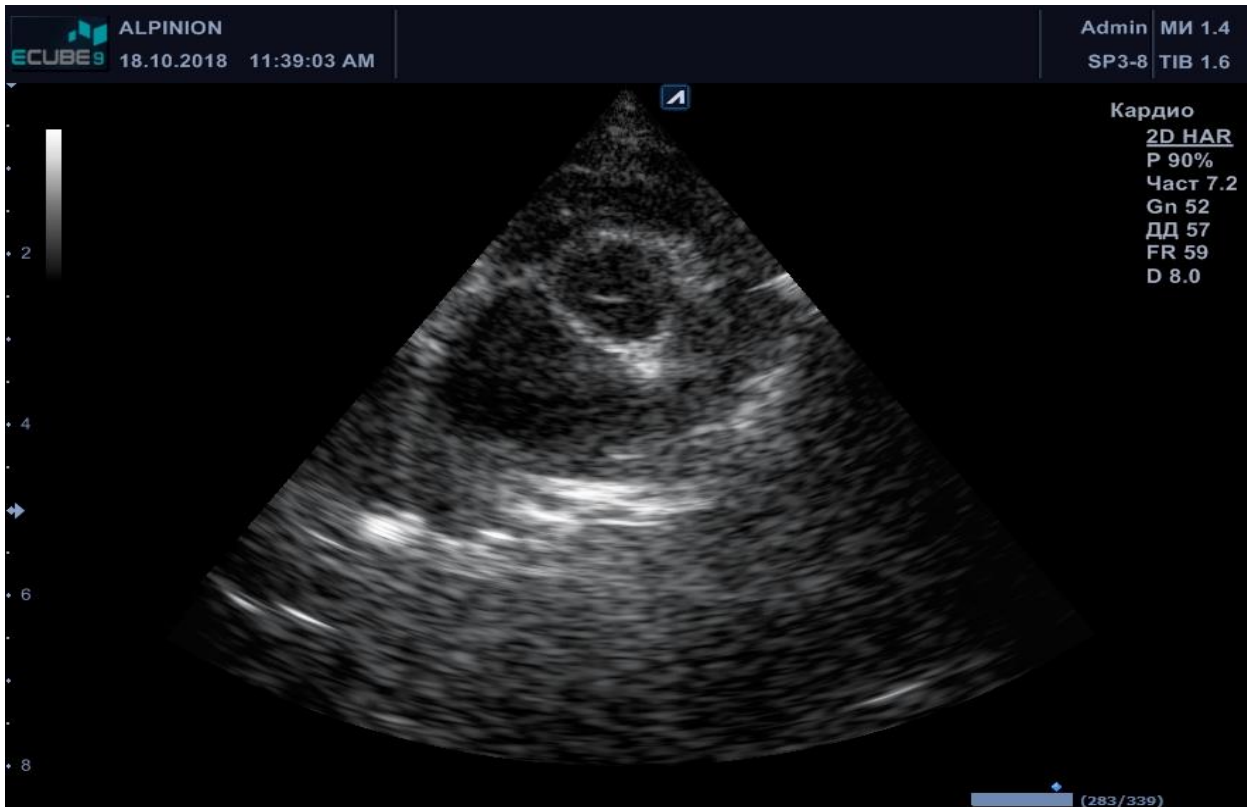


Figure 3. - Echocardiogram (right parasternal access on the short axis at AO level). Expansion of the left atrial cavity and the left ventricle.

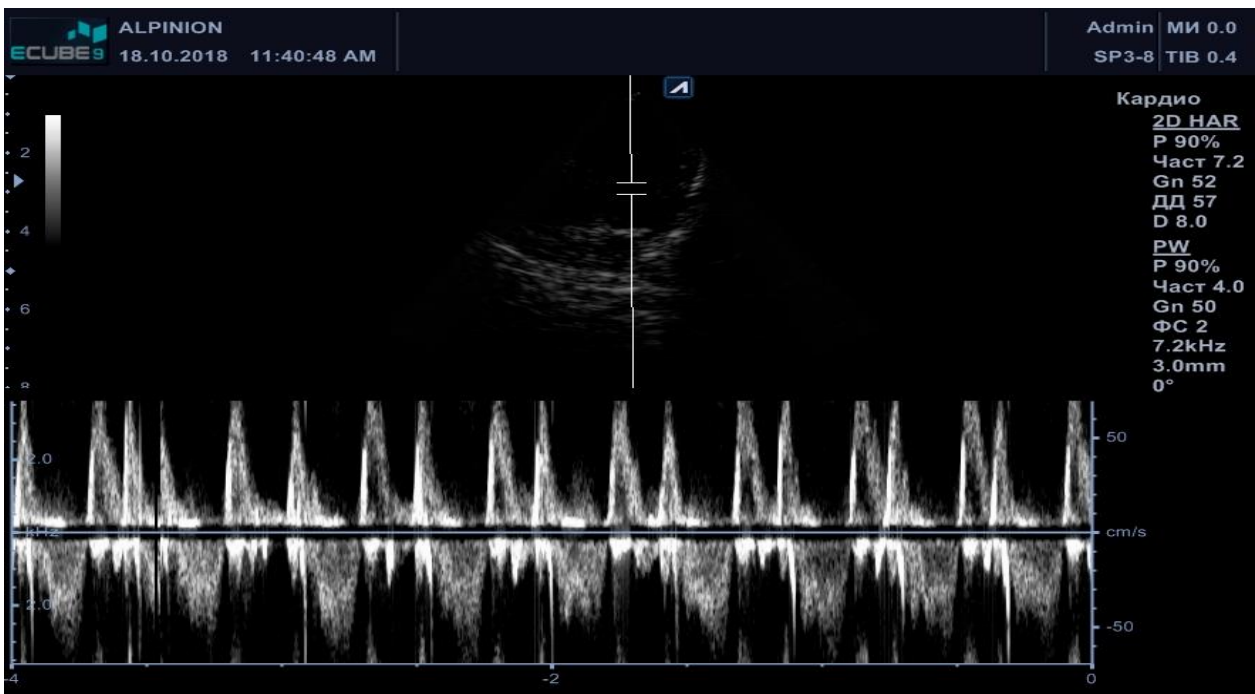


Figure 4. - Echocardiogram M-mode right parasternal short projection, the calculation of the CRA, CEB and fraction of contractility. Signs of mitral regurgitation, velocity peak moved to the first half of the systole.

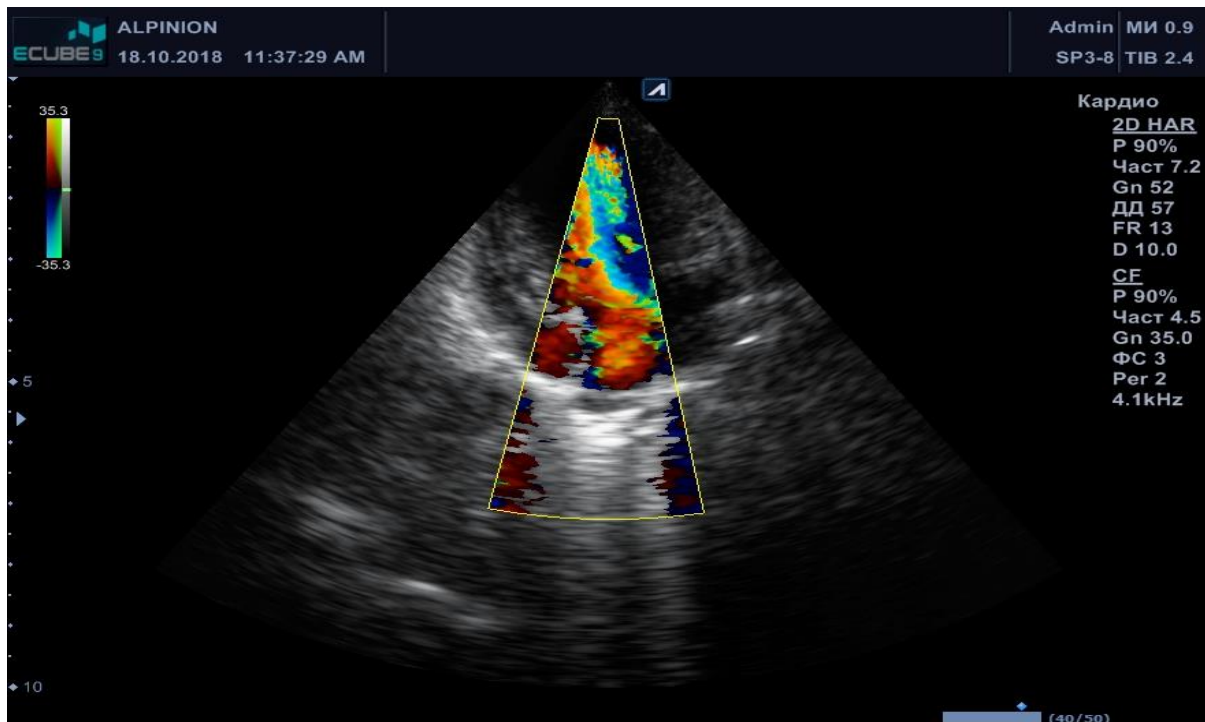


Figure 5-Echocardiogram (left parasternal access, five-chamber projection, color Doppler mapping mode).

The results of the effectiveness of conservative treatment of endocardiosis of the mitral valve in dogs are presented in tables 1 and 2.

Table 1. - Clinical picture for the period of therapy in the experimental group.

Symptoms	1 day	3day	5day	7 day	14 day	30 day
Cough	+	+	+	-	-	-
Dyspnea	-	-	-	-	-	-
Appetite	+	+	+	+	+	+
Thirst	+	-	-	-	-	-
Diuresis	-	+	-	-	-	-

In the experimental group, after three days of treatment, we observe a decrease in the strength and frequency of coughing, reduced to 1 time per day, improved General condition, lack of polydipsia and polyuria, appetite is preserved. Pulse rate, breathing unchanged. Canceled loop diuretics on the 4th day of treatment. After 7 days, there are no coughing attacks.

Table 2. - Clinical picture for the period of therapy in the control group.

Symptoms	1 day	3day	5day	7 day	14 day	30 day
Cough	+	+	+	+	-	-
Dyspnea	-	-	-	-	-	-
Appetite	+	+	+	+	+	+
Thirst	+	-	-	-	-	-
Diuresis	-	+	-	-	-	-

In the control group for 5 days the cough remained, improvements were after the 7th day of treatment (coughing 1-2 times a day), on the 14th day there are no coughing attacks. Added Prednisolone on the 5th day of treatment for decreasing dosage, the dosage of fortekor increased to 0.5 mg / kg.

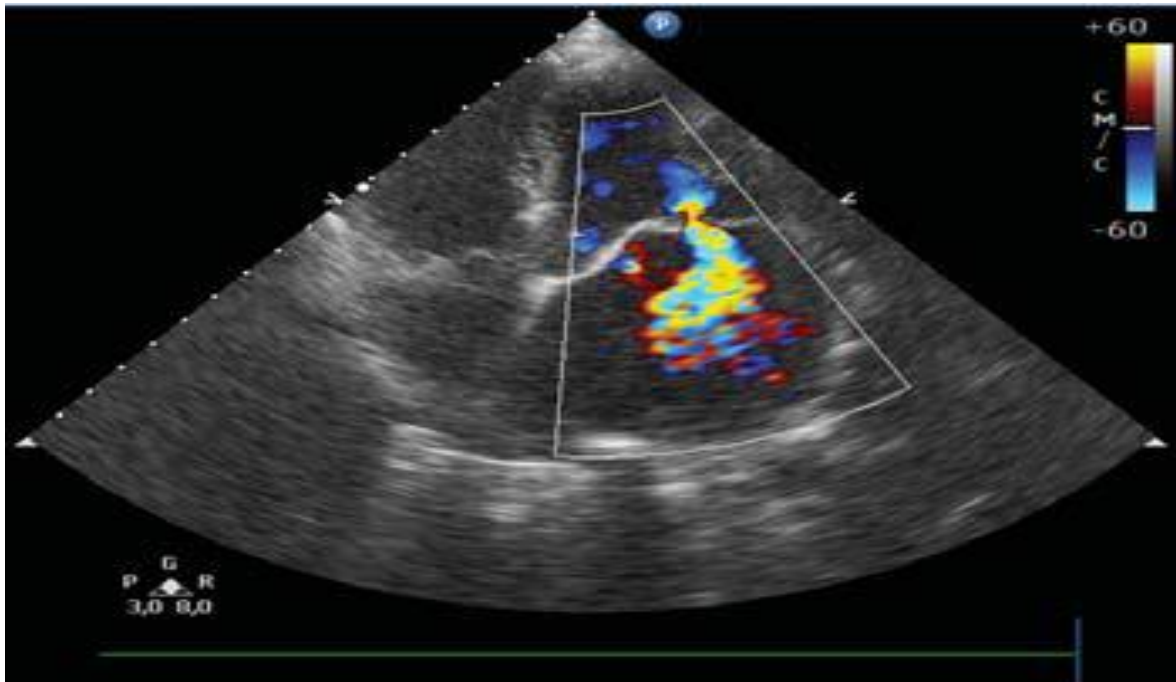


Figure 6. - Echocardiography. Color Doppler: regurgitate and the cavity of the left atrium is maintained. In the area of the furnace raster at a lower speed.

According to the results of clinical examination of animals of both groups, improvement of the General condition of animals was revealed, the severity of clinical symptoms (cough, shortness of breath) decreased. The absence of polydipsia and polyuria, appetite preserved for the entire period of treatment. Pulse rate, breathing unchanged. During the treatment period there were no complications in the form of renal or hepatic insufficiency.

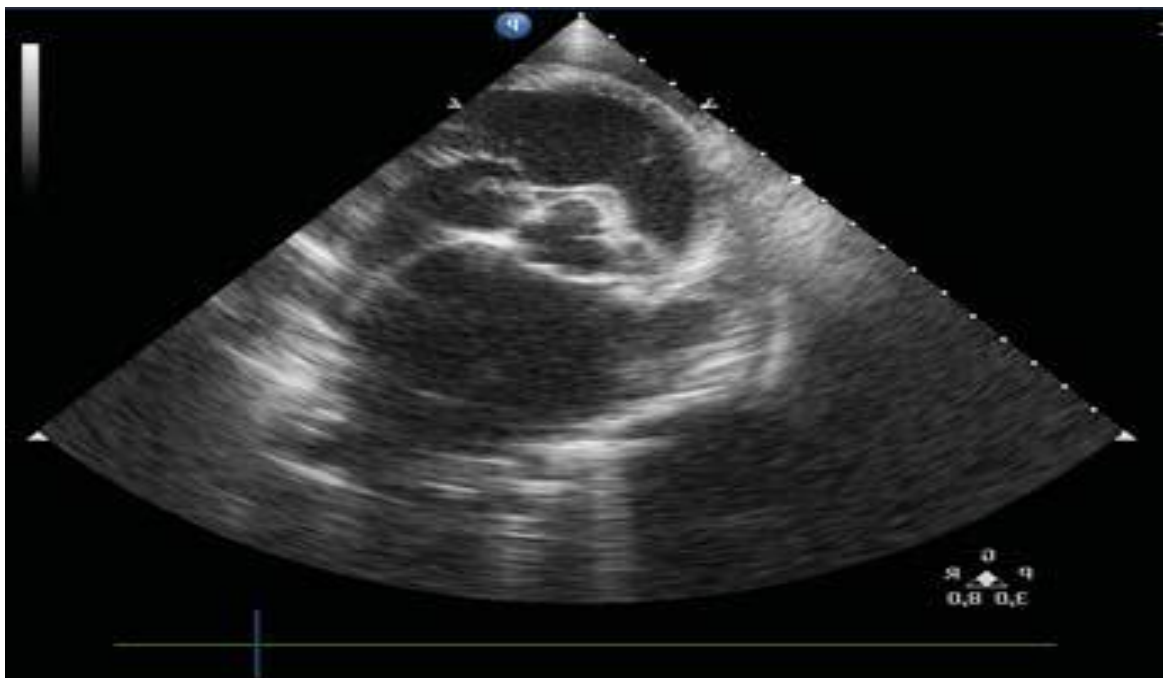

Figure 7. - Apical five-chamber position of the Aorta: 11.3 mm (not expanded). The aortic valve is not altered. The ratio of LP/AO: 1,63716814159292. MWP in diastole, long axis: 4.9 mm

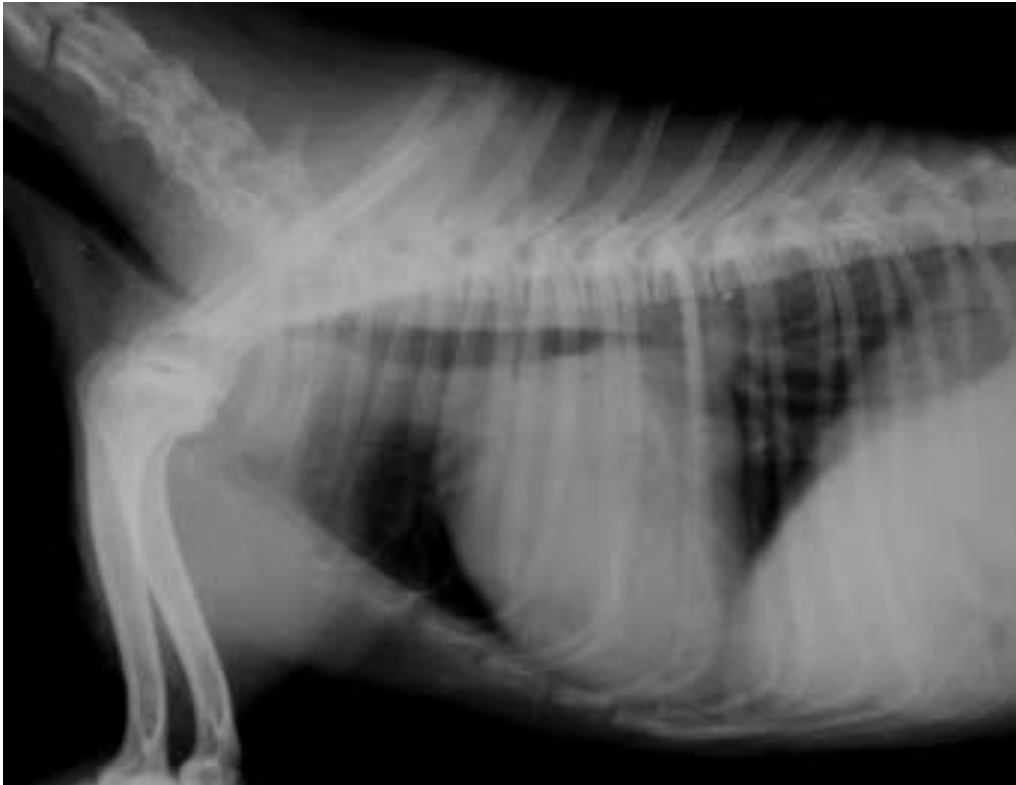

Figure 8. - X-rays (Lateral projection). Unchanged.

Since the Fortekor is excreted by the kidneys only - by 15% and the Vasotop - by 40% , in animals of both groups the biochemical parameters were slightly increased, in particular in the renal and hepatic profile. The disease is chronic, prolonged drugs ACE inhibitors for life.

SUMMARY

Analyzing the treatment in both groups, we can say that the treatment method used in the experimental group is the most effective, since the positive dynamics was observed in three for treatment. In the control group, the signs of the disease persisted until the 7th day of treatment. After the correction of treatment of endocardiosis of the mitral valve, the signs of the disease were not recorded by 14 days.

REFERENCES

- [1] Annikov V.V., Moiseev E.N. Clinical and biochemical evaluation of the effectiveness of the Vasotop in cardiomegaly of dogs. Bulletin of Saratov state agrarian University. N. And. Vavilova. 2010; 11: 6-9.
- [2] Annikov V.V., Moses E.N. Clinico-radiological and biochemical changes in the background Wastop when cardiomegaly in dogs. Proceedings of the Orenburg state agrarian University. 2011; 3 (31): 122-125.
- [3] Belov, A.V., Ponosov S.V., Ibishov D.F. The incidence of cardiogenic ascites in large dog breeds. The Perm agrarian journal. 2018; 2 (22): 118-122.
- [4] Zhulikova O.A. Monitoring of the spread of cardiovascular diseases among cats and dogs in the city of Blagoveshchensk of the Amur region. Far Eastern agricultural Bulletin. 2016; 2 (38): 49-56.
- [5] Kamenev, A. V. Estimation of the importance of ECHOCARDIOGRAPHY and HM ECG in the diagnosis of DCM in asymptomatic stage and the influence of Benazepril hydrochloride (Fortekor) on Dobermans in this stage of the disease. Russian veterinary journal. Small Pets and wild animals. 2014; 2: 6-9.
- [6] Kruglova T.S., Pakhmutov I.A. Biochemical and crystallographic status of the dogs and its features in the diagnosis of heart failure, caused by mitral valve endocardiosis and other diseases. In the book: food security and sustainable agricultural development proceedings of the International scientific-practical conference. 2015, pp. 428-433.

- [7] Nazarov, M.V. Application of Pimobendan (Vetmedin®) in clinical practice in endocardiosis mitral valve. *VetPharma*. 2016; 4 (32): 60-63.
- [8] Connell, P.S., Han R.I., Grande-Allen K. J. Differentiating the aging of the mitral valve from human and canine myxomatous degeneration. . *Journal of Veterinary Cardiology*. 2012; Vol. 14; 1: 31-45.
- [9] Dillon, A.R., Dell'italia L.J., Tillson M., Killingsworth C., Denney T., Hathcock J., Botzman L. Left ventricular remodeling in preclinical experimental mitral regurgitation of dogs. *Journal of Veterinary Cardiology*. 2012; Vol. 14; 1: 73-92.
- [10] Fox, P. R. Pathology of myxomatous mitral valve disease in the. *Journal of Veterinary Cardiology*. 2012; Vol. 14; 1: 103-126.
- [11] Kellihan H.B., Stepien R.L. Pulmonary hypertension in canine degenerative mitral valve disease. *Journal of Veterinary Cardiology*. 2012; Vol. 14; 1: 149-164.
- [12] Mallery, K. Factors contributing to the decision for euthanasia of dogs with congestive heart failure. *Journal of the American Veterinary Medical Association*. 2009; 8: 1201-1204.
- [13] Tidholm A.A., Jonsson L. Retrospective study of canine dilated cardiomyopathy (189 cases). *J. Amer. Anim. Hosp. Assoc.* 1997; Vol. 33; 6: 544-550.
- [14] Tillet L.P., Smith F.W.K., Oyama M.A., Sleeper M.M.. *Manual of Canine and Feline Cardiology*. Fourth Edition, Philadelphia: Saunders, an imprint of Elsevier Inc., 2008, 443 p.
- [15] Lyashenko P.M., Ermolaev V.A., Zolotukhin S.N., Maryin E.M., Sapozhnikov A.V. *Fundamentals of emergency veterinary care for animals*, Ulyanovsk, 2018; Vol. 2, 98p.
- [16] Nenashev I.V., Marin E.M., Ermolaev V.A. Testing of intramuscular administration of rometar on pain sensitivity and clinical and physiological parameters in rams edilbaevskoy breed. *Research Journal of Pharmaceutical, Biological and Chemical Sciences*. 2018; Vol. 9; 6: 982-986.
- [17] Sapozhnikov A.V., Maryin E.M., La Schenk, P.M. Clinical and endoscopic picture of pathologies of internal organs in dogs and cats. *Vestnik of Ulyanovsk state agricultural Academy*. 2015; 4 (32): 143-146.
- [18] Ermolaev V.A., Maryin E.M., Lyashenko P.M., Sapozhnikov A.V. *Anesthesiology*. Ulyanovsk, 2018, 72p.
- [19] Lyashenko P.M., Ermolaev V.A., Zolotukhin S.N., Maryin E.M., Sapozhnikov A.V. *Fundamentals of emergency veterinary care for animals*, Ulyanovsk, 2018; Volume Part 1, 228p.
- [20] Lisichin A.A., Maryin E.M., Pichugin Yu.V. Study of the chest dogs by radiography. In collection: *STUDENT RESEARCH FORUM - 2017 IX international student electronic scientific conference*. 2017.
- [21] Suvorov, A.A., Ermolaev V.A. Portosystemic shunt in dogs. In the world of scientific discoveries, proceedings of the II International student's scientific conference. 2018, pp.55-58.