

# Research Journal of Pharmaceutical, Biological and Chemical Sciences

## Management Of Complicated Crown-Root Fracture By Inter Disciplinary Approach: A Case Report: 7-Years Follow-Up.

Swathi<sup>1\*</sup>, Vivek Amin<sup>2</sup>, Suhail Shariff<sup>3</sup>, and Maria Priya Paul<sup>1</sup>.

<sup>1</sup>Department of Conservative Dentistry and Endodontics, A J Institute of Dental Science, Mangalore, Karnataka, India.

<sup>2</sup>Department of Orthodontics, Yenepoya Dental College, Yenepoya University, Mangalore, Karnataka, India.

<sup>3</sup>Ibn Sina National College for Medical Studies, Jeddah, Saudi Arabia.

### ABSTRACT

In everyday practice, the clinician sometimes sees cases of sub-gingival trauma. Possible therapeutic options include orthodontic extrusion or surgical lengthening, as well as extraction and prosthetic restoration. A predictable aesthetic restoration is not limited to the restored teeth; it has to include the gingival unit and its interface with the teeth involved. Failure to place the crown margins on sound tooth material may violate the biologic width and should be considered a restorative failure. Orthodontic root extrusion or forced eruption is a well-documented clinical method for altering the relation between a non-restorable tooth and its attachment apparatus, elevating sound tooth material from within the alveolar socket. This case describes a multidisciplinary approach of management of fractured crowns with periapical pathology which was endodontically treated and then extruded by fixed orthodontic appliances. Subsequent to endodontic and orthodontic treatment, biological width realignment procedure was done followed by prosthodontic rehabilitation.

**Keywords:** Biologic width, Forced eruption, Ferrule.

*\*Corresponding author*

## INTRODUCTION

Subgingivally fractured incisors pose a true therapeutic dilemma for the dental team. Tooth fracture below the gingival attachment or alveolar bone crest presents restorative difficulties because there is inadequate tooth structure to achieve a ferrule effect following reconstruction with a post and core and crown. Under these conditions the resulting restoration margins would extend up to the depth of the gingival sulcus, encroach upon the biologic width and may lead to potential chronic gingival inflammation. [1]

Extrusion of such teeth elevates the fracture line above the epithelial attachment so that proper finishing margins can be placed.

Treatment options for teeth fracture involving the biologic width include

- Endodontic therapy followed by Orthodontic Extrusion
- Surgical Crown Lengthening
- Extraction and Implants
- Extraction and fixed prosthesis

The advantage of orthodontic extrusion is that it does not involve the loss of bone or periodontal support. In the absence of root eruption, a surgical crown lengthening procedure alone will have a negative architectural impact on the adjacent teeth that can impact the crown to root ratio adversely, elongate clinical crowns and open embrasures by disrupting the interdental bone. [1] Implants are very successful in replacing missing units but their cost may not be afforded by a number of patients. In addition fixed and removable prostheses can be destructive to sound abutment teeth and can result in damage to dental and soft tissue. This article describes a multidisciplinary approach using orthodontic extrusion, biological width realignment procedure followed by prosthodontic rehabilitation with a follow up of seven years.

## CASE REPORT

A twenty-year-old male patient presented to the Department of Conservative Dentistry and Endodontics, Yenepoya Dental Collegewith complaints of fracture and bad appearance of his upper right central incisor, lateral incisor and canine. He gave a history of trauma four months back. The patient was in excellent general health with no known allergies, took no medication and denied the use of tobacco. Intra-oral and radiographic examination revealed cervical root fracture and pulp exposure of teeth Nos. 11, 12 and 13.

The crown-root fracture was of chisel type, extending below the alveolar crest palatally and with circumferential probing depths of 1.0-mm, the biologic width had not been directly violated by the fracture. At the same time, however, there was inadequate tooth structure to achieve a ferrule effect following reconstruction with a post and core and crown. (Figure 1)

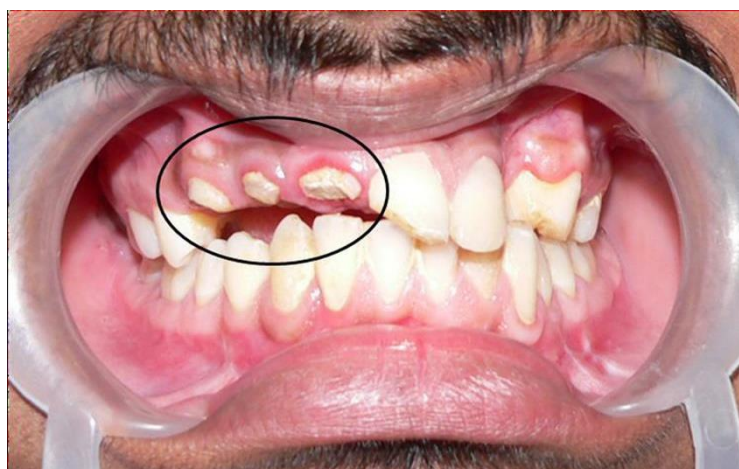

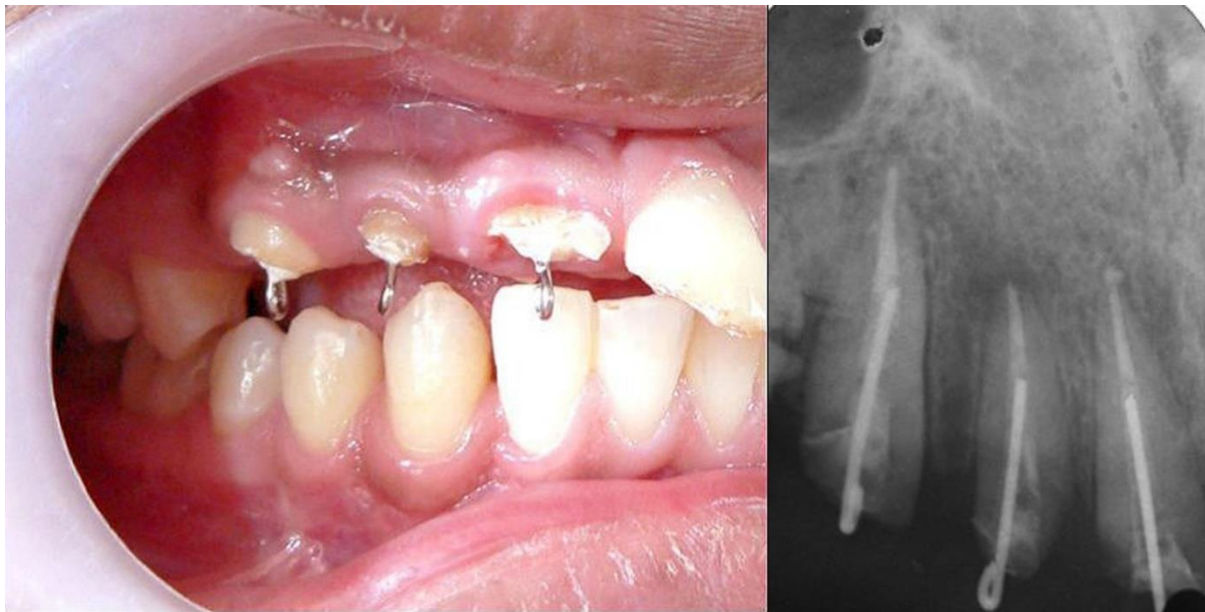
Figure 1: Pre-operative view

A number of treatment options were offered including:

- (a) Endodontic therapy, forced eruption and reconstruction with a post and core and crowns.
- (b) Extraction and placing implants
- (c) Extraction and placing a fixed prosthesis

After reviewing the risks and potential outcomes, the patient opted for forced eruption and reconstruction with post and core and crowns.

Endodontic therapy was started and taken to completion. The gutta-percha was removed from the coronal and middle 10-mm of the canal space. Using a drill, the canal space was prepared for a post-hook 1.0-mm in diameter. The post-hook was cemented into the canal space with zinc-phosphate cement. (Figure 2)



**Figure 2: J-hooks cemented**

The patient was strapped with Begg's appliance both in the upper and lower arch. A rigid 0.016-inch stainless steel wire was placed with step down bend given to extrude the fractured teeth. Light forces were given for slow extrusion of the teeth. Since there was no clearance, the lower anterior teeth were intruded using a 0.016-inch stainless steel wire.

Biologic width realignment procedure was done to establish biologic width on the extruded root repositioning the soft-tissue and/or bony profile apically into alignment with the architecture of the adjacent teeth. Crown lengthening with ostectomy and apically displaced flap was done.

The patient was recalled after a week for a check-up and a crown length of 4.5 mm was achieved. (Figure 3) Two weeks after surgical crown lengthening the orthodontic brackets were debonded from the upper and lower arches and splinting was done for stabilization.

The root system was then prepared for the placement of cast gold post and core. The cast post was cemented into place after fabrication. (Figure 4) Impressions were recorded and temporary crowns were seated. After 6 weeks of stabilization permanent PFM crowns were seated. (Figure 5)

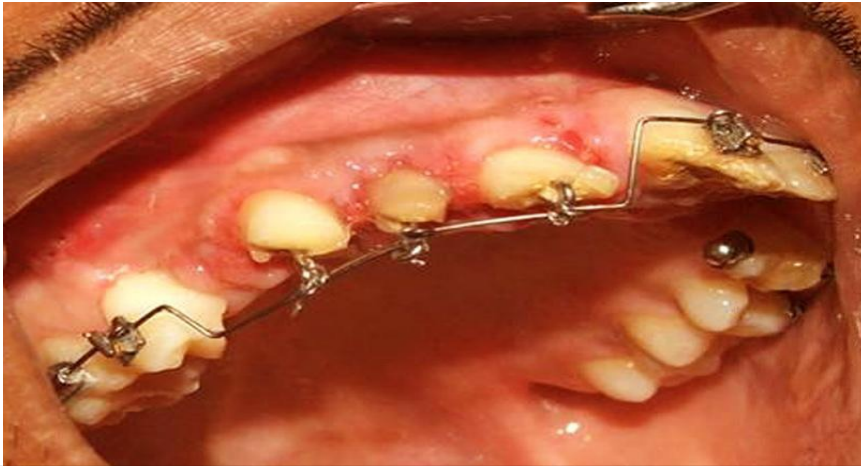

Figure 3: After crown lengthening - crown length of 4.5 mm achieved

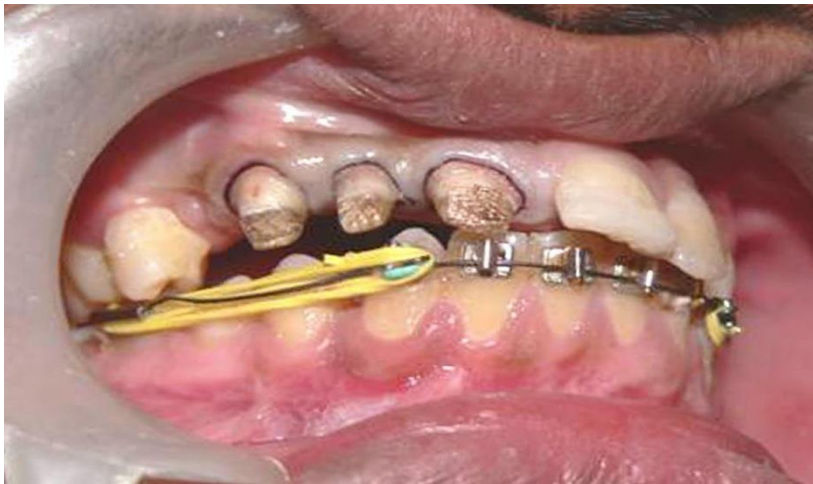

Figure 4: Custom-cast gold post and core cemented irt 11, 12 and 13

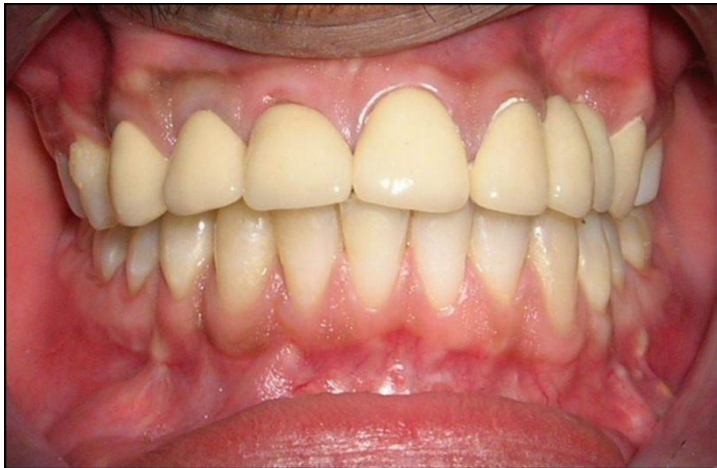
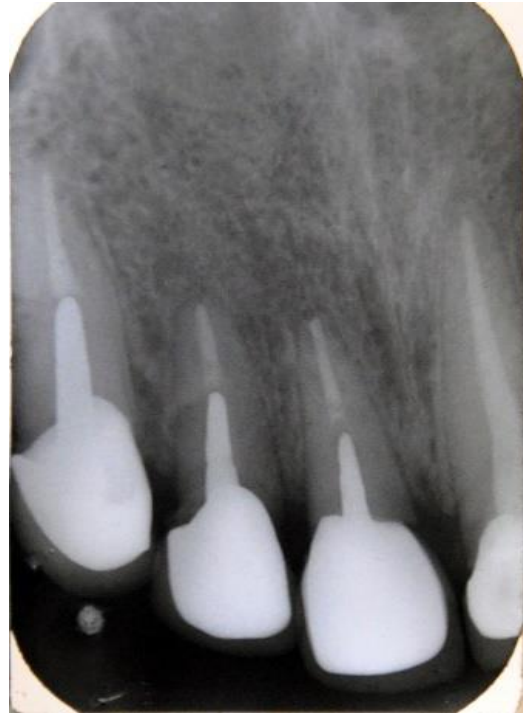
Figure 5: PFM Crowns cemented





**Figure 6: 7 years follow-up radiograph showing teeth 11,12 and 13 with periodontal healing and normal bony trabecular patterns**

The patient was periodontally healthy during the follow-up period. No relapse occurred by the end of seven years. The tooth did not show any signs of the root resorption during the treatment and follow up periods. Seven-years follow up radiograph revealed normal trabecular bony pattern. (Figure 6)

### DISCUSSION

The decision to choose orthodontic forced eruption as the final treatment modality was influenced by several considerations. Normand Bach et al discussed forced eruption as a conservative approach that saves the natural root system. It maintains the associated periodontal architecture thus retaining the option of future implant placement. Simple surgical crown lengthening involves additional resection of the bone of the adjacent teeth to the tooth that is to be lengthened. [2] They indicated that forced eruption also preserves the adjacent tooth structure by eliminating the restorative trauma of FPD preparation. Also, the overall cost to the patient is less than that of an implant or FPD. The major limitation of this treatment is the longer duration of treatment & longer stabilization period. [2] Orthodontic extrusion was introduced by Heithersay in 1973 and further developed by Ingberin 1974, 1976. [3] Timothy et al suggested that extrusion can be done by fixed or removable appliance although fixed devices can lead to precise and well-defined movements and generally requires less patient dexterity. [1]

Timothy et al reported forced eruption technique can occur slowly (that is, over the course of months), or very rapidly (over the course of weeks). While slow or rapid forced eruption will achieve the desired root movement, each technique has different periodontal implications. If the root is extruded slowly, there will be compensatory growth of bone and soft tissue not unlike what is seen in supra-eruption of an unopposed tooth. [1, 4, 5-8] Normand Bach et al indicated before the final restoration is completed, the bone and soft tissue must be recontoured to establish biologic width and alveolar architecture that is consistent with the adjacent teeth. [2] Some authors recommend simple fibrotomy procedure [3, 9] but according to several clinicians, fibrotomy has proved unpredictable and gingival and/or bone remodeling may be required. [2, 10, 11] Slow eruption can be advantageous for areas where bone growth is desired, such as interproximal areas where the bone can provide substructure for interdental papillae or correct a bony defect. Rapid extrusion involves stretching and adjustment of periodontal fibers, without marked bone remodeling due to

the fast movement. Relapse may follow orthodontic extrusion, the primary reason being the stretched state of marginal periodontal fibers. Malmgren Oetal indicated to avoid relapse, fibrotomy should be performed before the retention period, which should last for at least 3-4 weeks. [2] In reported case, the slow eruption was followed by biological width realignment procedures.

Timothy et al and Edward P Allen reported the level and extent of fracture dictates the success of the eruption process and is critical for determining the necessary amount of eruption. The objective is to re-establish a biologic width of 2.04mm;a minimum gingival sulcus of 0.69mm;and a prosthetic ferrule (1.5-2.0mm circumference of natural tooth structure coronal to the final restoration margin). [1, 12]

Orthodontic extrusion may be contraindicated, however, because of short root length and poor root form, which results in inadequate crown/root ratio following extrusion. [1, 2] A crown to root ratio of 1:1 is required. The final restoration length should be equal to or less than the amount of root that will remain in the bone. [1] In the reported case the root length of incisors allowed the teeth to undergo the necessary amount of extrusion and still retain a crown-root ratio of approximately 1:1.

#### **Stabilization:**

Once the desired amount of extrusion has been achieved, the tooth must be stabilized to allow for remodeling of the periodontal apparatus and to prevent relapse intrusion. Generally, the root system must be stabilized four weeks for every millimeter of movement. [1, 5, 13, 14]

#### **Reconstruction:**

Timothy M et al reported if osseous recontouring is necessary, an additional four to six weeks of healing will be required before final reconstruction can begin. Esthetic areas may require up to 8-10 weeks of healing. [1] In the reported case permanent crowns were given approximately 6-8 weeks after extrusion.

### **CONCLUSION**

The necessity for an interdisciplinary approach to treatments of complicated dental problems has been recognized for a long time. In the cases described, an endodontist, an orthodontist, a periodontist and a prosthodontist participated in the dental management of a patient with subgingivally fractured permanent maxillary anterior teeth. It is clear that without such cooperative action, the prognosis would not have been good.

### **ACKNOWLEDGEMENT**

I would like to whole heartedly thank my teacher Dr. Harish K. Shetty, Professor & Head of Department, Department of Conservative Dentistry & Endodontics, Yenepoya Dental college, Mangalore for his valuable guidance & timely advice.

I would like to whole heartedly thank my teacher Dr. M.S. Prathap, Professor, Department of Conservative Dentistry & Endodontics, Yenepoya Dental College, Mangalore for his constant support and encouragement.

### **REFERENCES**

- [1] *Timothy M. Durham, Thomas Goddard, Scott Morrison: Rapid forced eruption: A case report and review of forced eruption techniques. Gen Dent 2004; 52(2):167-75.*
- [2] *Normand Bach, Jean-François Baylard, René Voyer: Orthodontic Extrusion: Periodontal Considerations and Applications. J Can Dent Assoc 2004; 70(11):775-80.*
- [3] *Malmgren O, Malmgren B, Frykholm A. Rapid orthodontic extrusion of crown root and cervical root fractured teeth. Endod Dent Traumatol 1991; 7(2):49-54.*
- [4] *Levine RA. Forced eruption in the esthetic zone. Compend Contin Educ Dent 1997; 18: 795-803.*
- [5] *Wang WG, Wang WN. Forced eruption: An alternative to extraction or periodontal surgery. J Clin Orthod 1992; 26: 146-9.*



- [6] *Ivey DW, Calhoun RL, Kemp WB, Dorfman HS, Wheless JE.* Orthodontic extrusion: Its use in restorative dentistry. *J Prosthet Dent* 1980; 43: 401-7.
- [7] *Johnson GK, Sivers JE.* Forced eruption in crown-lengthening procedures. *J Prosthet Dent* 1986; 56: 424-7.
- [8] *Stevens BH, Levine RA.* Forced eruption: A multidisciplinary approach for form, function, and biologic predictability. *Compend Contin Educ Dent* 1988; 19: 994-1000.
- [9] *Ainama J, Tal, Talari A.* The increase with the age of the width of attached gingival. *J Periodontal Res*, 1976; 11(4): 182-8.
- [10] *Sabri R.* L'allongement coronaire par légression orthodontique principes et techniques. *J Parodontol* 1989; 8(2): 197-204.
- [11] *Lovdahl PE.* Periodontal management and root extrusion of traumatized teeth. *Dent Clin North Am* 1995; 39(1): 169-79.
- [12] *Edward P. Allen.* Surgical crown lengthening for function and esthetics. *Dental Clinics of North America* 1993; 37: 163-79.
- [13] *Benenati FW, Simon JH.* Orthodontic root extrusion: Its rationale and uses. *Gen Dent* 1986; 34: 285-9.
- [14] *Stroster TG.* Forced eruption: Clinical considerations. *Gen Dent* 1990; 38: 376-80.