

Research Journal of Pharmaceutical, Biological and Chemical Sciences

Effectiveness Of Surgical Treatment Of The Left-Sided Displacement Of The Abomasum In Cows And First Heifers In Trans-Urals.

Otto K. Sintiurev^{1*}, Larisa A. Glazunova², Andrei V. Plakhotnik³, Iurii V. Glazunov⁴, Olga A. Dragich⁵, and Klavdiia A. Sidorova⁶.

¹Veterinarian, FSBEI HE Northern Trans-Ural SAU.

²PhD Veterinary, Associate Professor, Associate Professor of the Department of Anatomy and Physiology FSBEI HE Northern Trans-Ural SAU.

³Veterinarian Zap Sib Khleb- Iset LLC.

⁴MD Veterinary, Associate Professor, Associate Professor of the Department of Infectious and Invasive Diseases FSBEI HE Northern Trans-Ural SAU.

⁵MD Biology, Associate Professor, Professor of the Department of Physical Culture, Tyumen Industrial University, Department of Anatomy and Physiology, FSBEI HE Northern Trans-Ural SAU.

⁶MD Biology, Professor, Head of the Department of Anatomy and Physiology, FSBEI HE Northern Trans-Ural SAU.

ABSTRACT

Objective of the research was to compare the effectiveness of various methods of surgical treatment of left-sided abomasum displacement in cows. Object of research: first heifers and cows in a large livestock complex with a productivity of 8,000 kg per year per 1 fodder cow. Methods of research: surgical treatment of left-sided displacement of the abomasum by "puncture", "suturing through the paralumbal fossa", and "abdominal midline operation". It was established that abomasum displacement is recorded in 4.39% of cows and first heifers of the surveyed farm. In total, 75 first heifers and 31 cows were operated. It was found that each of the methods had both advantages and disadvantages. The advantages of the puncture method are simplicity, due to the minimum access, quickness of the manipulations and minimum costs of treatment, while the success of the operation was 81.32% and 81.48% in the treatment of first heifers and cows, respectively. The disadvantages of this method include poor guidance during the operation (the abomasum is not visible), as well as inconvenient fixation of the animal (in the dorsal position). Surgical treatment with suturing through the paralumbal fossa was characterized by a high success rate among experienced surgeons, a comfortable position of the animal during the operation (in a standing position), no relapses, visual access to the operated organ and direct suturing of the abomasum, and control of fixation. The disadvantages of this method include a large surgical wound and the associated long-term postoperative recovery. It should be noted that the surgeon operating the animal must have certain physical characteristics subject to the long duration of the operation and need for physical strength and endurance, as well as long arms to grip the abomasum through the entire abdominal cavity. The midline abdominal surgery has a number of advantages, such as visualization of the abomasum, which allows it to be securely fixed, and fixing the animal in the dorsal position contributes to displacement of the abomasum to its anatomical position. Among the drawbacks are uncomfortable for the animal fixation in the dorsal position, and stress which can provoke an emetic reflex during operation. The use of abdominal surgery requires a long postoperative recovery, as well as an extensive surgical wound to access and, despite this, the impossibility of examining part of the abdominal cavity in this position. Given the advantages and disadvantages of each of the compared methods of treatment, as well as a high incidence of left-sided displacement of the abomasum among the first heifers, it is most advisable to use a puncture method that is simple to perform, quick to implement, low invasive, ensures low recurrence rate and high efficiency. In case of sufficient experience of the doctor and the capabilities of the farm facilities for the surgical treatment of cows and first heifers, treatment by suturing through the paralumbal fossa can be recommended.

Keywords: abomasum displacement, puncture method, suturing through the paralumbal fossa, abdominal midline operation, cows, first heifers.

**Corresponding author*

INTRODUCTION

Read displacement is an acutely progressing disease, which is characterized by a change in the anatomical position of the abomasum, filled with gases, liquid their combination, right or left [18,25]. At left-sided displacement, the abomasum is located caudodorsally between the scar and the left abdominal wall, and at right-sided - between the right abdominal wall and the intestine [1]. Left-sided displacement of the abomasum is characteristic of Holstein-Friesian cows and is recorded in 3-8% of the stock [12,16,19]. Right-sided displacement of the abomasum occurs much less frequently and is much easier to diagnose by rectal examinations [14]. A heavily enlarged abomasum is located between the abdominal wall and the intestinal loops, reaching the right paralumbal fossa [1]. Since conservative treatment ensures practically no results, and valuable animals drop out of the herd, the damage from the disease is enormous and consists of loss of milk production, which reaches 30%, as well as premature disposal of sick animals or their death [5,8,19,26].

Since 2005, Holstein-Frisian cattle have been imported to Tyumen region, which today forms the basis of the entire dairy herd of the region. In this regard, the problem of the abomasum displacement is relevant and needs to be addressed. Since conservative treatment has low efficacy and does not provide for the complete recovery of the animal, we set a goal to compare the effectiveness of various methods of surgical treatment of left-sided abomasum displacement in cows.

MATERIALS AND RESEARCH METHODS

The study was conducted from February 2015 to March 2017 in the breeding plant ZapSibKhleb-Iset LLC of Isetsky district of Tyumen region.

During the observation period, 2,460 cows with a productivity of 8,000 kg per year per 1 fodder cow were examined. The farm uses a stable-outdoor housing and a loose housing of animals.

To diagnose displacement, the data of anamnesis and the main symptoms were considered and other diseases of the internal organs with characteristic clinical manifestations were excluded. To diagnose the left-sided displacement of the abomasum, a method of visual assessment of the animal was used, since cows with this pathology strongly lose their weight. With the help of percussion, a basket-ball-bouncing sound was detected, the tone of this sound may vary depending on the course of the disease. During auscultation of the abomasum displacement areas were determined by sounds of fluid overflow; sometimes the sound of a falling drop was recorded. Rectal examination allowed finding location of the abomasum. Thus, a greatly enlarged abomasum could be located between the abdominal wall and intestinal loops, near the right or left paralumbal fossa [1,4].

Despite the use of standard research methods, 15% of cases of left-side displacement of the abomasum cannot be or rarely determined by auscultation. Auscultation with the help of a stethoscope is often complicated by industrial noise, which can prevent to find the best sound point and affect the outcome of the operation. Rectal examination also can be uncertain due to the different habit of animals. Thus, it is quite difficult to determine the correct abomasum topography with rectal examination in large animals. In this regard, for a more accurate diagnosis of abomasum displacement, a need for ultrasound arose. For this purpose, DRAMINSKI ultrasonic scanner with a convex sensor, scanning depth 15 cm and frequency 7.5 MHz was used;

The study used Mediagel highly-viscous ultrasound gel, which provided the optimal viscosity for the best visualization of the test organ. Ultrasound examination was performed in various positions of the animal: in the standing position, fixed in the machine, and fixed in the dorsal position.

During the operation by the puncture method, the animal was fixed in the dorsal position; the best points of hearing the abomasum and for puncture were determined by percussion, auscultation or ultrasound examination revealed. The surgical field was prepared and, in the area of the best sound localization, the abdominal wall and the abomasum were punctured using the trocar cannula, while trying to avoid disrupting the integrity of the intra-abdominal and hypodermic veins and blood vessels. After the puncture, the trocar was removed, leaving a cannula in a perforated abomasum. An indicator of perforation was the characteristic odor of abomasum gas. The suture fixator was inserted through the cannula into the abomasum using a trocar, then the cannula was removed, leaving the suture. Exactly the same principle was used to make a puncture at a distance of 7 cm. The seams were tied 5 cm from the skin surface. An antiseptic wound treatment was performed

and the animal was turned on its left side and forced to stand. After the operation, 40 liters of warm water with energy drink was fed to the animal with the help of a drencher. After surgery, a diet was prescribed [2,6,7,9,10,11,15,20,21].

During surgical treatment by suturing through the paralumbal fossa, the animal was fixed in a standing position, in a cage or machine, with the head securely fixed and the pelvic limbs tied together. The surgical field was prepared. Anesthesia was provided with a conductive paralumbal blockade with 100 ml of a 0.5% novocaine solution, and infiltration anesthesia was performed with a 2% novocaine solution in the area for the incision. Laparotomy was performed in the left paralumbal fossa, bleeding was stopped as the layers of the abdominal wall were dissected. After opening, the arm entered the abdominal cavity and the palm went along the abdominal wall behind the last rib 20 cm below the lumbar transverse vertebrae or along the scar, in most cases the abomasum was visible in the wound. For better convenience, the abomasum was pulled closer to the surgical wound, a needle with a rubber tube was inserted into it in order to reduce the volume of gases and the abomasum size. Then the displaced abomasum was captured by hand and carefully tightened to the edge of the wound, and then stitched with ta wo-story suture. At the same time, the suture in the region of large curvature was applied 5-7 cm long, not touching the mucous membrane of the stomach, at the ends of the suture, threads were sutured 1.5-2 m long. Then the abdominal wall was pierced from the inside along the midline of 25 cm from the cartilage, and the abomasum was placed in the abdominal cavity. To do this, an assistant was involved, who gradually tightened the thread to fix the stomach. During physiological positioning of the abomasum the topography of other organs was monitored. After placing the organ in a correct position, the assistant fixed both ends of the thread at a distance of 8-10 cm from the skin surface. In order to avoid injury to the skin, under the fixing thread a bandage was tied between the skin and the thread. At the end of the operation, an antibiotic was administered and the wounds were sutured. After the operation, the animal was isolated and received 40 liters of water with propylene glycol and Lacto-rumen, was prescribed a diet, a course of antibiotics and symptomatic therapy. Sutures were removed after 7-10 days [3,13,17,22,23,24,26].

During the abdominal medial surgery on the abomasum, the animal was fixed in the dorsal position, like for the puncture method. The operating field was prepared and the access point was anesthetized using an infiltration anesthesia with a 0.5% novocaine solution. A section located 20 cm from the cartilage was cut along the white line. After the laparotomy, the operating physician inserted his hand into the abdomen with a tubed needle used to reduce the pressure and size of the abomasum through the removal of gases from it. After this, the wall of the abomasum was sutured with a two-story suture to provide a reliable fixation of the stomach; suturing was performed to the caudal edge of the surgical wound. Amoxylong antibiotic was injected into the abdominal cavity and surgical wound was sutured with the subsequent treatment of the suture. After the operation, measures were taken as in the method of suturing through the paralumbal fossa [3,13,17,22,23,24,26].

RESULTS

During the observation period at the farm, 108 cases of left-sided displacement of the abomasum were recorded, which was 4.39%. To confirm the diagnosis, an ultrasound examination was conducted. For this, the cow in a standing position was shaved its fur in the region of the left hypochondria, namely in the region of the two last ribs, after which the gel was applied and the abdominal cavity was scanned, in particular, the abomasum (Fig. 1).

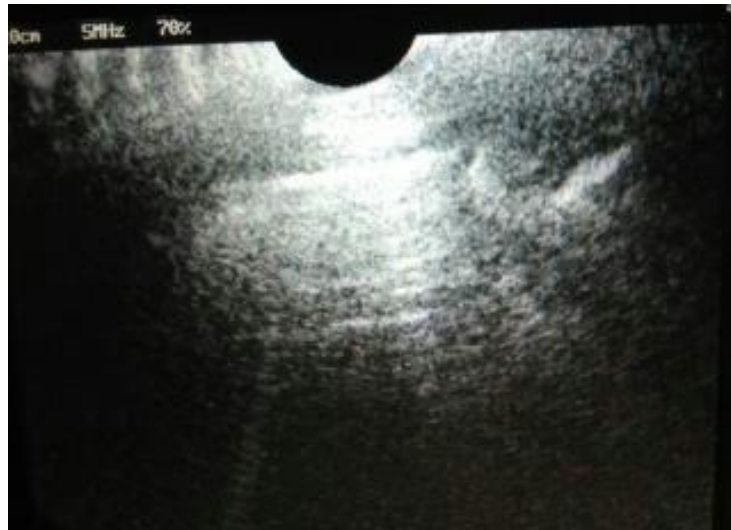

Figure 1. The boundary line between the abomasum and abdominal cavity

As Figure 1 shows, the ultrasound examination showed a hyperechoic zone, which is characteristic of this pathology. Hyperechoicity is explained by the presence of gas formed in the abomasum and the very high pressure caused by it, which makes the ultrasound glow.

Ultrasound examination in supine position was performed in the upper abdomen, as well as during auscultation.

In the course of the study, an image was obtained showing the hyperechoic glowing emitted by the contents of the abomasum (Fig. 2). During the operation by puncture method, invasive intervention (puncture) was performed in places where the glow of gases was the most intense.

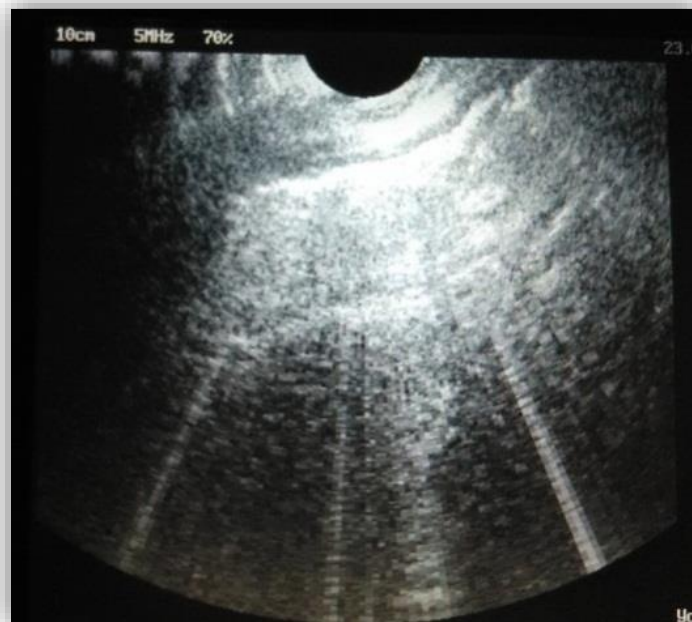


Figure 3. The boundary line between the abomasum and abdominal cavity immediately before the surgical intervention

It has been established that the use of ultrasound examination in the case of displacement of the abomasum in cows as well as traditional methods does not ensure 100% effectiveness. Nevertheless, ultrasound

allows accurately determining the intensity of the pathological process, with minimal impact of external factors affecting the quality of this diagnosis and the establishment of localization of surgical intervention.

In case of surgical treatment of the abomasum displacement in our work, we stopped at the three main surgical methods, namely the method of "puncture", the method of "suturing through the paralumbal fossa", and the method of "abdominal medial surgery".

The main tasks of each method is to return the abomasum to its physiologically correct position, and to ensure its reliable attachment. For an objective assessment of the efficacy of surgical treatment, we divided the ill animals into two groups: first heifers and cows.

The results of the treatment of the abomasum displacement are presented in Table 1 and Table 2.

It was established that the greatest degree of pathology is recorded in the first heifers. Thus, the occurrence of the left-sided displacement of the abomasum during the study period was observed in 75 first heifers and 31 cows.

During the study of the effectiveness of various methods of surgical treatment of the abomasum displacement, we noted both the advantages and disadvantages of each of the methods used.

Table 1. Effectiveness of various methods of surgical treatment of left-sided displacement of the abomasum in first heifers

Indicator	Method of treatment		
	Puncture method	Suturing through the paralumbal fossa	Abdominal medial surgery
Number of experimental animals, total	68	4	3
Animal healed, un.	57	3	2
Efficacy of treatment, %	83.82	75.00	66.67
Recurrent displacement, un.	11	0	0
Disposed as a result of complications, un.	4	1	1
%	5.88	25.00	33.33

Table 2. Effectiveness of various methods of surgical treatment of left-sided displacement of the abomasum in cows

Indicator	Method of treatment		
	Puncture method	Suturing through the paralumbal fossa	Abdominal medial surgery
Number of experimental animals, total	27	3	1
Animal healed, un.	22	3	0
Efficacy of treatment, %	81.48	100.00	0
Recurrent displacement, un.	5	0	0
Disposed as a result of complications, un.	4	0	1
%	14.82	0	100.00

Thus, the advantages of the puncture method are simplicity, due to the minimum access, quickness of the manipulations and minimum costs of treatment, while the success of the operation was 81.32% and 81.48% in the treatment of first heifers and cows, respectively. The disadvantages of this method include poor guidance during the operation (the abomasum is not visible), as well as inconvenient fixation of the animal (in the supine position).

Surgical treatment with suturing through the paralumbal fossa was characterized by a high success rate among experienced surgeons, a comfortable position of the animal during the operation (in a standing position), no relapses, visual access to the operated organ and direct suturing of the abomasum, and control of fixation.

The disadvantages of this method include a large surgical wound and the associated long-term postoperative recovery. It should be noted that the surgeon operating the animal must have certain physical characteristics subject to the long duration of the operation and need for physical strength and endurance, as well as long arms to grip the abomasum through the entire abdominal cavity.

The midline abdominal surgery is similar to puncture method and has a number of advantages, such as visualization of the abomasum, which allows it to be securely fixed, and fixing the animal in the dorsal position contributes to displacement of the abomasum to its anatomical position. Among the drawbacks are uncomfortable for the animal fixation in the dorsal position, and stress which can provoke an emetic reflex during operation. The use of abdominal surgery requires a long postoperative recovery, as well as an extensive surgical wound to access and, despite this, the impossibility of examining part of the abdominal cavity in this position.

CONCLUSION

Given the advantages and disadvantages of each of the compared methods of treatment, as well as a high incidence of left-sided displacement of the abomasum among the first heifers, it is most advisable to use a puncture method that is simple to perform, quick to implement, low invasive, ensures low recurrence rate and high efficiency (81.32% in first heifers and 81.48% in cows). In case of sufficient experience of the doctor and the capabilities of the farm facilities for the surgical treatment of cows and first heifers, treatment by suturing through the paralumbal fossa can be recommended.

REFERENCES

- [1] Anderson D., Gaughan E., St-Jean G.: Normal laparoscopic anatomy of the bovine abdomen. *Am. J. Vet. Res.* 1993, 54, 1170-1176.
- [2] Babkine M., Desrochers A., Bouré L., Hélie P.: Ventral laparoscopic abomasopexy on adult cows. *Can. Vet. J.* 2006, 47, 343-348.
- [3] Baird A. N., Harrison S.: Surgical Treatment of Left Displaced Abomasum. *Compend. Contin. Educ. Pr. Vet.* 2001, 23, 102-109.
- [4] Barisani C.: Evoluzione della tecnica di Janowitz per la risoluzione della dislocazione abomasale sinistra secondo Barisani. *Summa.* 2004, 5, 35-39.
- [5] Chasovshchikova M.A., Sheveleva O.M., Svjazhenina M.A., Tatarkina N.I., Satkeeva A.B., Bakharev A.A., Ponomareva E.A., Koshchaev A.G. Relationship between the genetic variants of kappa-casein and prolactin and the productive-biological characteristics of cows of the black-motley breed // *Journal of Pharmaceutical Sciences and Research.* 2017. Vol. 9. № 7. P. 1038-1044.
- [6] Connell J.: Four Methods of Surgical Correction of Abomasal Displacement in the Cow. *Iowa State Vet.* 1976, 38, 21-24.
- [7] Freick M.: Laparoscopic reposition of the displaced abomasum in a dairy herd in Saxony – a case series. *Tierarztl. Umsch.* 2013, 8, 311-321.
- [8] Glazunova L.A., Glazunov Yu.V, Ergashev A.A. Ecological-epizootical situation on telasiosis among large cattle in Northern Ural region. *Research Journal of Pharmaceutical, Biological and Chemical Sciences.* 2018. Vol. 9. Vol. 4. pp. 1687-1693.
- [9] Gnemmi G., Maraboli C.: Endoscopia bovina: dislocazione abomasale sinistra: approccio endoscopico one step con animale in stazione quadrupedale: valutazione retrospettiva. *Summa* 2006, 1, 11-21.
- [10] Gnus, Michal; Ratajczak, Kornel; Antosik, Pawel Application of a laparoscopic spieker of own design in reposition and fixation of the leftdisplacement of the abomasum (LDA) in cattle. *Medycyna weterynaryjna-veterinary medicine-science and practice.* Volume: 74 Issue: 2 Pages: 99-103
- [11] Janowitz H.: Laparoscopic reposition and fixation of the left displaced abomasum in cattle. *Tierarztl. Prax. Ausg. G. Grosstiere Nutztiere.* 1998, 26, 308-313.
- [12] Jorritsma R., Westerlaan B., Bierma M. P. R., Frankena K.: Milk yield and survival of Holstein-Friesian dairy cattle after laparoscopic correction of left-displaced abomasum. *Vet. Rec.* 2008, 162, 743-746.
- [13] Kelton D. F., Garcia J., Guard C. L.: Bar suture (toggle pin) vs open surgical abomasopexy for treatment of left displaced abomasum in dairy cattle. *J. Am. Vet. Med. Assoc.* 1988, 193, 557-559.
- [14] Mordak R., Nicpoń J.: Metabolic conditions of displacement of abomasum in cows. *Med. Weter.* 2015, 71, 142-145.

- [15] Mulon P. Y., Babkine M., Desrochers A.: Ventral Laparoscopic Abomasopexy in 18 Cattle with Displaced Abomasum. *Vet. Surg.* 2006, 35, 347-355.
- [16] Newman K. D., Anderson D. E., Silveira F.: One-step laparoscopic abomasopexy for correction of left-sided displacement of the abomasum in dairy cows. *J. Am. Vet. Med. Assoc.* 2005, 227, 1142-1147.
- [17] Newman K. D., Harvey D., Roy J. P.: Minimally invasive field abomasopexy techniques for correction and fixation of left displacement of the abomasum in dairy cows. *Vet. Clin. North. Am. Food. Anim. Pr.* 2008, 24, 359-382.
- [18] Niehaus A. J.: Surgery of the Abomasum. *Vet. Clin. North. Am. Food. Anim. Pr.* 2008, 24, 349-358.
- [19] Raizman E.A., Santos J.E.P. The effect of left displacement of abomasum corrected by toggle-pin suture on lactation, reproduction, and health of Holstein dairy cows/ *Journal of dairy Science* Vol. № 5 Pp.: 1157-1164. doi.org/10.3168/jds.S0022-0302(02)74178-7.
- [20] Roy J. P., Harvey D., Bélanger A. M., Buczinski S.: Comparison of 2-step laparoscopy-guided abomasopexy versus omentopexy via right flank laparotomy for the treatment of dairy cows with left displacement of the abomasum in on-farm settings. *J. Am. Vet. Med. Assoc.* 2008, 232, 1700-1706.
- [21] Sickinger M.: Clinic`c decade of LDA endoscopic repositioning techniques in cows. *Vet. Times.* 2014, 22, 18-20.
- [22] Staric J., Biricik H. S., Aksoy G., Zadnik T.: Surgical Treatment of Displaced Abomasum in Cattle Using Ljubljana Method. *Acta Vet. Brno* 2010, 79, 469-473.
- [23] Steiner A.: Surgical treatment of the left displacement of the abomasum an update. XXIV World Buiatrics Congress, Nice, France 2006.
- [24] Trent A. M.: Surgery of the bovine abomasum. *Vet. Clin. North. Am. Food. Anim. Pract.* 1990, 6, 348-399.
- [25] Trent A.: Surgery of the abomasum. *Farm animal surgery.* WB Saunders Co. 2004, 196-239.
- [26] Van Winden, SCL; Kuiper, R. Left displacement of the abomasum in dairy cattle: recent developments in epidemiological and etiological aspects. *Veterinary Research* Vol. 34 . № 1 P. 47-56 DOI: 10.1051/vetres:2002060/