

Research Journal of Pharmaceutical, Biological and Chemical Sciences

Comparative Pharmacodynamic And Histopathological Studies On Tetracycline Loaded Nanoemulsion And Tetracycline In Rabbits.

Mohamed S Saber¹, Aziza M Amer², Shymaa A El-Badawy², Ahmed M Othman³, Omar A Ahmed-Farid⁴, Mohamed M Amer⁵

¹PhD student in Pharmacol., Vet.Service division, Ministry of Defense, Egypt.

²Dept. of Pharmacol., Facult. Vet.Med., Cairo University, Giza, Egypt.

³Dept. of Pathol., Facult. Vet.Med., Cairo University, Giza, Egypt.

⁴Physiol. Dept. NODCAR, Giza, Egypt.

⁵Dept. of Poult.Dise.,Facult. Vet.Med., Cairo University, P.O. 12211, Giza, Egypt.

ABSTRACT

This study is a comparative evaluation of pharmacodynamic and histopathological effect of prepared tetracycline nanoemulsion (TC-nm) and tetracycline hydrochloride (TC-hcl) in New Zealand male rabbits orally in dose 50 mg/kg b.wt for 7 days. Blood and tissue samples were collected for determination of function parameters and histopathological examination. Liver enzymes ALT, AST and T.bil in sera of rabbits given TC-nm (98.80±6.40, 119.80±5.56 and 0.86±0.05) were higher than those given TC-hcl (89.40±1.37, 118±1.79 and 0.72±0.09) and both significantly higher than nontreated control (20.80±0.75, 18.60±1.36 and 0.58±0.08). Kidney function including creatinine and Urea (0.84±0.05 and 40.0±1.67) of TC-nm are higher than those of TC-hcl (0.68±0.08 and 23.60±0.80) and were significantly higher than control group (0.58±0.02 and 23.00±1.41); respectively). Drug tissue concentration by microbial assay in liver, kidney, lung and muscle from TC-nm and TC-hcl treated groups at 1, 2, 3, and 4 days after the last dose revealed that highest concentration of TC-hcl residues at 1 day in lung, liver, kidney and breast muscles were 0.334±0.041, 0.190±0.031, 0.031±0.003, 0.012±0.001 µg/g, respectively. At 2 and 3 days TC-hcl was detected in lung (0.200±0.041 and 0.198±0.053 µg/g) higher than liver (0.175±0.017 and 0.077±0.009 µg/g). TC-nm highest concentration was detected at 1 day in lung (0.555±0.036 µg/g) followed by liver (0.425±0.074 µg/g), kidney (0.047±0.004 µg/g) and muscles (0.022±0.001 µg/g). At 2 days higher concentration was in lung (0.434±0.050 µg/g) than liver (0.306±0.057 µg/g), while it was higher in liver (0.192±0.014 µg/g) than lung (0.112±0.009 µg/g). Using HPLC the highest concentration of TC-hcl residues at 1 day was found in lung (0.370±0.043 µg/g), liver (0.244±0.030 µg/g), kidney (0.037±0.005 µg/g) followed by muscles (0.024±0.002 µg/g). At 2 and 3 days TC-hcl level was higher in lung (0.243±0.050 and 0.087±0.003 µg/g) than liver (0.196±0.011 and 0.102±0.006 µg/g); respectively. TC-nm highest concentration was detected at 1 day in lung (0.609±0.036 µg/g) followed by liver (0.553±0.096 µg/g), kidney (0.053±0.004 µg/g) and muscles (0.031±0.003 µg/g). At 2 days higher concentration was in lung (0.467±0.047 µg/g) than liver (0.357±0.058 µg/g). Drugs were not detected in both kidney and muscles at 2 and 3 days as well as in all tested tissues at 4 days. Histologically, TC-hcl resulted in liver disorganization of hepatic cord, narrowing of hepatic sinusoids, hyperplasia of Kupffer cells, granularity of cytoplasm and vesiculation in hepatocytes nuclei. Hypercellularity of capillary tufts with proliferation of many cells, congestion of perialveolar and peribronchial capillaries were seen in kidney. Intermuscular edema with wide spaces in-between cardiac muscle bundles and necrosis of some bundles were recorded. It can be concluded that tetracycline and tetracycline nanoemulsion formulation oral administration in rabbit affect liver and kidney function, tissue residues can be reached to the undetected level in all organs at 4 days from the last dose. Nanoemulsion formulation of tetracycline increases its pharmacodynamics but it was less safe than normal tetracycline.

Keywords: Tetracycline, nanoemulsion, tissue residue, microbiology, HPLC, Histopathology, Rabbit.

**Corresponding author*

INTRODUCTION

Tetracyclines were discovered in the 1940s and had activity against gram-positive and gram-negative bacteria, chlamydiae, mycoplasmas, rickettsiae, and protozoan parasites. Furthermore, Tetracyclines still inexpensive antibiotics, which have been used in the both prophylaxis and therapy in bacterial infections of human and animal, and subtherapeutic levels are added in animal feed as growth promoters [1, 2]. The tetracyclines are still considered a clinically relevant group of antibiotics, though dissemination of tolerance and resistance determinants has limited their use [3].

Nanoemulsions formulations are used for the improvement of drug delivery system [4-6]. Tetracycline hydrochloride Nanoemulsions were prepared and their antimicrobial efficacy was also tested by many authors [7-10].

Long term administration of tetracycline can induce effect in liver and kidney functions in form of increased free and conjugated bilirubin, serum glutamic oxaloacetic transaminase (SGOT), and alkaline phosphatase [11-16]. The histological examination of kidney showed shrinkage of glomeruli and tubular protein deposits and marked fat infiltration in the liver of rats treated with the oxytetracycline (37.5 and 75 mg/kg/day) or tetracycline (75 mg/kg/day) intraperitoneally for four days [17]. Two doses of Tetracycline at 50 and 200 mg/kg daily affect pancreatic and liver tissue function for 14 and 21 days in adult male albino rats [18].

Tissue distribution of tetracyclines in canine after repeated oral administration [19], intrapulmonary concentrations in healthy or cancerous human [20], residues in tissues of slaughtered animals (cattle: 9, hog: 30) where, kidney samples showed higher incidence of TCs residues and 1.6-6.9 times higher residual concentrations than liver samples [21]. Tetracyclines residues was reported to induce harmful effects on consumers as liver damage, allergic reactions, yellowing of teeth and gastrointestinal disorders [22]. Ten adult white Californian rabbits (males and females) received a single oral dose of 20 mg/kg bw of technical CTC or CTC-chloride highest concentrations were found in the liver (1.53 mg/kg) 24-h post-dosing, followed by kidney, lung and heart. No measurable levels were found in muscle the detection limit was 37.5 µg/kg [23]. Residue depletion of oxytetracycline was determined in rabbit meat using high performance liquid chromatography (HPLC) [24]. Sensitive and specific high-performance liquid chromatography (HPLC) method based upon laser-based polarimetric detection for the determination of tetracycline analogues was developed [25] and optimized and validated [26].

The available literature don't satisfactory explore the effect of Tetracycline hydrochloride nanoemulsions on liver and kidney function as well as structural changes and residues concentration in tissues or effect on tissue structure.

Therefore this study was planned to carry out a comparative evaluation of Pharmacodynamic, effect on liver and kidney function and histopathological effect of prepared tetracycline nanoemulsion (TC-nm) formula with tetracycline hydrochloride (TC-hcl) and in rabbits.

MATERIAL AND METHODS

Tetracyclines:

a. Tetracycline-loaded nanoemulsions (TC-nm):

Certain systems were selected and formulated by mixing specified weight ratios of oil (10, 15 and 20%, w/w), a fixed S/CoS concentration (50%, w/w) and water (40, 35 and 30%, w/w), respectively [27]. Tetracycline-loaded nanoemulsions (5%, w/w) were formulated and preserved with sodium benzoate (0.01%, w/w). The used TC-nm in this study was prepared and characterized by Amer - Aziza et al. [28].

b. Tetracycline hydrochloride (TC-hcl).

Tetracycline hydrochloride was obtained as pure powder 100% from El-Nasr pharmaceutical chemicals Co. (Abu Zaabal, Egypt).

Samples

a. Blood Samples:

Blood samples for chemical analysis and enzymes activities wascollected and used for the determination of alkaline phosphates (ALP) [29], aspartate aminotransferase (AST), alanine aminotransferase (ALT) [30], Total protein (T.P), and total Bilirubin (T.Bill).

b. Tissues for detection of drug concentration:

Liver, kidney, lung and muscletissue samples were taken at 1, 2, 3 and 4 day after stop of oral administration (50 mg/kg b.wt for 7 successive days) of the two formulas for determination of tetracycline concentration and withdrawal time.

c. Tissues for histopathology:

Liver, kidney, lung and cardiac musclesamples were taken after oral administration of the two formulas (50 mg/kg b.wt for 7 successive days) for histopathological examination; samples were kept in 10% formalin for histological examination.

Groups and administration:

White male New Zealand rabbits weighing 3- 4 kg/each were housed in laboratory animal housing facilities at faculty of veterinary medicine, Cairo University. The rabbits feed on commercial diet and water ad libitum. After 1 week accommodation rabbits were randomly divided into 5 groups. Animals of groups 1, 2 and 3 (5 animals each), animals of group 1 were given the adjuvant as control (0.5 ml/kg b. wt for 7 successive days), animals of group 2 and group 3 were given TC-nm and TC-hcl(50 mg/kg b.wt oral for 7 successive days), respectively) for determination of the effect on liver and kidneys function and Liver, kidney, lung and cardiac musclehistopathology. Animals of group 4 and 5 (12 animals each) were given TC-nm and TC-hcl(50 mg/kg b.wt orally for 7 days) for determination of tissue (Liver, kidney, lung and muscle) concentration and withdrawal time.

HPLC determination of chlortetracycline in tissues:

Sample preparation: preparation of liver, kidney, lung and muscle tissue samples were done via HPLC technique [26]. The extraction was done via citrate buffer (pH4) plus trichloroacetic acid (80:20%), followed by centrifugation then using 0.01 M methanolic oxalic acid for elution.

Chromatographic conditions:

Column used to determination tetracycline hydrochloride was Zorbax SB-C18, 3.5 μ m, 4.6X75mm, Mobile phase: A: 0.025 MKH₂PO₄ in H₂O with pH 3 and B: CAN, gradient at 5%Bto 60% B in 10 min then 60% B to 5% B in 2min, wavelength was 350 nm detection; flow rate 1ml/min and Temperate 25 °C. Limit of detection (LOD) and limit of quantification (LOQ) were found to be 10 and 30 ng; respectively.

Microbiological determination of chlortetracycline in tissues:

Tetracycline levels in tissues were determined on tissue homogenates prepared in phosphate buffer. A 0. 1 molar monobasic potassium phosphate buffer pH 4.5 was added to the tissue in a 1:1 ratio (weight to volume) and a homogenate was produced using a glass screw capped, Dual tissue grinder. Tissue drug concentrations were determined from a standard curve prepared daily containing known amounts of drug and tissue homogenate. Tissue homogenate were assayed for the presence of tetracycline using the plate disk method as previously described byArret et al. [31].Cultures of Bacillus cereus varmycoides ATCC 1177815 (Difco Laboratories, Detroit, Michigan), freshly prepared, were used as the test organism in antibiotic assays. All tests were done in duplicate, including standard controls. The minimum level of sensitivity of the assay was 0.07 μ g/ mL of serum. Tissue homogenate samples with drug levels lower than this were recorded as undetected.

Histopathological examination:

Liver, kidney, lung and cardiac musclespecimens were fixed in 10% neutral buffered formalin. The fixed specimens were then trimmed, washed and dehydrated in ascending grades of alcohol, cleared in xylene, embedded in paraffin, sectioned at 4-6U thickness and stained by hematoxylin and eosin [32].Histological grading of liver [33] and kidney [34]were recorded as shown in the following tables.

Grade	Grade Description of liver
0	No apparent injury by light microscopy
I	Swelling of hepatocytes
II	Ballooning of hepatocytes
III	Lipid droplets in hepatocytes
IV	Necrosis of hepatocytes

Score	Grading System for Renal Lesions
0	Normal histology
1	Tubular epithelial cell degeneration, without significant necrosis or apoptosis
2	Tubular epithelial cell necrosis and apoptosis <25%
3	Tubular epithelial cell necrosis and apoptosis <50%
4	Tubular epithelial cell necrosis and apoptosis <75%
5	Tubular epithelial cell necrosis and apoptosis ≥ 75%

Statistical analysis:

Data was presented as mean ± SD. Selected liver and kidney function values were compared for IV and oral administration of tetracycline using mixed models analysis of variance and a compound symmetry covariance matrix (PROC MIXED, SAS 9.2, SAS Inc, Cary, NC). A P value <0.05 was considered significant.

RESULTS AND DISCUSSION

Tetracyclines are still low price antibiotics and extensively in the prophylaxis and therapy of animal infections and in animal feed as growth promoters [1-3]. This pharmacodynamics study was done in rabbits which reared as source of human protein. Liver and Kidney function test in treated and control groups (Table, 1)

The obtained results showed that the liver enzymes ALT, AST and T.bill in sera of rabbits given TC-nm in dose of 50 mg/kg for 7 days (98.80±6.40 119.80±5.56 and 0.86±0.05) were higher than those give the same dose of HC-hcl (89.4 0± 1.37, 118±1.79 and 0.72 ± 0.09) and both were elevated significantly than nontreated control (20.80± 0.75, 18.60 ±1.36and 0.58 ± 0.08). The obtained results showed that the treatment of rabbits with tetracycline 50 mg/kg daily for 7 Successive days, significant increase in liver enzymes (ALT and AST) on the 7th days after administration of TC-hcl as compared with nontreated control are in agreement with those obtained by Abdel Aziz et al.[16]following oral dose of tetracycline (35 mg/kg BW once daily) for five successive in rabbits, Shabana et al.[35] registered a significant increase in the levels of ALT and AST in the serum of tetracycline-administrated rats. Increasing the level of liver enzymes in the serum may be attributed to necrotic lesions induced by tetracycline in the hepatocytes [36] and oxidative damage which might result in an enhanced release of ALT and AST into the general circulation. In addition to the elevation of the AST and ALT levels refers to a reversible change of the cell membrane permeability [37]. Also, Hunt and Washington [38]found a significant increase in AST and ALT levels in the serum of female patients treated with tetracyclines for 2 months.

The Kidney function results including creatinine and Urea (0.84±0.05 and 40.0 ± 1.67) of TC-nm are higher than those of TC-hcl (0.68 ±0.08 and 23.60± 0.80) and both were elevated significantly than nontreated control group 1 (0.58± 0.02 and 23.00± 1.41); respectively.). The obtained results showed that the treatment of rabbits with tetracycline 50 mg/kg daily for 7 Successive days, significant increase kidney function (creatinine and urea) on the 7th. day of TC-hcl administration of as compared with non treated control. Our results are in agreement with significant increase in the level of urea and creatinine in the serum of

tetracycline-treated rats [16, 39-41] and rabbits [16], also, Zallen [42] recorded significant increases in the levels of serum bilirubin and urea in mice after treatment with tetracycline. The toxic effect of tetracycline on kidney may have prohibited the filtration of the waste products (urea and creatinine) from the bloodstream [43].

Table 1: Liver and Kidney function test in treated rabbits with nanoemulsions tetracycline (TC-nm), tetracycline (TC-HCl) and adjuvant control groups at 7th day of treatment (Mean ± SD, n=5)

Group	Drug	Creatinine(mg/dL)	Urea (mg/dL)	ALT (U/L)	AST (U/L)	T.Bill
		Mean ± SD	Mean ± SD	Mean ± SD	Mean ± SD	Mean ± SD
1	Adjuvant	0.58 ± 0.02	23.00 ± 1.41	20.80 ± 0.75	18.60 ± 1.36	0.58 ± 0.08
2	TC-hcl	0.68±0.08 ^a	23.60 ± 0.80	89.4 0± 1.37 ^a	118 ± 1.79 ^a	0.72 ± 0.09 ^a
3	TC-nm	0.84±0.05 ^b	40.0 ±1.67 ^a	98.80±6.40 ^b	119.80 ± 5.56 ^a	0.86±0.05 ^b

^{a, b}; means of different treatment with different superscripts are significantly different at (P ≤ 0.05)

Tissue residues:

HPLC assays method is available for most of tetracycline members [31, 44, 45], but many investigators have used microbiological assays [32, 46, 47].

Tissue concentration using the microbiological (MC) method:

Tissue concentration of tetracycline was determined using the MC [32] method in groups treated with TC-nm and TC-hcl (50 mg/kg b.wt orally for 7 successive days) at 1, 2, 3 and 4 days after stop administration. The highest concentration of TC-hcl residues (Table 2, Fig 1) at 1 day was found in lung, liver, kidney and breast muscles in rate of, 0.334 ± 0.041, 0.190 ± 0.031, 0.031 ± 0.003, 0.012 ± 0.001 µg/g (Table 2), respectively. At 2 and 3 days TC-hcl was detected in higher decline levels in lung (0.200 ± 0.041 and 0.198 ± 0.053 µg/g) than liver (0.175 ± 0.017 and 0.077 ± 0.009 µg/g); respectively; while it was not detected in both kidney and muscles. TC-nm highest concentration was detected at 1 days in lung (0.555 ± 0.036 µg/g) followed by liver (0.425 ± 0.074 µg/g), kidney (0.047 ± 0.004 µg/g) and muscles (0.022 ± 0.001 µg/g). At 2 days it was detected in higher concentration in lung (0.434 ± 0.050 µg/g) than liver (0.306 ± 0.057 µg/g), while it was higher in liver (0.192 ± 0.014 µg/g) than lung (0.112 ± 0.009 µg/g). Drugs were not detected in kidney and muscles at 2 and 3 days (Table 2, Fig 1) as well as all tested tissues at 4 days.

Tissue concentration using HPLC method:

The highest concentration of TC-hcl residues [31] at 1 day (Table 2, Fig 1) was found in lung (0.370 ± 0.043 µg/g), liver (0.244 ± 0.030 µg/g), kidney (0.037 ± 0.005 µg/g) followed by breast muscles (0.024 ± 0.002 µg/g) (Table, 2). At 2 and 3 days TC-hcl was detected in higher levels in lung (0.243 ± 0.050 and 0.087 ± 0.003 µg/g) than liver (0.196 ± 0.011 and 0.102 ± 0.006 µg/g); respectively; while it was not detected in both kidney and muscles. TC-nm highest concentration was detected at 1 day in lung (0.609 ± 0.036 µg/g) followed by liver (0.553 ± 0.096 µg/g), Kidney (0.053 ± 0.004 µg/g) and muscles (0.031 ± 0.003 µg/g). At 2 days it was detected in higher concentration in lung (0.467 ± 0.047 µg/g) than liver (0.357 ± 0.058 µg/g) (Table 2, Fig 1), while it was higher in liver (0.217 ± 0.026 µg/g) than lung (0.146 ± 0.014 µg/g).

In comparing the obtained results tetracycline tissue residues were detected in higher rates using HPLC than the microbiological method, TC-nm induced higher tissue residue than TC-hcl and both muscles and kidney having undetected levels at 9 and 10 days (Table 2, Fig 1). All samples having undetected levels at 4 days. Concentrations detected by MC are lower than HPLC. The result can be explained by Ferrero et al. [48] who stated that the bioassay technique has the advantage of only measuring active amounts of the antibiotic.

The detected HC-hcl concentration in tested tissues proved that liver showed higher values than kidney and muscles showed the lost at 1 day after treatment. Abdel-Mohsein et al. [49] detected a significant difference between the level of TC in liver and muscle of broiler chickens, while non-significant difference between TC level in liver and kidney, and the liver had the highest level of TC residue in comparison to other samples. The mean level of TC residues was the highest in the kidney samples that may be due to the major

elimination pathway of tetracycline through renal excretion with approximately 60% of tetracycline administered being excreted in urine in unchanged form [50]. Meanwhile, a higher level of tetracycline residue usually observed in liver and kidney rather than in the muscle, which is explaining their role in the metabolism and excretion of antibiotics, as well as to the role of the kidney in the filtration and clearance of blood from any undesirable constituents [51]. The intrapulmonary concentration of tetracycline is increased in rat lungs infected by *Legionella pneumophila*[20].The high lung concentration can attribute to the high of tetracycline or to the damage in liver and kidney [52, 53].

Muscles and kidney showed undetected drug levels at 2 and 3 days, while all samples showed undetected drugs in both TC-nm and TC-hcl at 4 days.The obtained results pointed out that TC-hcl withdrawal time can be less than 2 days after the last dose from muscles and kidney while lung and liver can be 4 days. The result agree with Abdel Aziz [16]who reported residues remained in the liver and kidney for 7 days, while in muscles for 3 days only after the last oral dose of the drug. Villa et al. [54]found that the withdrawal time of oxytetracycline preparation when given to rabbits by medicating water or feeding for five days at dose 80mg/kg may be not more than 3 days. Highest CTC concentrations were found in the liver (1.53 mg/kg) 24-h post-dosing, followed by kidney, lung and heart of rabbits, while no measurable levels were found in muscle [26]. Our results were in disagreement with Morshedy et al. [24] who recommended that slaughter of rabbit treated with oxytetracycline (20 mg/kg bw) subcutaneously for 5 successive days must be dallied till is metabolized in liver and excreted from the kidneys and this takes a withdrawal period about 3 weeks muscles.. Also, Martin-jimenez et al. [55]reported that the concentrations of oxytetracycline persisted in the kidneys and muscle at the injection site for >19 days after oxytetracycline administered at 20mg/kg for 3 successive days.

Otherwise, the detected higher drug concentrations in tetracycline formulated TC-nm after oral administration as compare with animals given TC-hcl. The results of this study suggest that Nanoemulsions are promising novel formulations which can promote the oral bioavailability of hydrophobic drugs [56-59].

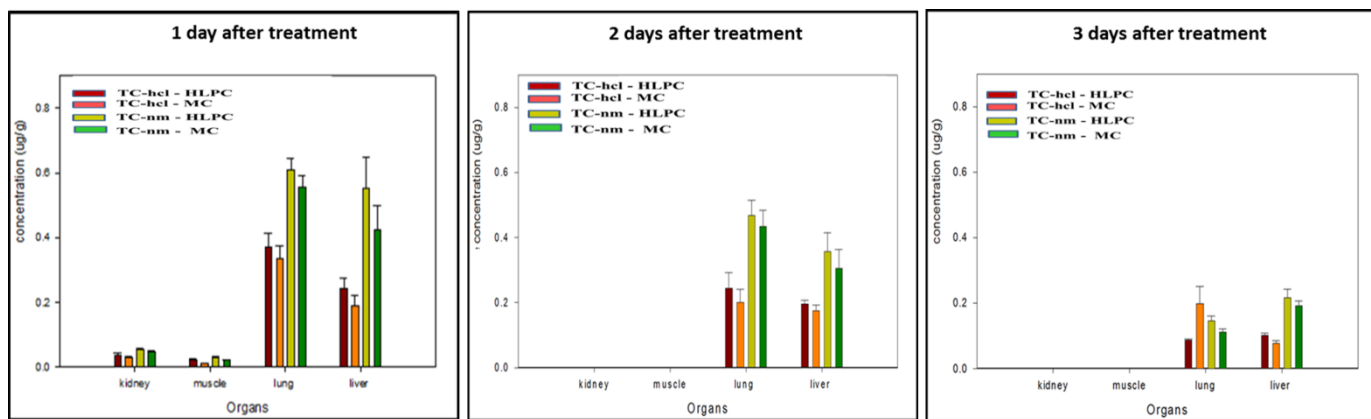
Table 2 : Microbiologically (MC) and HPLC results of tetracycline (TC-HCl) and nanoemulsions tetracycline (TC-nm) tissue concentration (µg/g) in treated groups at 1-4 days after stop administration (Mean ± SD, n=3).

Drug	Days	Micro				HPLC			
		Liver	Kidneys	Lung	Muscle	Liver	Kidneys	Lung	Muscle
		Mean ± SD	Mean ± SD	Mean ± SD	Mean ± SD	Mean ± SD	Mean ± SD	Mean ± SD	Mean ± SD
TC-HCl	1	0.190 ± 0.031	0.031 ± 0.003	0.334 ± 0.041	0.012 ± 0.001	0.244 ± 0.030	0.037 ± 0.005†	0.370 ± 0.043	0.024 ± 0.002††
	2	0.175 ± 0.017	ND	0.200 ± 0.041	ND	0.196 ± 0.011	ND	0.243 ± 0.050	ND
	3	0.077 ± 0.009	ND	0.198 ± 0.053	ND	0.102 ± 0.006	ND	0.087 ± 0.003	ND
	4	ND				ND			
TC-nm	1	0.425 ± 0.074**	0.047 ± 0.004**	0.555 ± 0.036**	0.022 ± 0.001**	0.553 ± 0.096**†	0.053 ± 0.004**†	0.609 ± 0.036**†	0.031 ± 0.003**††
	2	0.306 ± 0.057**	ND	0.434 ± 0.050**	ND	0.357 ± 0.058**	ND	0.467 ± 0.047**	ND
	3	0.192 ± 0.014**	ND	0.112 ± 0.009	ND	0.217 ± 0.026**	ND	0.146 ± 0.014	ND
	4	ND							

*,** significantly different compared to TC-HCl at (P ≤0.05 and p≤0.005, respectively)

†, ††significantly different compared to TC-HCl at (P ≤0.05 and p≤0.005, respectively)

Fig 1: Microbiologically (MC) and HPLC of tetracycline (TC-hcl) and nanoemulsions tetracycline (TC-nm) tissue concentration (µg/g) in treated groups at 1-4 days post stop treatment (Mean ± SD, n=3).



Histopathology:

Liver, kidney, lung and cardiac muscle H&E stained tissue section of rabbit (Group 1) received oral adjuvant for 7 successive days:

Liver of animals exposed to adjuvant showed ballooning of hepatic cells, narrowing of hepatic sinusoids and hyperplasia of Kupffer cells. Mononuclear cells mainly lymphocytes and macrophages were infiltrated the portal area (Fig., 2). Some cells showed intracellular lipid droplets(grade II) (Fig., 3). Kidneys showed normal histological structure of glomeruli (Fig.,4). The renal tubules of both proximal and distal convoluted tubules showed intact epithelial lining and arrangement scoring (0) (Fig., 5). Lung tissue showed hyperplastic changes of bronchial epithelial lining with sloughing of some epithelial cells in its lumen. Mild congestion of perialveolar and peri-bronchial blood capillaries were seen (Fig., 6). Cardiac muscle showed mild intermuscular edema without marked intermuscular necrosis (Fig.,7).

Liver, kidney, lung and cardiac muscle H&E stained tissue section of rabbits (Group 3) received oral 50 mg/kg BW of tetracycline powder for 7 successive days:

Liver showed disorganization of hepatic cord, ballooning of hepatic cells and narrowing of hepatic sinusoids and hyperplasia of Kupffer cells (Fig., 8). Granularity of cytoplasm and vesiculation of hepatocytes nuclei were also seen. (Grade II) (Fig., 9). Similar liver lesions were detected by Machado et al. [60] where tetracycline administered to rats liver showed vacuolization, necrosis, inflammation and sinusoidal dilatations, more evident in the newborn. Mitosis, early increase of Kupffer cells population and hipertrophy of hepatocytes. Also, in off springs of rats, the presence of fluorescent bands in dentin and enamel, in both the incisors and molars, were evident after the use of the drug [61,62]. Hepatic vacuolization and slight increase of collagen fibers between the hepatocytes were detected in rat's liver [35, 63-65]. In pregnant rats and guinea-pigs the administration of tetracycline resulted in fatty degeneration of hepatic cells [65, 67], and in dogs, the microscopic changes were degeneration and tubular necrosis in the kidney [68], fatty accumulation in the hepatocytes, dose-dependent [69]. While Calves that used oxytetracycline did not present hepatocellular degeneration [70].

Kidneys showed hypercellularity of capillary tufts with proliferation of many cells include mesangial, endothelial and visceral epithelial cells (Fig., 10). Renal tubules showed epithelial cell degeneration, with significant tubular epithelial cell necrosis and apoptosis <50% scoring (3) (Fig., 11). Machado et al. [60] reported that kidney of rat offspring showed slight tubular vacuolizations and necrosis, more prominent in the newborn when tetracycline administered to rats on the 10th day of pregnancy. Tetracycline caused vacuolar degeneration in kidney in adult rats [17, 35, 71]. In dogs, the microscopic changes including degeneration and tubular necrosis in the kidney were reported [68], and calves given oxytetracycline showed tubular nephrosis [70]. Transient tubular nephropathy with cellular debris and figure of mitosis were also seen [72].

Lung showed congestion of perialveolar and peri-bronchial capillaries (Fig., 12). Multiple emphysematous areas with giant alveoli were noticed (Fig., 13). Cardiac muscle revealed intermuscular edema which characterized by wide spaces in-between muscle bundles (Fig., 14). Necrosis of some muscle bundles were appeared deeply eosinophilic (Fig., 15).

Liver, kidney, lung and cardiac muscle H&E stained tissue section of rabbit (group 2) received oral 50 mg/kg BW of Nano –tetracycline for 7 successive days:

Liver of treated animals showed swelling of hepatocytes and granularity of its cytoplasm (Fig., 16) narrowing of hepatic sinusoids and hyperplasia of Kupfer cells were seen [61, 62]. Apoptosis of hepatocytes in the centrilobular zone which appeared as deeply eosinophilic bodies were also noticed (Grade IV) (Fig., 17). Kidney tissue section showed hypercellularity of glomerular tufts and narrowing of Bowman's spaces (Fig., 18). The renal tubules showed epithelial cell degeneration, without significant necrosis or apoptosis (Scoring 1) (Fig., 19) [17, 35, 60, 70, 71]. Lung tissue section showed congestion perialveolar and peri-bronchial blood capillaries (Fig., 20). Few emphysematous areas with giant alveoli formation were observed (Fig., 12). Cardiac muscle revealed intermuscular edema and widening in between muscle bundles without significant necrosis (Fig., 22-23).

Liver, kidney, lung and cardiac muscle H&E stained tissue section of rabbit of control group received oral Adjuvant showing:

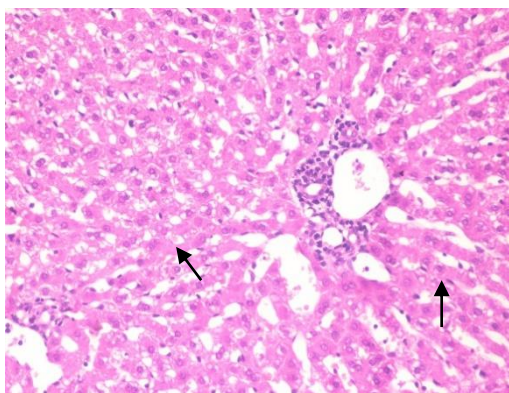


Fig (2) Liver: ballooning degeneration of hepatic cells and leukocytic infiltration of portal area arrow(X100).

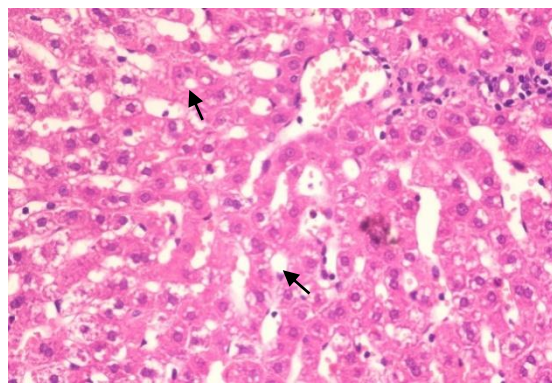


Fig (3) Liver: intracellular lipid droplets arrow(X200).

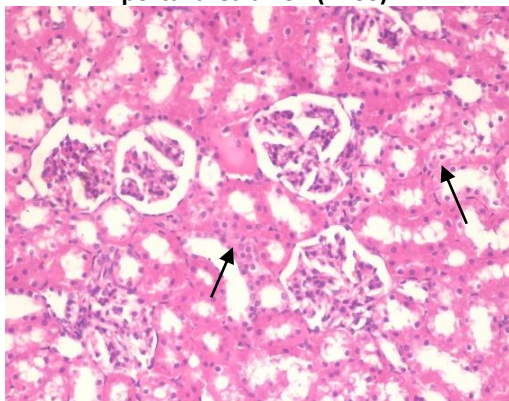


Fig (4) Kidney: normal histological structure of tubular epithelial lining arrow(X100).

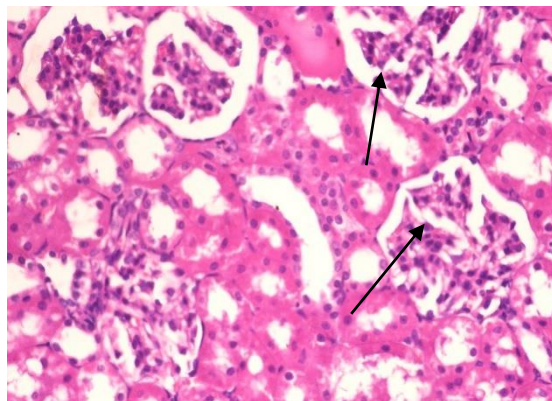


Fig (5) Kidney: normal histological structure of glomeruli arrow(X200).

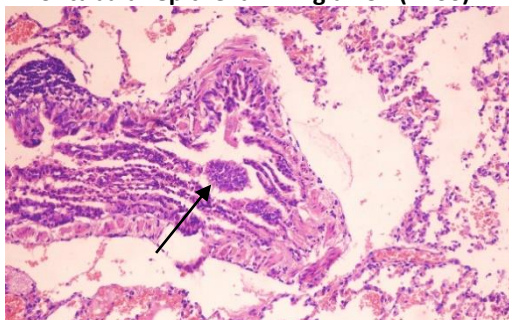


Fig (6) Lung: hyperplastic changes of

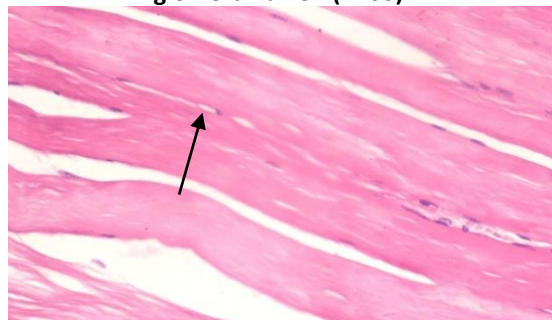


Fig (7) Cardiac muscle: tissue section showing

bronchial epithelial lining with sloughing of some epithelial cells in its lumen arrow(X200).

mild intermuscular edema arrow(X200).

Liver, kidney, lung and cardiac muscle H&E stained tissue section of rabbit received oral 50 mg/kg BW of tetracycline Powder showing:

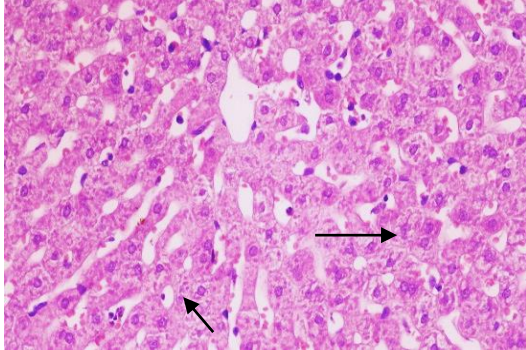


Fig (8) Liver: ballooning and granularity of hepatic cells arrow(X100).

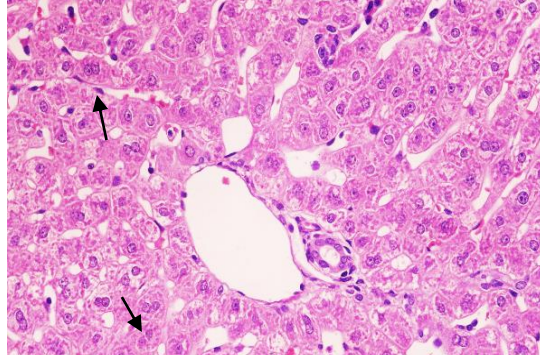


Fig (9) Liver: narrowing of hepatic sinusoids and hyperplasia of Kupffer cells arrow (X200).

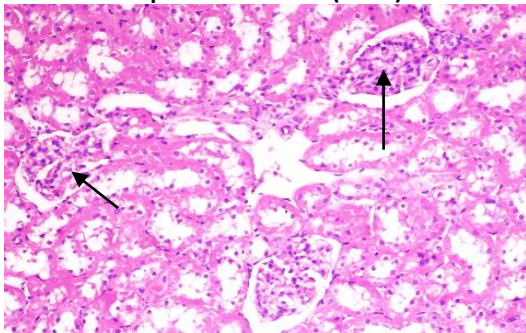


Fig (10) kidney: hypercellularity of glomerular tufts arrow(X100).

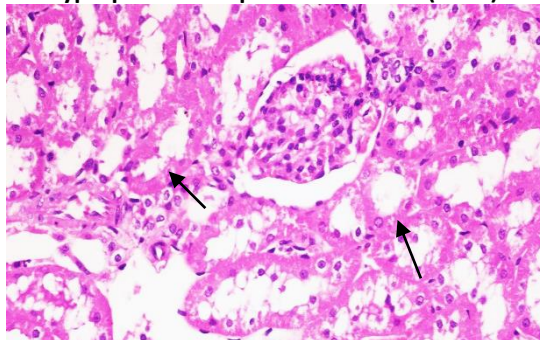


Fig (11) kidney: degeneration of tubular epithelial lining arrow(X200).

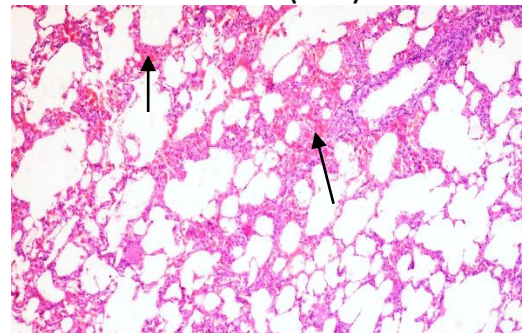


Fig (12) Lung : congestion of perialveolar and peri-bronchial blood capillaries arrow(X100) .

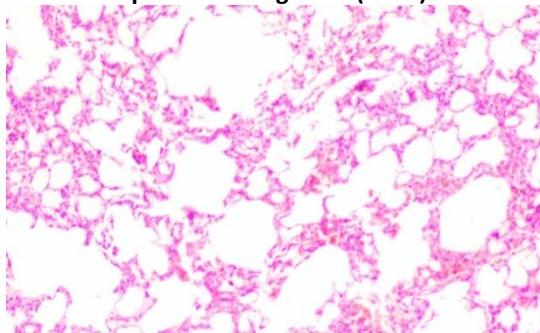


Fig (13) Lung: multiple emphysematous areas arrow(X200).

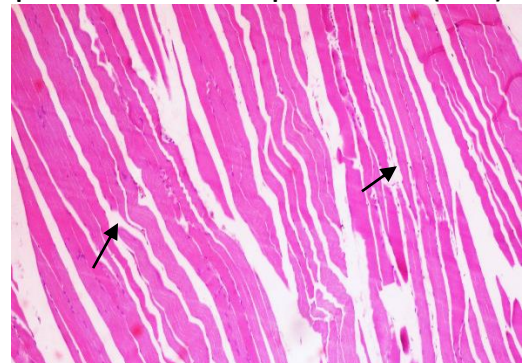


Fig (14) cardiac muscle: intermuscular oedema arrow(H&Ex100).

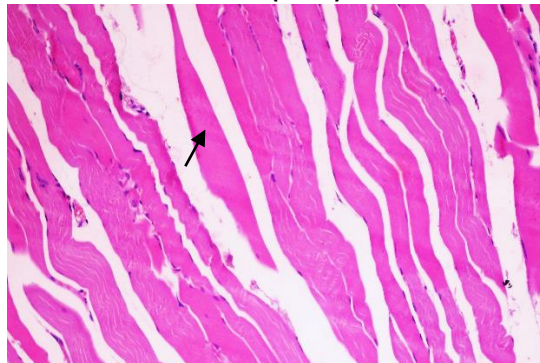


Fig (15) cardiac muscle: necrosis of muscle bundles arrow(X200).

Liver, kidney, lung and cardiac muscle H&E stained tissue section of rabbit received oral 50 mg/kg BW of Nano-tetracycline showing:

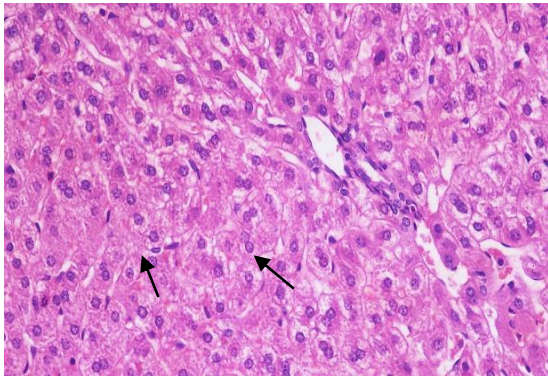


Fig (16) Liver: swelling of hepatocytes and narrowing of sinusoids arrow(X 100).

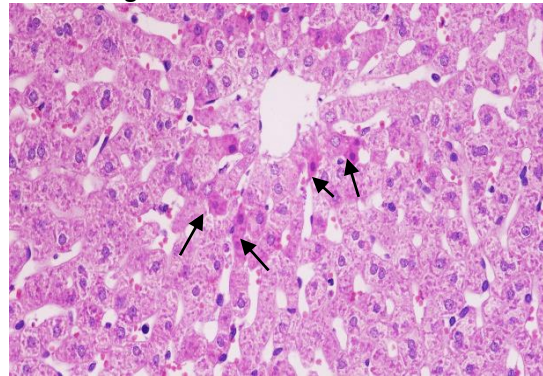


Fig (17) Liver:centrolobular apoptotic bodies arrow(X200).

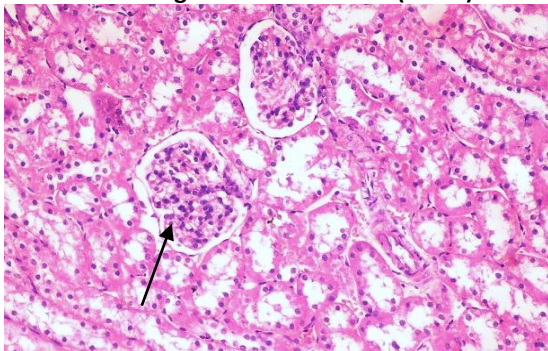


Fig (18) Kidney:hypercellularity of glomerular tufts arrow(X100).

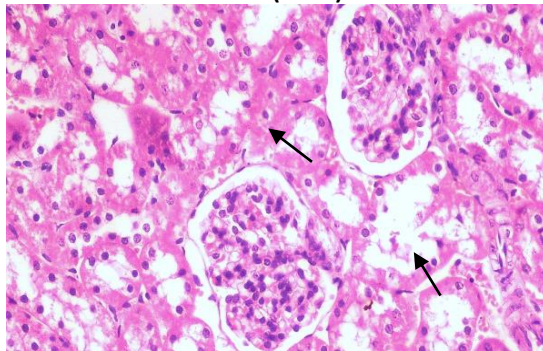


Fig (19) Kidney: degeneration of tubular epithelial lining arrow(X 200).

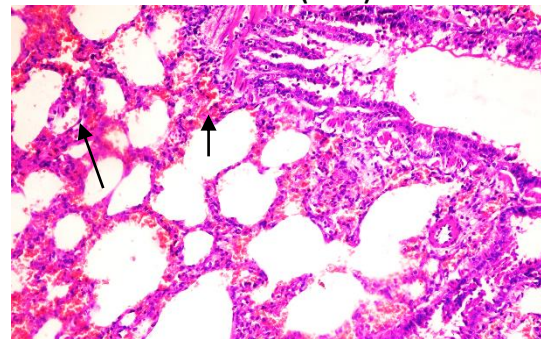


Fig (20) Lung: congestion of perialveolar capillaries arrow(X100).

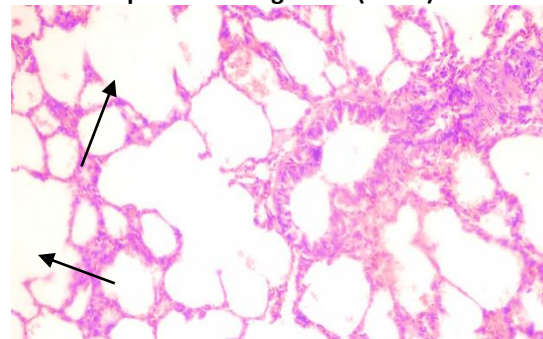


Fig (21) Lung: focal emphysematous area arrow(X200).

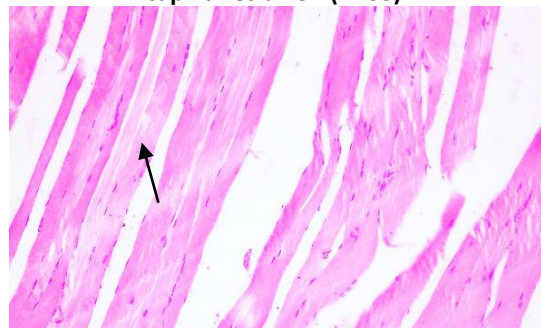


Fig (22) Cardic muscle: intermuscular oedema arrow(X100).

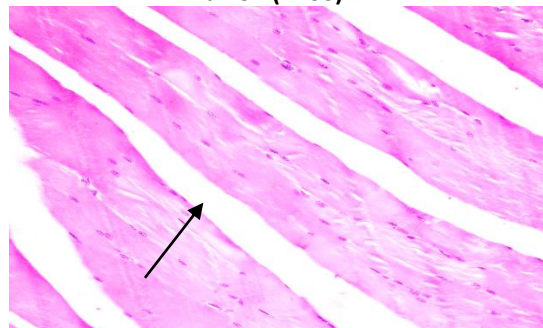


Fig (23) Cardic muscle: wedging spaces in between muscle bundles arrow(X200).

No available literature about the effect of tetracyclines on histological structure of lung tissue and heart muscles. But the detected lesions can be explained by clinical sign reported in dog given adose of 150

mg/kg bw caused respiratory distress, general paresis, somnolence and death within a few hours [73], final mean body weight was slightly decreased in males mice (16%) and females (6%) at the 5% level by TC hydrochloride [74], atrophic changes in skeletal muscle in dog [75], in rabbit slowing of the heart rate (from 270-300 (normal) to 100 beats/min or less) was observed 1-3 min after the injection and respiration was depressed which led at high doses to respiratory arrest or to a slow, shallow respiration for 1-2 min [76].

Comparing histopathological changes in examined tissue sections proved that TC-nm formula induced less and milder lesions than TC-hcl in rabbits, this result can prove the efficacy and safety of nanoemulsion formula in drug delivery [4-6, 77-79]. Taken in consecration and comparing the obtained results those showing that TC-nm produced higher liver and kidney function test, higher tissue concentration and somewhat prominent histological changes indicating that formulation of tetracycline increases its pharmacokinetics and bioavailability.

CONCLUSION

From all obtained data in this study, it can be concluded that tetracycline oral administration in rabbit affect liver and kidney function, tissue residues can be reach to the undetected level in all organs at 4 days from the last dose. Nanoemulsion formulation of tetracycline increases its pharmacokinetics and bioavailability but it was less safe than tetracycline hcl.

Ethical approval

The research plan was approved from Cairo University institutional animal care and use committee (CU-IACUC) with approval number CU-II-F-99-18.

Authors' Contributions:

A.M.A,S.A E. and MMA designed and planned this study. MSS and OAF performs experimental work, collects samples and all laboratory tests. All authors shared samples collection, performing the tests, manuscript writing, drafted, revised the manuscript and approved the final manuscript.

ACKNOWLEDGMENTS

The authors thank members whom cooperate in Department of Pharmacology, Faculty of Vet. Med., Cairo University.

Funding statements: The authors declared that this work was self-funded.

Conflict of Interests: The authors declare that there is no conflict of interests regarding the publication of this article.

REFERENCES

- [1] Prescott, J. F., Baggot, J.D., Walker, R.D. (2000): Antimicrobial Therapy in Veterinary Medicine. Iowa State University Press, Ames. pp.277.
- [2] Chopra, I., Roberts, M.(2001).Tetracycline Antibiotics: Mode of Action, Applications, Molecular Biology, and Epidemiology of Bacterial Resistance.Microbiol. Mol. Biol. Rev., 65(2): 232–260. doi: [10.1128/MMBR.65.2.232-260.2001].
- [3] Granados-Chinchilla, F., Rodríguez, C. (2017). Review Article: Tetracyclines in Food and Feeding stuffs: From Regulation to Analytical Methods, Bacterial Resistance, and Environmental and Health Implications. J. of Analytical Methods in Chemistry. Article ID 1315497, 24 ps. <https://doi.org/10.1155/2017/1315497>
- [4] Drulis-Kawa, Z, Jach, A. D. (2009). Liposomes as delivery system for antibiotics.Int J Pharm., 387:187-198.
- [5] Kalhapure, R.S., Suleman, N., Mocktar, C., Seedat, N., Govender, T. (2015).Nanoengineered drug delivery systems for enhancing antibiotic therapy. J Pharm Sci., 104(3):872-905. doi: 10.1002/jps.24298.
- [6] Gurpreet, K. Singh, S. K. (2018). Review of Nanoemulsion Formulation and Characterization Techniques.Indian J. ofPharmaceut. Sci., 80(5):781-789.

- [7] Teixeira, P.C., Leite, G.M., Domingues, R.J., Silva, J., Gibbs, P.A., Ferreira, J.P. (2007). Antimicrobial effects of a microemulsion and a nanoemulsion on enteric and other pathogens and biofilms. *Int. J. Food Microbiol.* 118(1):15-19.
- [8] Mahmoud, H.A., Melake, N.A., El-Semary, M.T. (2012). Bactericidal Activity of Various Antibiotics versus Tetracycline-loaded Chitosan Microspheres against *Pseudomonas aeruginosa* Biofilms. *Pharmaceut. Anal. Acta S15*. doi:10.4172/2153-2435.S15-007.
- [9] Ahmad, A., Græsboell, K., Christiansen, L. E., Toft, N., Matthews, L., Nielsen, S. S. (2015). Pharmacokinetic-Pharmacodynamic Model To Evaluate Intramuscular Tetracycline Treatment Protocols To Prevent Antimicrobial Resistance in Pigs. *Antimicrob. Agents Chemother.* 59(3): 1634–1642. doi: [10.1128/AAC.03919-14].
- [10] Mukherjee, R., Patra, M., Dutta, D., Banik, M., Basu, T. (2016). Tetracycline-loaded calcium phosphate nanoparticle (Tet-CPNP): Rejuvenation of an obsolete antibiotic action. *Biochimica et Biophysica Acta (BBA)*, 1860 (9): 1929-1941.
- [11] Schultz, J.C., Adamson, J.S., Jr., Workman, W.W., Norman, T.D. (1963). Fatal liverdisease after intravenous administration of tetracycline in high dosage. *N. Engl. J. Med.*, 269:999-1004.
- [12] Plaut D. (1978). Biochemical evaluation of liver function. *Am. J. Med. Technol.*, 44 (3):212-216.
- [13] Müller, S., Pfandzelter, C. Spachmüller, B. (1982). Comparative evaluation of the effects of tetracycline, rolitetracycline and doxycycline on some blood parameters related to liver function. *Arzneimittel-Forschung*, 32(3):237-241.
- [14] Pratt, D.S., Kaplan, M.M. (2000). Evaluation of abnormal liver-enzyme results in asymptomatic patients. *N. Engl. J. Med.* 342(17):1266-1271.
- [15] Peterson, M.S., Ajibade, A. J., Olaitan, P. B. (2017). Some effects of simultaneous administration of crude aqueous extracts of *Mangifera indica* leaves and tetracycline on the liver of adults wistar rats. *Anatomy J. of Africa*, 6 (2) 934 – 942.
- [16] Abdel Aziz, E. A., Khairy, M. H., El-Nabtity, S. M., Hamed, E. E., Saffaf, B. A. (2017). Pharmacodynamic and Pharmacokinetic Studies on Tetracycline Hydrochloride in Rabbits. *Zagazig Vet. J.*, 45 (3): 218-227.
- [17] Rosenberg, P. H., Wahlström, T. (1974). Renal and Hepatic Toxicity of Methoxyflurane in Combination with Tetracycline or Oxytetracycline Treatment in Rats. *Basic. clinic. pharmacol. toxicol.*, 34 (1): 46-57. <https://doi.org/10.1111/j.1600-0773.1974.tb02012>
- [18] Asha, K.K., Sankar, T.V., Viswanathan Nair P. G. (2007). Effect of tetracycline on pancreas and liver function of adult male albino rats. *J. Pharm. Pharmacol.* , 59 (9):1241-1248.
- [19] Von Wittenau M. S. and Delahunty C. S. (1966). The distribution of tetracyclines in tissues of dogs after repeated oral administration. *J. of Pharmacol. and Exp. Therap.*, 152 (1): 164-169.
- [20] Fournet, M. P., Zini, R., Deforges, L., Lange, F., Lange, J., Tillement, J. P. (1989). Tetracycline and erythromycin distribution in pathological lungs of humans and rat. *J. Pharm. Sci.*, 78 (12) 1015-1019.
- [21] Hisao, O.K.A., Yoshitomo, I.K.A.I., Hayakawa, J., Ishikawa, N., Shibata, S., Saito, F., Ohmi, S., Ando, K., Kawada, M., Nakanishi, K. (1995). Survey of Residual Tetracycline Antibiotics in Tissues Collected from Diseased Animals in Aichi Prefecture. *Food Hyg. and Safety Sci.*, 36 (6) 759-762. <https://doi.org/10.3358/shokueishi.36.759>
- [22] Roberts, M.C. (1996). Tetracycline resistant determinants: mechanisms of action, regulation of expression, genetic mobility and distribution. *FEMS Microbiol Rev*, 19(1): 1-24.
- [23] Neuschl, J. (1991). Comparison of some pharmacokinetic parameters of tetracyclines which are most frequently used in veterinary medicine. *Arch. Exp. Veterinarmed.* 45, 105-112.
- [24] Morshdy, A.M., Hussein, M.A., El-Gohary, A.E. (2014). Studies on oxytetracycline residues depletion in rabbit meat. *Assiut Vet. Med. J.*, 60 (141): 158- 166.
- [25] Ng, K., Linder, S.W. (2003). HPLC Separation of Tetracycline Analogues: Comparison Study of Laser-Based Polarimetric Detection with UV Detection. *J. of chromatographic sci.*, 419, 460- 466.
- [26] Shalaby, A.R., Salama, N. A., Abou-Raya, S.H., Emam, W. H., Mehaya, F.M. (2011). Validation of HPLC method for determination of tetracycline residues in chicken meat and liver. *Food Chemistry*, 124 (4): 1660-1666.
- [27] Ammar, H.O., Salama, H., Ghorab, M. and Mahmoud, A. (2009). Nanoemulsion as a potential ophthalmic delivery system for dorzolamide hydrochloride. *AAPS PharmSciTech.*, 10, 808. <https://dx.doi.org/10.1208%2Fs12249-009-9268-4>
- [28] Amer M.A., M., El-Badawy, S. A., Saber, M, S., Ahmed-Farid, A.O., Abd-Elsalam, W. H., Amer, M, M. (2018). Comparative pharmacokinetics of tetracycline and tetracycline nanoemulsion formulas in rabbits. in press.

- [29] King, P.R.N., King E.J. (1954). Estimation of plasma phosphatase by determination of hydrolysed phenol with amino-antipyrine. *J. Clin. Pathol.*, 7, 322-326.
- [30] Bergmeyer, H.U., Herder M., Rej R. (1986). Approved Recommendation (1985). On IFCC Method for Measurement of Catalytic Concentration of Enzyme. Part 2. (IFCC Method for Aspartate Aminotransferase). *J. Clin. Chem. Biochem.*; 24:49
- [31] Arret, B., Johnson, D.P., Kirshbaum, A. (1971). Outline of details for microbiological assays of antibiotics: Second revision. *J. Pharm. Sci.*, 60, 1689-1694.
- [32] Bancroft, J.D., Stevens, A., Turner, D.R. (2013). *Theory and practice of histological techniques*. 4th Ed. Churchill Livingstone, Edinburgh, London, Melbourne, New York.
- [33] Plaa, G.L., Charbonneau, M. (1994). Detection and evaluation of chemically induced liver injury: In Hayes, A.W. (ed.) *Principles and methods of toxicology*. 3rd Ed., Raven press, New York
- [34] Zhang, J., Brown, R.P., Shaw, M., Vaidya, V.S., Zhou, Y., Espandari, P., Sadrieh, N., Stratmeyer, M., Keenan, J., Kilty, G. C., Bonventre, V.J., Goering, L. P. (2008). Immunolocalization of Kim-1, RPA-1, and RPA-2 in Kidney of Gentamicin-, Mercury-, or Chromium-Treated Rats: Relationship to Renal Distributions of iNOS and Nitrotyrosine. *Toxicol. Pathol.* 36(3): 397-409.
- [35] Shabana, M.B., Ibrahim, H.M., Khadre, S. E.M., Elemam, M.G. (2012). Influence of rifampicin and tetracycline administration on some biochemical and histological parameters in albino rats. *J. Basic Appl. Zool.*, 65 (5): 299-308.
- [36] Amin, A., Hamza, A. A. (2005). Oxidative stress mediates drug-induced hepatotoxicity in rats: a possible role of DNA fragmentation. *Toxicol.*, 208(3): 367-375.
- [37] Böcker, R., Estler, C.J., Müller, S., Pfandzelter, C., Spachmüller, B. (1982). Comparative evaluation of the effects of tetracycline, rolitetracycline and doxycycline on some blood parameters related to liver function. *Arzneim-Forsch*, 32(3): 237-241.
- [38] Hunt, C.M., Washington, K., (1994). Tetracycline-induced bile duct paucity and prolonged cholestasis. *Gastroenterology* 107 (6), 1844- 1847.
- [39] Yanardag, H., Caner, M., Gunes, Y., Uygun, S. (2005). Acute hemolysis and oligoanuric acute renal failure caused by interrupted. *Internet. J. Nephrol.*, 2 (1). <http://ispub.com/IJNE/2/1/4967>.
- [40] Tasduq, S.A., Kaiser, P., Sharma, S.C., Johri, R.K. (2007). Potentiation of isoniazid-induced liver toxicity by rifampicin in a combinational therapy of ant tubercular drugs (rifampicin, isoniazid and pyrazinamide) in Wistar rats. A toxicity profile study. *Hepatol Res*, 37(10): 845-853.
- [41] Miller, C.S., McGarity, G. J. (2009). Tetracycline-induced renal failure after dental treatment. *J. of the Amer. Dental Asso.*, 140 (1): 56-60.
- [42] Zallen, R.D. (2009). Tetracycline. *J. Am. Dent. Assoc.*, 140 (3): 276 - 282.
- [43] Bihorac, A., Oezener, C., Akoglu, E., Kullu, S. (1999). Tetracycline-induced acute interstitial nephritis as a cause of acute renal failure. *Nephron*, 81(1): 72-75.
- [44] Anonymous (1999). Tetracycline (hydrochloride). In: Dollery C, ed. *Therapeutic Drugs*, 2nd edn. London: Churchill Livingstone, T66-69.
- [45] Welling, P.G., Koch, P.A., Lau, C.C., Craig, W. A. (1977). Bioavailability of tetracycline and doxycycline in fasted and non-fasted subjects. *Antimicrob. Agents Chemother.*, 11: 462- 469.
- [46] Andrews, J. M. (1999). Microbiological assays. In: Reeves DS, Wise R, Andrews JM, White LO, eds. *Clinical Antimicrobial Assays*. Oxford: Oxford University Press, 35-44.
- [47] White, L.O., Lovering, A. M. (1999). Non-microbiological assays. In: Reeves DS, Wise R, Andrews JM, White LO, eds. *Clinical Antimicrobial Assays*. Oxford: Oxford University Press, 45- 64.
- [48] Ferrero, J.L., Bopp, B.A., Marsh, K.C., Quigley, S.C., Johnson, M. J. (1990). Metabolism and disposition of clarithromycin in man. *Drug Metab. Dispos.*, 18: 441-446.
- [49] Abdel-Mohsein, H.S., Mahmoud, M.A.M., Ibrahim, A.A. (2015). Tetracycline Residues in Intensive Broiler Farms in Upper Egypt: Hazards and Risks. *J. World Poult. Res*, 5(3): 48-58.
- [50] Oh, Y.H. and Han, H.K. (2006): Pharmacokinetic interaction of tetracycline with non-steroidal anti-inflammatory drugs via organic anion transporters in rats. *Pharmacol. Res.*, 53(1): 75-79.
- [51] Lin, J.H., Lu, A.Y. (1997). Role of Pharmacokinetics and Metabolism in Drug Discovery and Development. *J. Pharmacol. Rev.*, 49(4): 403 -449.
- [52] Schentag, J.J. (1989). Clinical significance of antibiotic tissue penetration. *Clin Pharmacokinet*, 16(Suppl 1): 25-31. <https://www.ncbi.nlm.nih.gov/pubmed/2653692>.
- [53] Bergogne-Berezin E. (1981). Penetration of antibiotics into the respiratory tree. *J Antimicrob Chemother.*, 8(3): 171-174.

- [54] Villa, R., Cagnardi, P., Bacchetta, S., Sonzogni, O., Faustino, M., Carli, S. (2001). Meat distribution and residue depletion of oxytetracycline in the rabbit. *J. World rabbit Sci.*, 9(4): 159-164.
- [55] Martin-jimenez, T.; Craigmill, L. A. and Riviere, J.E. (1997): Farad digest extralabel use of oxytetracycline. *JAVMA*, 211(1):42-45.
- [56] Rutvij, J.P., Gunjan, J.P., Bharadia, P.D., Pandya, V.M., Modi, D.A. (2011). Nanoemulsion: An advanced concept of dosage form. *Int. J. Pharm. Cosmetol.* 1(5): 122-133.
- [57] Yashpal, S., Tanuj, H., Harsh, K. (2013). Nanoemulsions: A pharmaceutical review. *Int. J. Pharma. Prof. Res.* 4(2): 928-935.
- [58] Charles, L., Attama, A. A. (2011). Current state of nanoemulsions in drug delivery. *J. Bio-mat. Nanobiotech.*, 2: 626-639.
- [59] Subhashis, D., Satayanarayana, J., Gampa, V.K. (2011). Nanoemulsion-a method to improve the solubility of lipophilic drugs. *Pharmanest- Int. J. Adv. Pharm. Sci.*, 2(2-3): 72-83.
- [60] Machado, A.L.D., Branda~o, A.A.H., da Silva, C.M.O.M., da Rocha, R.F. (2003). Influence of tetracycline in the hepatic and renal development of rat's offspring. *Braz. Arch. Biol. Technol. Int. J.* 46 (1): 47-51.
- [61] Bevelander, G., Rolle, G. K., Cohan, S. Q. (1961). The effect of the administration of tetracycline on the development of teeth. *J. Dent. Res.*, 40, 1020-1024
- [62] Cohan, S. Q., Bevelander, G., Tiamsic, T. (1963). Growth inhibition of prematures receiving tetracycline. *Am. J. Dis. Child.*, 105, 65-73.
- [63] Shauer, B. A., Lukacs, L., Zimmerman, H. J. (1974), Biochemical indices of tetracycline hepatic injury in rats. *Proc. Soc. Exp. Biol. Med.*, 147, 868-872.
- [64] Hagel-Lewicka, E., Lewicki, Z., Wutzen, J., Figurski, R. (1980). Ultrastructural investigations of the liver in young (suckling) rats receiving tetracycline hydrochloride. *Mat. Med. Pol.*, 4, 259-262.
- [65] Silva, J. R. O., Rocha, R. F. (1995). Efeitos do cloridrato de tetraciclina em fetos de ratastratadas com o antibiótico. *Rev. Odontol. UNESP*, 24, 109-115.
- [66] Steiner, G., Bradford, W., Craig, J.M. (1965). Tetracycline-induced abortion in the rat. *Labor. Invest.*, 14, 1456-1463.
- [67] Romert, P., Matthiessen, M. E. (1986). Tetracycline-induced changes in hepatocytes of mini-pigs and mini-pigs fetuses as revealed by electron microscopy. *Acta Pathol. Microbiol. Immunol. Scand. Sect. A*, 94, 125-131
- [68] Öbek, A., Petorak I, Eroğlu L, Gürkan A. (1974). Effects of tetracycline on the dog kidney: a functional and ultrastructural study. *Isr. J. Med. Sci.*, 10, 765-771.
- [69] Amacher, D. E., Martin, B. A. (1997), Tetracycline - induced steatosis in Primary canine hepatocyte cultures. *Fundam. Toxicol.*, 40, 256-263.
- [70] Lairmore MD, Alexander AF, Powers BE, Milisen WB, McChesney AE, Spraker TS. (1984). Oxytetracycline-associated nephrotoxicosis in feedlot calves. *J Am Vet Med Assoc.*, 185(7):793-795.
- [71] Hayashi, K. (1961). Experimental studies on histopathological changes in the liver and kidney of rats following antibiotics administration. *J. Exp. Med.*, 8, 156-162.
- [72] Lindquist, R. R., Fellers, F. X. (1966). Degraded tetracycline nephropathy: functional, morphologic and histochemical observations. *Lab. Invest.*, 15, 864-876.
- [73] Hines, L.R. (1956). An appraisal of the effects of long-term chlortetracycline administration. *Antibiotics. Chemother.* 6 (11): 623-641.
- [74] NTP (1989) NTP technical report on the toxicology and carcinogenesis studies of tetracycline hydrochloride (Cas no. 64-75-5) in F344/N rats and B6C3F1 mice (feed studies) NTP toxicology program P.O. Box 12233. NTP TR 344 NIH Publication No. 89-2600. U.S. Department of health and human services.
- [75] Nelson, A.A., Radomski, J.L. (1954). Comparative pathological study in dogs of feeding of six broad-spectrum antibiotics. *Antibiotics and Chemotherapy IV*, (11): 1174-1180.
- [76] Gyrd-Hansen, N. (1980). The effect of tetracyclines on the rabbit heart. *Zentralbl. Veterinärmed. A*, 27(3):228-237.
- [77] Jaiswal, M., Dudhe, R., Sharma, P. K. (2015). Nanoemulsion: an advanced mode of drug delivery system. *Biotech.*, 5 (2): 123-127.
- [78] Hou, L., Liu, Q., Shen, L., Liu, Y., Zhang, X., Chen, F., Huang, L. (2018). Nano-delivery of fraxinellone remodels tumor microenvironment and facilitates therapeutic vaccination in desmoplastic melanoma. *Theranostics*. 8(14): 3781-3796.
- [79] Assali, M., Shakaa, A., Abu-Hejleh, S., Abu-Omar, R., Karajeh, N., Ajory, N., Zyoud, S., Sweileh, W. (2018). A cross-sectional study of the availability and pharmacist's knowledge of nano-pharmaceutical drugs in Palestinian hospitals. *BMC Health Serv Res.*, 18: 250. doi: 10.1186/s12913-018-3060-7.