

Research Journal of Pharmaceutical, Biological and Chemical Sciences

Accidental Cannulation Of Aberrant Radial Artery: Importance Of Labelling The Limb.

Madhu Rao, Sushma Thimmaiah Kanakalakshmi*, and Shweta Sinha.

Department of Anaesthesiology, Kasturba Medical College, Manipal, Udupi, Karnataka, India.

ABSTRACT

Arterial anomalies are very common in the upper limb. It is of utmost clinical significance as accidental cannulation of the artery mistaking it for a vein is a common occurrence. Inadvertent intra-arterial injection of certain drugs can cause thrombosis and lead to ischemia of the limb. Here we report the case of a forty two year old patient with aberrant radial artery which was cannulated mistaking it for cephalic vein despite the anomaly being detected during preanaesthetic evaluation. We discuss the detection and further management of the same highlighting the importance of palpating the radial artery before venous cannulation, labelling the limb and education of the patient and the medical personnel regarding the mishaps that can happen in the presence of an aberrant radial artery.

Keywords: Intra-arterial injection, Arterial anomaly, Aberrant radial artery, Labelling, Education.

**Corresponding author*

INTRODUCTION

Arterial anomalies are common in the upper limb; whether brachial, ulnar or radial. Radial artery anomalies are the commonest with the incidence being as much as 0.8-1%. [1, 2] Normally radial artery runs deep to brachioradialis tendon and runs in the anatomical snuff box. Sometimes it runs superficial to the tendons defining the anatomical snuff box and is called superficial radial artery. Researchers have reported the incidence of superficial radial artery to be ranging from 0.5-1%. [1] We report one such case where an aberrant superficial radial artery was cannulated despite being detected during preanaesthetic evaluation.

Case report

A forty two year old male with no known comorbidities sustained fracture left radial shaft, left clavicle and bilateral metatarsals and was posted for open reduction and internal fixation of the fractures. During preanesthetic evaluation, done one day prior to surgery the radial artery pulsation was found to be absent in the normal position instead, patient was found to have aberrant radial artery running superficially on the dorsum of the right forearm and hand with obvious visible pulsations. Left radial artery could not be visualized or palpated in view of the slab. These findings were recorded in the preanaesthetic chart.

Next day when the patient was shifted to the operating room, the patient had a 20 gauge intravenous cannula in the right hand (Fig 1). Since we were aware of the anomalous radial artery, we had a high suspicion for intra-arterial cannulation. First we confirmed that no drug was injected through it. It had been secured by the ward nurse to draw sample for routine blood investigations and for further use in the operation theatre. Only heparinised saline was injected through it to maintain the patency. As the cephalic vein was running just parallel to the artery (Fig 2), we went ahead to confirm intra-arterial cannulation. There was a gush of bright red blood on aspiration as seen in Figure 1 and 2. On connecting the pressure transducer, an arterial waveform was obtained (Fig 3) and blood gas analysis confirmed that it was an arterial sample (Fig 4). To reinforce our findings, an ultrasound examination was done, which affirmed the anatomy that had been previously suspected. The cannula was removed and pressure dressing was applied at the site. An intravenous cannula was secured in the right external jugular vein (EJV). Right upper limb was labeled and the intravenous fluids and the drugs were administered through the cannula in the EJV. Once the slab was removed from the left upper limb, we confirmed that the radial artery was present in normal position. Surgery proceeded uneventfully under general anaesthesia. Once the surgery was over the patient, his relatives and the attending medical personnel were informed regarding the anomaly. The patient was advised to be careful as the aberrant artery was superficial and was prone for injury and to inform medical personnel during any treatment in the future.

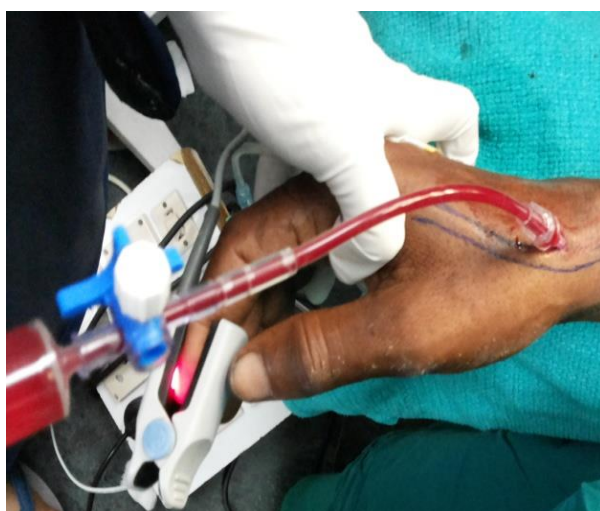

Figure 1: showing a 20G iv cannula in the superficial radial artery and backflow of bright red blood from it

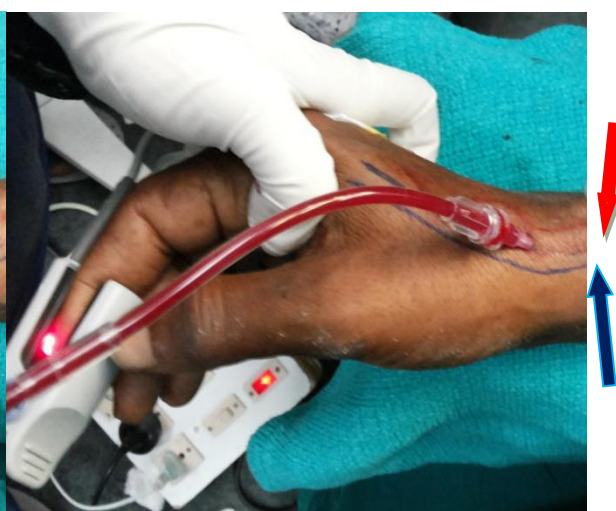

Figure 2: cephalic vein (blue arrow) and superficial radial artery (red arrow) running parallelly

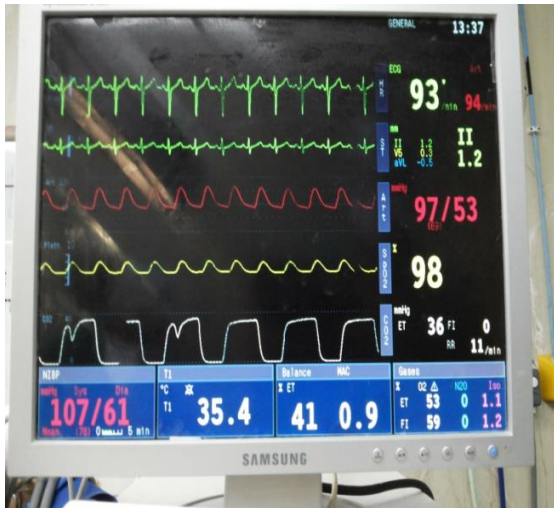

Figure 3: Monitor displaying the arterial waveform after connecting the pressure transducer to the cannula

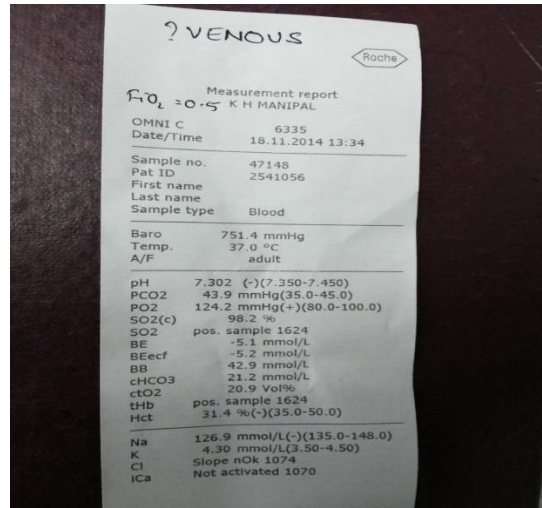


Figure 4: Blood gas analysis report of the sample drawn from the cannula

DISCUSSION

It is of immense clinical importance to recognize this anomaly as inadvertent arterial cannulation is a common occurrence as the superficial radial artery runs very close to cephalic vein and it is prone for injury. Intra-arterial injection of certain drugs can cause vasospasm and thrombosis leading to ischemia and loss of the limb.

Our patient was found to have this anomaly during preanesthetic evaluation. Despite documenting this in the anesthesia chart the ward nurse cannulated it mistaking it for cephalic vein which was running very close to the artery. Fortunately nothing was injected through it and was identified by us as soon as the patient was shifted inside the operating room. We sent a sample for blood gas analysis and connected it to the pressure transducer to confirm the intra-arterial placement of the cannula out of academic interest. There are various case reports on accidental cannulation of aberrant radial artery. [3-5] In all of them, the anomaly was detected after cannulation of the artery in the operating room. This makes our case unique in the fact that though the anomaly was detected and documented the previous day, absence of communication and not labelling the limb led to the mishap. Thus we would like to conclude by highlighting the following learning points;

- Always palpate the radial artery before venous cannulation of the upper limb.
- Label the limb when such an anomaly is identified.
- Educate the patient, relatives and the attending medical personnel regarding the untoward events that can happen.
- Have a thorough knowledge about the management of inadvertent intra-arterial injection of drugs which can salvage the limb.

REFERENCES

- [1] Rodríguez-Niedenführ M, Vázquez T, Nearn L, Ferreira B, Parkin I, Sañudo JR. Variations of the arterial pattern in the upper limb revisited: A morphological and statistical study, with a review of the literature. *J Anat* 2001;199:547-66.
- [2] Wood SJ, Abrahams PH, Sañudo JR, Ferreira BJ. Bilateral superficial radial artery at the wrist associated with a radial origin of a unilateral median artery. *J Anat.* 1996 Dec;189(Pt 3):691-3.
- [3] Sathish N, Prasad S R, Nagesh K S, Jagadeesh A M. Accidental cannulation of aberrant radial artery. *Ann Card Anaesth* 2014;17:76-7.
- [4] Kapoor I, Mahajan C, Prabhakar H. An unintended cannulation of aberrant radial artery!. *Karnataka Anaesth J* 2015;1:220-1.
- [5] Whalen FX, Martin DP. Unintentional cannulation of aberrant radial artery: Review and treatment recommendations. *Signa Vitae* 2011;6:89-90.