

Research Journal of Pharmaceutical, Biological and Chemical Sciences

Organ-Specific Features Of The Terminal Bloodstream Of The Grid Of The Stomach Of Cattle.

Valentina Mikhaylovna Shpygova*, Olga Vladimirovna Dilekova,
Viktor Vasilyevich Mikhaylenko, Vladimir Anatolyevich Meshcheryakov,
and Natal'ya Aleksandrovna Pisarenko

Stavropol State Agrarian University, Zootekhnicheskiiy lane 12, Stavropol, 355017, Russia.

ABSTRACT

In view of the lack of information on the organ-specific and morphometric features of the hemo-microcirculatory bed of the grid, we conducted studies using histological and infusion methods, followed by morphometry. It was established that arterioles move away from first-order arteries into the serous membrane, forming microvascular units - modules in the form of polygonal cells, oriented mainly along the organ, with a diameter of 20 microns in newborns to 40 microns in adult animals. The main elements that form the hemo-microcirculatory bed of the serous membrane are the anastomosing arterioles, which give the precapillaries inside and outside of the specified zone, forming vascular modules. Within the hemo microcirculatory bed of the modules of the serous membrane, all five links stand out clearly. The absolute majority of the modular vessels in adult animals are capillaries. From vessels 2-7 orders of the submucosal plexus, recurrent arteriolar branches are sent to the muscular layer, which anastomose with arterioles extending from the first-order muscular arteries on a subserosal basis. Passing through the muscle sheath, the organ arteries give off many second-order vessels branching mainly along the trunk type. In the hemo microcirculatory bed of the modules of the muscular layer of the mesh in the resistive and depositing units, there are two levels of arterioles and venules, in which the greatest age-related changes in morphometric parameters are noted. The blood supply to the mucous membrane of the mesh occurs through the submucosal plexus. The hemo microcirculatory bed of the mucous membrane is formed in the folds of cells of different levels, conical and spherical papillae of the bottom of the cells and interparticular spaces of the grid. In the cone-shaped papillae, from 1 to 7 papillary arterioles depart, which are divided into them mainly according to the loose type with the formation of the smallest capillary network with a diameter of 6.56 ± 2.78 in young animals to 7.70 ± 1.29 microns in adult animals. Sub-epithelial in the mucous membrane at the confluence of several capillaries are formed post-capillaries, collective venules from 2 to 4 in young and from 4 to 10 or more in adult animals. Changes in the morphometric parameters of the hemo-microcirculatory bed of the mesh in each layer occur most significantly during the period of intensive growth of the epithelio-connective tissue formations of the mucous membrane.

Keywords: vessels, ruminant animals, cattle, stomach, microcirculatory bed, mucosa, membrane; capillaries.

**Corresponding author*

INTRODUCTION

The digestive apparatus of ruminants is unique and economical due to its ability to extract nutrients from roughage rich in fiber (Wang, 2014; Jerbi, 2013; Machado, 2015). In the process of chewing gum, the eaten feed is re-crushed, which increases the efficiency of digestion of coarse vegetable feed (Meshcheryakov, 2008; Beloborodenko, 2014). An important role in the process of chewing gum belongs to the grid, its muscles and muscle plate of the mucous membrane of the folds (crista). The contraction of the smooth muscle cells of the folds and the walls of the mesh are synchronous. Synchronicity in the reduction of reticular cristae is due to the location of the crista muscles (Pelagalli, 2007) and contributes to the normal flow of the chewing gum. The level of chewing activity in cows depends on both milk production and the general state of animal health - the economic efficiency of milk production depends on all of this (Buryakov, 2016). The scar and net make up to 70% of a multi-chamber stomach of ruminants, in which the feed mass can linger from 10 to 20 h (Shevelev, 2003). Numerous intercellular spaces of the basal and spinous layers are involved in the mechanisms of absorption of volatile fatty acids (VFA) and liquids (Pelagalli, 2007). In this regard, it is necessary to study the structural and functional organization of the grid and its age-related adaptive rearrangements, especially those related to the bloodstream.

Objective: to study the organ-specific features of the distribution and morphometric parameters of the hemo-microcirculatory links of the gastric grid of cattle.

Objectives of the study: to determine the morphometric parameters of the arterial and venous level of the terminal bloodstream of the grid in certain periods of postnatal ontogenesis and to describe the types of branching of vessels in its folds of various orders.

MATERIALS AND METHODS

The work was carried out on 90 stomachs of cattle taken from animals of seven age groups: newborns, 1 month, 3 months, 6 months, 18 months, 3 years, 8-10 years of clinically healthy. Material from animals older than three months was taken at the slaughterhouse, and from newborns and menstruations in accordance with Directive 2010/63 / EU of the European Parliament and the Council of the European Union of September 22, 2010 on the protection of animals used for scientific purposes. The choice of age groups for the study was carried out in accordance with the postnatal periodization of cattle (Taurus, 2001). The age morphology of the bloodstream of the mesh was studied by injection, histological and morphometric methods. The vessels were injected through the celiac artery and the gastro-splenic vein with a contrast agent — barium sulphate with glycerin, and a solution of 5% frost-resistant carcass with gelatin, followed by separation of the stomach wall into four shells and enlightenment of the preparations. To obtain histosections, the mesh wall fragments were fixed in a 10% solution of neutral buffered formalin, dehydrated in alcohols of increasing concentration, clarified, condensed in paraffin, 5 µm thick sections were prepared, stained with hematoxylin and eosin for review studies and van Gieson picrofuxin for identify connective tissue. The obtained morphometric parameters were processed by the method of variation statistics.

RESULTS AND DISCUSSION

From the sources of blood supply to the mesh, which are reticular – a. ruminoreticularis, left ventricular - a. gastroepiploica sinistra, left cicatricial - a. ruminalis sinistra and left gastric artery –a. gastrica sinistra, the first-order organ arteries enter the wall of the mesh. Arterioles depart from the first-order arteries into the serous membrane, forming microvascular units - modules in the form of polygonal cells, oriented mainly along the organ (Figure 1).

The main elements that form the hemo-microcirculatory bed of the serous membrane are the anastomosing arterioles with a diameter of 20 to 40 µm, which give the precapillaries inside and outside the module. Within the hemo microcirculatory bed of the modules of the serous membrane, all five links stand out clearly. The absolute majority of the modular vessels in adult animals are capillaries.

First-order muscle arteries in the submucosal plexus branch up to the third order in newborn animals and to the seventh order in adults. From the vessels of the first to seventh orders of the submucosal plexus, recurrent arteriolar branches are sent to the muscle membrane.

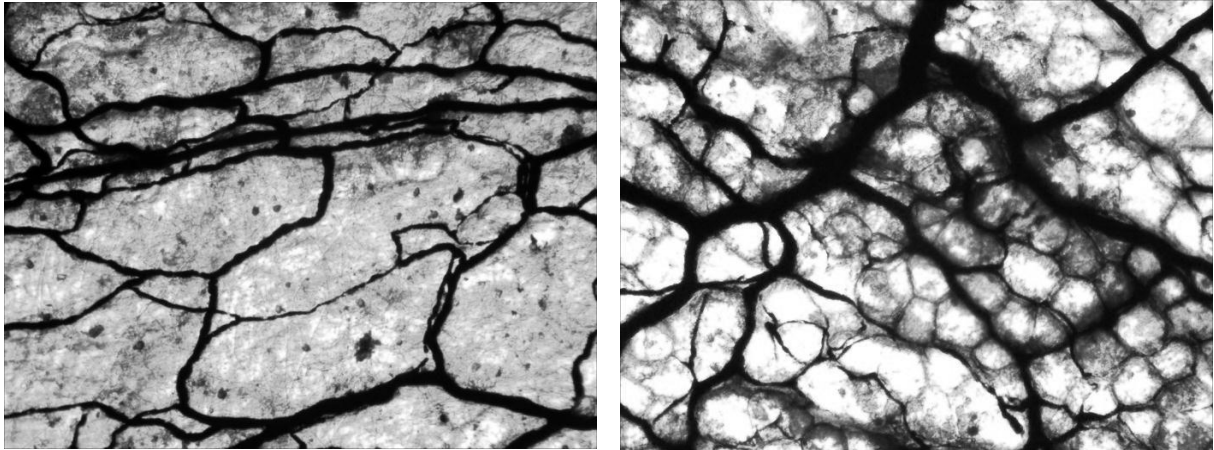


Figure 1: Modules of the hemo microcirculatory bed in the form of polygonal cells of the subserous vascular plexus grid. Age 1 month, injection of arteries with 5% gelatin ink, increase $\times 80$

The vessels in the muscle membrane are distributed along the muscle bundles, forming a plexus in the form of rectangular cells. In the hemo microcirculatory bed of the modules of the muscular membrane of the mesh, seven links are clearly distinguished. The vessels of the first resistive link are divided according to the diameter and structure of the middle shell into large and terminal arterioles, the last depositing link is divided into collective and muscular venules.

The diameter of the first link of the microcirculatory bed of the muscular layer - large arterioles significantly increases in the period from one to six months of animal life by 1.5 times. The diameter of the terminal arterioles significantly changes in the period from three to six months, only by 14% (Figure 2).

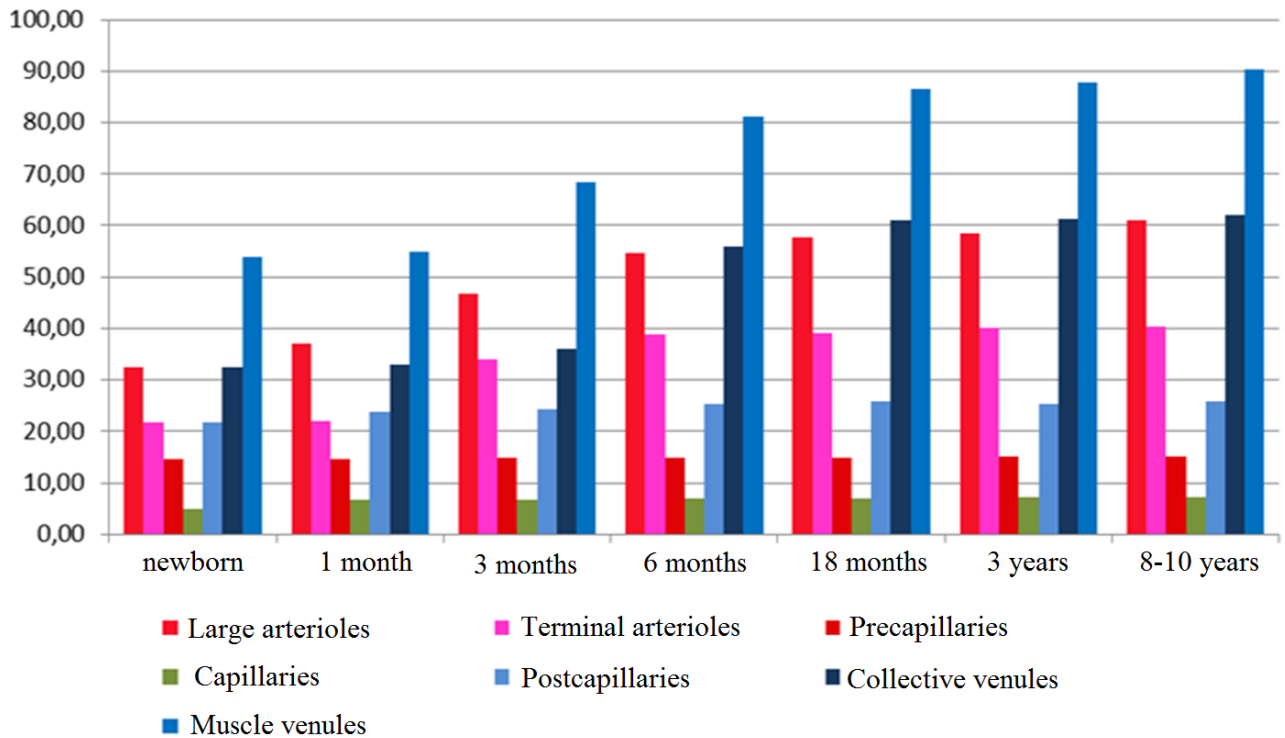


Figure 2: Dynamics of morphometric parameters of the hemomicrocirculatory bed of the muscular layer of the mesh

In the capillary link, a significant difference is observed only between newborns and month-old animals and is 36.3%. In the links of the collective and muscular venules, an intensive change in the diameter of the vessels occurs between three and eighteen months and is 1.7 and 1.3 times, respectively.

In the submucosa, the organ arteries are divided (depending on age) into branches of the second to seventh orders, forming intravascular, intervascular and opposite anastomoses. The source of blood supply to the mucous membrane of the mesh is the submucosal plexus. The arteries of the submucosal plexus form polygonal networks, focused mainly on the base of the cells.

The hemo microcirculatory bed of the mucous membrane is formed in the folds of various levels, conical and spherical papillae of the bottom and interaparticular spaces of the cells of the grid. The blood supply to the papillae of the mesh floor comes from the vessels of the submucosal plexus, which runs along the bases of the papillae. The papillae includes 5-7 papillary arterioles, which are divided into capillaries with a vessel diameter of $6.56 \pm 2.78 \mu\text{m}$ in newborns and $7.70 \pm 1.29 \mu\text{m}$ in adult animals.

At the base of the folds of the cells of the first order in newborn and monthly animals are arteries of the muscular type with a diameter of 100 to 150 microns (Figure 3). In animals aged six to eighteen months and older at the base of the folds of cells of the first order are muscular arteries with a diameter of 300 to 600 microns. In newborns, second-order cells feed from arterioles with a diameter of 48 to 100 microns, running parallel to each other across the sweet cells at their base.

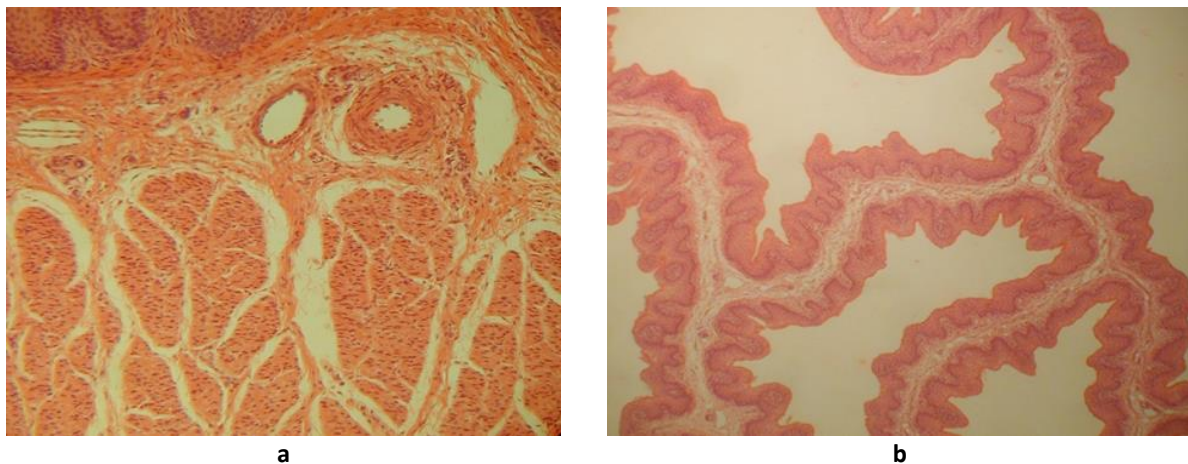


Figure 3: Blood vessels a) submucosal increase x 100; b) the folds of the cells of the mucous membrane of the mesh increase x 40. Age 7 days, hematoxylin and eosin

The arteries of the folds of the cells are divided into long, medium and short arteries with low, medium and high level of branching, running parallel to each other and anastomosing among themselves. Arteries reaching the free edge of the folds — long arteries with the juxtaapical type of branching, form marginal arcs along the free edge of the folds. The middle arteries reach the middle of the folds, and the short branches branch at their base, forming numerous intra-channel and inter-channel anastomoses and subepithelial reticular capillary plexus.

Sub-epithelial in the mucous membrane at the confluence of several capillaries are formed post-capillaries, collective venules from 2 to 4 in young and from 4 to 10 or more in adult animals.

CONCLUSION

Thus, during the period of intensive growth of the epithelium of connective tissue formations of the mucous membrane of the mesh, there is a significant change in the morphometric parameters of its hemo-microcirculatory bed and its morphofunctional specification in each layer.

REFERENCES

- [1] Histomorphometric characterization of forestomach of yak (*Bos grunniens*) in the qinghai-tibetan plateau / J. Wang, H. Li, L. Zhang et al. // *International Journal of Morphology*. 2014. N 32(3) P. 871–881.
- [2] Meshcheryakov, F.A., Trukhachev, V.I. Morphology and sorting-evacuation function of the grid of a multi-chamber stomach of sheep // *Sheep, goats, wool business*. 2008. № 3. p.64–66.
- [3] Beloborodenko A.M., Beloborodenko T.A., Beloborodenko M.A. Age and comparative physiology of digestion in a multi-chamber stomach in sheep and cattle: monograph. - Tyumen: Pechatnik, 2014. 140 p.
- [4] Buryakov N. P., Buryakova M.A. The impact of some indicators on the level of chewing activity in cows // *Current status, prospects for the development of dairy farming and processing of agricultural products*. Omsk, 2016. P. 61–63.
- [5] Jerbi, H., Pérez, W. Gross anatomy of the stomach of the cervus elaphus barbarous // *International Journal of Morphology*. 2013. N 31(2). P. 388–391.
- [6] Morfologia do estômago do cervo-do-pantanal (*Blastocerus dichotomus*, Illiger 1815) / M.R.F. Machado, L.M. Lea, T.H.C. Sasahara et al. // *Arq. Bras. Med. Vet. Zootec*. 2015. V.67, N. 2. P. 424–432.
- [7] Directive 2010/63 / EU of the European Parliament and of the Council of the European Union of September 22, 2010 on the protection of animals used for scientific purposes [Electronic resource]. The access mode is <http://vetrf.ru/fsvps-docs/ru/laws/eu/142-2011.pdf> (the date of circulation is 10.12.2010).
- [8] Teltsov L.P., Solov'eva L.P. Heredity and staged development of human and animal organs in ontogenesis // *Russian morphological statements*. 2001. No. 1–2. P. 153.
- [9] Shevelev N.S., Grushkin A.G. Features of metabolism and morphofunctional structure of the mucous membrane of the rumen of ruminants / N.S. Shevelev, A.G. Grushkin // *Agricultural Biology*. 2003. № 6. P. 15-21.
- [10] Pelagalli, G.V. Morphological studies in the buffalo as a contribution to biotechnological methodologies in the animal production // *Journal of Animal Science*. – 2007. – V. 6, № 2. – P. 184–193.