

# Research Journal of Pharmaceutical, Biological and Chemical Sciences

## Evaluation Of Hepatoprotective And Hepatotherapeutic Activity Of Alhagimaaurorum (Camel Thorn) Alcoholic Extract.

Aziza M Amer<sup>1\*</sup>, Gehad Tarek<sup>2</sup>, Wafaa M Amer<sup>3</sup>, Hana A Mabrok<sup>4</sup>, and Abdrabou MI<sup>5</sup>.

<sup>1</sup>Pharma. Dept., Faculty of Veterinary Medicine, Cairo University, Egypt.

<sup>2</sup>College of Biotechnology, Misr University for Science and Technology (MUST), Egypt.

<sup>3</sup>Plant taxonomy- Faculty of Science, Cairo University.

<sup>4</sup>Animal Health Research Institute, Dokki, Giza, Egypt.

<sup>5</sup>Cytology & Histology dept., Faculty of Veterinary Medicine, Cairo University, Egypt.

### ABSTRACT

The study was designed to investigate the hepatoprotective and hepatotherapeutic (treatment) activity of 70 % alcohol whole plant extract of Alhagimaaurorum (A.maurorum) against injured liver induced by paracetamol in experimental mice. Phytochemical screening of the extract was also carried out and indicated the presence of flavonoids and tannins. Alcohol extract of A.maurorum at dose of 1g /kg body was administered and compared with 100 mg/kg silymarin as hepatoprotective for 7 days and 7 days treatment in paracetamol (2 gm/ kg) intoxicated mice. Biochemical parameters including Aspartate aminotransferase (AST), alkaline phosphates (ALP), alanine aminotransferase (ALT), Total protein (T.P) and total Bilirubin (TB) levels were measured to determine the degree of improvement in conditions of damaged mice liver. The liver was taken and preserved in 10 % formal saline for histological studies. The extract pretreatment with the extract as hepatoprotective at doses of 1g/kg has exhibited reduction in biochemical parameters (ALP, T.P, ALT, AST, and T.B). The extract administration as pre-treatment (7 days) and treatment (7 days) in hepatic intoxicated mice showed histological improvement of the damaged liver tissues. Hepatic cellular changes were recorded in paracetamol treated animals and these cellular changes were improved and/or prevented by administration of A. maurorum alcoholic extract. Our results clarified that A.maurorum alcoholic extract has a hepatoprotective and hepatic therapeutic (treatment) effect against paracetamol hepatotoxicity in mice.

**Keywords:** Alhagimaaurorum, Alcohol extract, liver function, hepatoprotective, hepatotherapeutic

*\*Corresponding author*

## INTRODUCTION

Medicinal values of plant species is an important part of documentation of indigenous knowledge, that provided various modern drugs [1]. Also, Medicinal information of plants is helpful to ecologists, taxonomists, pharmacologists, watershed and wild life managers in listing the traditional uses and enhancing the prosperity of an area [2,3].

Alhagi is genus from family Fabaceae. The plant is of wide distributed in many countries including Asia, Australia and Europe. It is commonly known as camel thorn. Alhagi species are famous for feed and folk medicinal uses. Different species of Alhagi have been explored for their antioxidant potential, nutritive value and various medicinal properties. A wide array of pharmacologically active secondary metabolites such as flavonoids, alkaloids (alhadidin and alhacin), steroids, pseudalhagin A, phospholipids and polysaccharides have been reported from different parts of Alhagi species [4]. A broad range of biological activities such as hepatoprotective, antispasmodic, antidiarrheal, antioxidant, cardiovascular, antiulcer, antipyretic, anti-inflammatory, anti-rheumatic, antibacterial and antifungal have been attributed to the usage of different parts of Alhagi. Alhagi plants are a rich source of digestible protein and important minerals [5]. All parts of plants including roots, bark, leaves and flowers are commonly used to treat pain, respiratory disorders, wounds, pyrexia, stomach disorders and sexual diseases [6- 8]. Extracts of flowers, roots, stem, leaves, and oil and seeds of Alhagi plant are biologically active and are used to treat several diseases [9-16].

Functionally, Liver has great capacity to remove toxic substances and synthesize useful principles. Therefore, liver damage by hepatotoxic agents is of grave consequences. In spite of the great develop in medicine and therapeutics industry; there is increasing need of an agent which could protect liver from damage. In view of severe undesirable side effects of synthetic agents, there is growing focus to follow systematic research methodology and to evaluate scientific basis for the traditional herbal medicines which are claimed to possess hepatoprotective activity. Generally could not distinguish and defined an activity related to an antihepatotoxic effect, a wide variety of parameters should be evaluated for the selection of remedies related to the disorders associated with this organ [17].

Liver damage is further characterized into hepatocellular (predominantly initial alanine transferase elevation) and cholestatic type (initial alkaline phosphatase rise). However they are not mutually exclusive and mixed type of injuries are often encountered. Chemicals and drugs such as paracetamol radicals induced lipid peroxidation; damage the membranes of liver cells and organelles, causing the swelling and necrosis of hepatocytes and result to the release of cytosolic enzymes in to the blood [18].

Liver function tests (LFTs) are used to monitor the stat of liver function. These tests for the presence of enzymes in blood that is normally most abundant in liver tissue, metabolites or products as serum proteins, serum albumin, serum globulin, alanine transaminase, aspartate transaminase, prothrombin time, partial thromboplastin time [19].

Silymarin herbal drugs derived from the species *Silybum marianum* has activities due to its antioxidant activity and radical scavenging. Therefore, the protective effects on different organs toxicity have been shown the fields of nephrotoxicity, viral hepatitis, cancer, hepatotoxicity, neurotoxicity, lung diseases and prostate diseases [20].

This study was carried out for evaluation of hepatoprotective and hepatotherapeutic activity of *A. maurorum* (camel thorn) alcoholic extract as compared with Silymarin. Moreover, results of Clinical studies give an overview on the cure potency of this plant to develop improved traditional medicines from local plants.

## MATERIAL AND METHODS

### Plant Collection:

Fresh herb of *A. maurorum* (Camel thorn) was collected from the natural habitat. The collected plant will be scientifically identified by **Prof. Dr. Wafaa Amer** Professor of taxonomy Faculty of Science, Cairo University. The plants was washed with tap water and left for drying in the open air place. The dried plant will be grind to powder.

**Preparation of Extracts:**

Three hundred (300) grams of the dried plant powder was extracted by 500 ml alcohol, using gradual extraction. The extract was filtered and evaporated to dryness using rotavapour and the extractive value was calculated as 7.0 grams in El Nasser company laboratory. The dried extract was reconstituted in tween 80 and saline solvent to prepare the required concentration used in this study [18].

**Experimental Animals:**

Animal used are 65 male mice (30 for toxicity and 35 for hepatoprotective and hepatotherapeutic study) NIH mice age 8-10 week old (20-30 gm.) was maintained in spacious polypropylene cages in the animal house of Department of Pharmacology Faculty veterinary Medicine Cairo University. The animal room was ventilated and maintained under standard experimental conditions (Temperature 25°C) and 12 hours light/dark cycle throughout the experimental.

**Induction of hepatotoxicity using paracetamol:**

Animals in the 1<sup>st</sup> group were kept as control non treated (solvent only). The experimental mice in treated groups were administered paracetamol in a single oral dose (2 gm/kg b.wt. In 1 ml Maze oil). Blood samples will be collected for determination of liver enzyme activity as indicator for liver damage caused by paracetamol.

**Chemicals:**

The chemicals Alcohol 70%, Tween 80 used in this experiment were of highest purity grade available commercially in Egypt taken from El Nasser Company.

**Toxicological study:**

Total 30 mice were used. LD50 of the tested extract was determined as described by Hodge and Sterner [21] and Stevens and Gallo [22]. For this purpose five groups of 5 mice each, weighing 20-25 g b.wt and nearly the same age. Mice were given orally 500- 2500 mg/kg and the control group will give the respective volume of distilled water with tween 80 (as solvent). The toxic symptoms (colic, diarrhea and stretching), mortality rate and post-mortem findings in treated group will record within 24 hours post administration.

**Hepatoprotective and hepatotherapeutic study:**

Thirty five animals were randomly grouped into 7 groups, 5 animals each and treated as shown in table (1).

**Table (1): Animal Grouping and treatments**

|             | Group | Treatment  |
|-------------|-------|--|
| Control -ve | 1     | Control - ve (Tween 80 +Saline)  |
| Control +ve | 2     | Alcohol extract for (1000 mg/kg b wt.) 7 days  |
|             | 3     | Paracetamol (2gm/kg b wt)  |
| Prevention  | 4     | Alcohol extract (1000 mg/kg b wt.) for 7 days + Paracetamol (2gm/kg b wt)                      |
|             | 5     | Silymarin (100 mg/kg b.wt) for 7 days + Paracetamol (2gm/kg b wt) + Alcohol extract for 7 days |
| Treatment   | 6     | Paracetamol (2gm/kg b wt.) +Alcoholic extract of plant (1000 mg/kg b wt) for 7 days            |
|             | 7     | Paracetamol (2gm/kg b wt.) + Silymarin (100 mg/kg b wt) for 7 days                             |

### Samples

**a. Blood Samples:** Blood samples for chemical analysis and enzymes activities was collected and used for the determination of alkaline phosphates (ALP) [23], aspartate aminotransferase (AST), alanine aminotransferase (ALT) [19], Total protein (T.P), and total Bilirubin (TB).

**b. Tissue samples:** liver tissue samples will be taken and kept in 10% formalin for histological examination.

### Drugs:

**a. Silymarin (Mariagon)<sup>®</sup>** as capsules 140 mg. obtained from MEDU Co. Egypt.

**b. Paracetamol:** Pure powder 100%, obtained from El-Nasr for pharmaceuticals and chemicals, Egypt.

### Histological examination of liver tissues:

Liver tissue specimens were fixed in 10% formol saline, then trimmed off, washed and dehydrated in ascending grades of alcohol. The dehydrated specimens were then cleared in xylene, embedded in paraffin blocks and sectioned at 4-6  $\mu\text{m}$  thick. The obtained tissue sections were deparaffinized using xylol and stained using hematoxylin and eosin (H&E) for histological examination through the electric light microscope [24].

The frequency and severity of lesions in the livers were assessed semi-quantitatively as previously reported [25] using a scale where, grade 0: No apparent injury, grade I: Swelling of hepatocytes, grade II: Ballooning of hepatocytes, grade III: Lipid droplets in hepatocytes and grade IV: Necrosis of hepatocytes.

### Statistical analysis:

The samples were analyzed for normality using the Kolmogorov–Smirnov test. The parametric data were compared using Student's t-test for the intergroup means and Student's paired t-test or analysis of variance (ANOVA; two-way ANOVA with the Bonferroni posttest) for the intragroup means, and the nonparametric data were compared using the Mann–Whitney test. All values are expressed as the M + SD. Differences in the mean values were considered statistically significant when the p value was  $<0.05$  and  $0.01$ .

## RESULTS AND DISCUSSION

Liver disease rates are increasing over the years. According to National statistics, liver diseases have been ranked as the 4<sup>th</sup>[26] and 2<sup>nd</sup>[27] cause of mortality amongst all digestive diseases in UK and US; respectively. According to the latest Liver Disease Deaths in Egypt reached 84.51% of total deaths rank 1, United States 10.21% rank 127 while UK is 8.24% rank 141[28].

### Toxicity:

The alcohol extract showed no any toxic symptoms on mice up to 15 g/ k.gBwt. Therefore, the plant extract is a save extract.

### Effect on liver weight/body weight Index

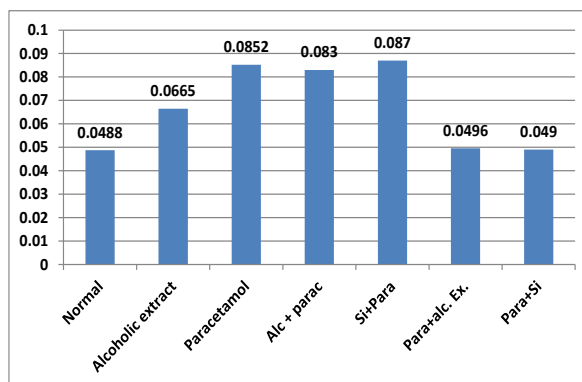
The treatments showed significant increase in liver weight/body weight Index. In groups treated with paracetamol (Gr 3). Mahmood et al.[2] reported significant increase in liver mean relative weights ratio of acute paracetamol treated animals. Significant decrease in index of G4 (alcoholic extract + paracetamol) and G5 (Silymarin and Paracetamol) as compared with index of normal group, while the results showed decrease of liver weight/body weight. Also a significant decreased index in Gr 6 Paracetamol + alcoholic extract and Gr 7 Paracetamol + Silymarin as compared with G3 Paracetamol damaged liver (Table 2 and Fig., 1). In mammals, liver size is 2.5 to 3% related to animal body weight, a ratio mediated by the afflux of hepatotrophic factors [29].

**Table (2): Effect of A maurorum alcoholic extract(1000mg/ kg) on on Body weight, Liver weight and liver/bodyweight index in paracetamol damaged mice liver (N=5, Mean ± SD)**

| Treatment   | Group | Mice B.WT      | Liver weight  | Index           |
|-------------|-------|----------------|---------------|-----------------|
| Control -ve | 1     | 18.64 ± 0.17   | 0.92 ± 0.097  | 0.0488 ± 0.006  |
| Control +ve | 2     | 21.2 ± 0.60    | 1.26 ± 0.050  | 0.0665 ± 0.011  |
|             | 3     | 28.14 ± 1.508  | 2.334 ± 0.333 | 0.0852 ± 0.010a |
| Prevention  | 4     | 25.7 ± 1.46    | 2.152 ± 0.186 | 0.083 ± 0.002a  |
|             | 5     | 25.2 ± 0.748   | 2.2 ± 0.090   | 0.087 ± 0.006a  |
| Treatment   | 6     | 27.402 ± 0.662 | 1.416 ± 0.059 | 0.0496 ± 0.001b |
|             | 7     | 26.332 ± 1.566 | 1.296 ± 0.036 | 0.49 ± 0.002b   |

aSignificant increase from normal P> 0.01.

b.Significant decrease from paracetamol treated P> 0.01.



**Fig (1) : Effect of A maurorum alcoholic extract (1000mg/ kg)on Body weight, Liver weight and liver/bodyweight index in paracetamol damaged mice liver (N=5, Mean ± SD)**

**Effect on biochemical parameters**

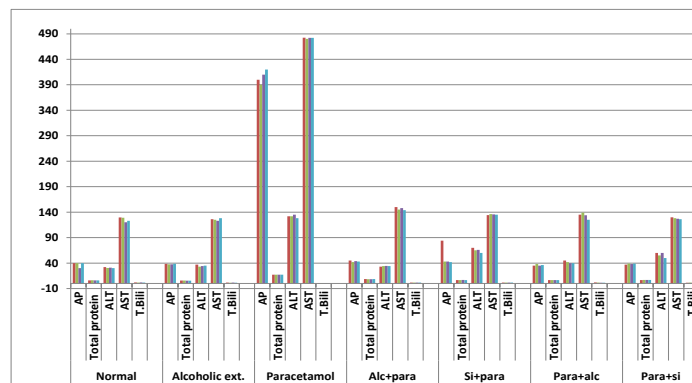
The determined biochemical parameters after oral administration of A maurorum alcoholic extract (1000mg/ kg) as preventive and treatment toparacetamol damaged mice liver for 7 days (Table 3 and Fig., 2) showed significant increase of Alkalinphosphatas (AP), TP protein , ALT and significant decrease in Total B.rubin (T.B.)in paracetamol (2gm/kg bwt.) treated group indicating liver damage. Paracetamol induced hepatic injury in rats [2, 30, 31].Preventive administration of A maurorum alcoholic extract (1000mg/ kg) and Silymarin (100 mg/kg b.wt) for 7 days showed significant increase in Total protein, ALT and ASTand significant increase in T.B., compared with the normal control group. Extract may decrease B.rubin levels by cathartic effect or activation of liver enzymes [32].

Treatment with oral administration of A maurorum alcoholic extract (1000mg/ kg) and Silymarin (100 mg/kg b.wt) for 7 days after liver damage by paracetamol (2mg/kg b wt) resulted in significant decrease in AP,Total proteinand ALT and significant increase in T.B. in treated groups than that of paracetamol treated group (Table 3 and Fig., 2)[33].Results of Donia[8]suggest that C. coronarium has a significant hepatoprotective activity at 400mg/kg.

**Table (3): The determined biochemical parameters after preventive and treatment administration of A maurorum alcoholic extract (1000mg/ kg) paracetamol damaged mice liver, N=5, Mean ± SD.**

| Treatment   | Group | Parameters    |               |              |               |             |
|-------------|-------|---------------|---------------|--------------|---------------|-------------|
|             |       | AP            | Total protein | ALT          | AST           | T.B.        |
| Control-ve  | 1     | 38.00±4.00    | 6.12±0.07     | 30.74±0.69   | 126.22±3.97   | 1.84±0.10   |
| Control +ve | 2     | 37.58±1.10    | 5.66±0.10a    | 34.80±1.33a  | 125.60±1.62   | 1.58±0.12a  |
|             | 3     | 400.00±14.14a | 17.18±0.07a   | 131.40±2.33a | 481.76±0.84a  | 0.73±0.02a  |
| Prevention  | 4     | 43.60±1.02b   | 8.38±0.12ab   | 34.02±0.49ab | 145.40±3.44ab | 1.72±0.05b  |
|             | 5     | 50.80±16.61ab | 6.70±0.06ab   | 64.20±3.82ab | 135.26±0.71ab | 1.72±0.01b  |
| Treatment   | 6     | 36.20±1.17b   | 6.64±0.14ab   | 41.40±1.96ab | 134.60±5.31b  | 1.62±0.15b  |
|             | 7     | 38.20±0.75b   | 6.84±0.08ab   | 55.00±4.47ab | 126.20±3.37b  | 1.50±0.09ab |

a. Significant change from normal at P> 0.01. b. Significant change from paracetamol treated P> 0.01  
 AP: Alkalin phosphatase. ALT: Alanintranaminase  
 AST: Asyetylalanintransaminase T.B.: Total B.rubin



AP= Alkalin phosphatase ALT= Alanintranaminase  
 AST=Asyetylalanintransaminase T.B.= Total B.rubin  
 Alc+para= alcoholic extract + paracetamol. Si+para=Silymarin + Paracetamol  
 Para+alc= Paracetamol +alcoholic extract. Para+Si= paracetamol + Silymarin

**Fig 2: The determined biochemical parameters after preventive and treatment administration of A maurorum alcoholic extract (1000mg/ kg) paracetamol damaged mice liver, N=5, Mean ± SD.**

The hepatoprotective effect of A.maurorumae alcohol extract was studied using Wistar albino mice (1000mg/kg BW orally for 7 days). Liver injury induced in mice by paracetamol (2g/kg BW once orally). The normal appearance of hepatocytes and correction of, alkaline phosphates (AP), Total protein (TP), Aspartate aminotransferase (AST), alanine aminotransferase (ALT) and total B.rubin (T.B.), indicated a good protection of the extract from paracetamol hepatotoxicity. The results were compared with silymarin as reference hepatoprotective drug [33, 34].

Administration of 1000mg/kg of the alcohol A. maurorum extract to mice, showed a significant decrease in the level of transaminases in animals treated with a combination of Alcohol A.maurorum extract plus paracetamol. Histological investigation confirmed that, A.maurorum extract protects liver against induced damage by paracetamol [18, 35]. It was reported that water or ethanolic extract of A. maurorum reduced ALT and AST activities, total B.rubin levels [36, 37]. Otherwise; Investigations on Ethanolic Extract of A. maurorum hepatoprotective effect showed that this plant at the doses of 250 and 500 mg/kg failed to inhibit the raised biomarkers (SGOT, SGPT, ALP and B.rubin levels) [34,38] and this effect of may be due to the presence of flavones [39].

### **The hepatotoxic agents metabolism on liver hepatotoxicity**

It is well established that (paracetamol) is metabolized in the liver to highly reactive trichloromethyl radical and this free radical leads to auto-oxidation of the fatty acids present in the cytoplasmic membrane phospholipids and cause functional and morphological changes in the cell membrane [2,40]. This is evidenced by an elevation of the serum AST, ALT in  $\text{CCl}_4$  treated mice [41, 42]. In the liver,  $\text{CCl}_4$  is metabolized by the cytochrome P450- dependent mono oxygenase systems [43] followed by its conversion to more chemically active radical. This radical initiates the chain reaction of lipid peroxidation, which attacks and destroys polyunsaturated fatty acids [44- 46]. It was reported that the antioxidant activity or inhibition of the generation of free radicals is important in the protection against the ( $\text{CCl}_4$ ) induced liver lesion [47].

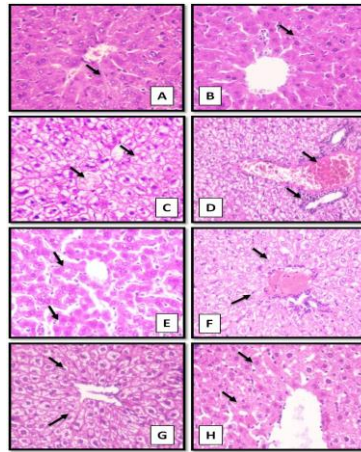
Study on the total phenolic and flavonoids contents of Camel thorn reveals the higher concentration of flavonoids and phenolic especially in the Alcoholic extract. In this study the administration of 1000 mg/kg of the alcohol extract of the *A. maurorum* to mice showed a significant hepatoprotective activity against paracetamol, by a significant decrease in the activity of serum transaminases. Similar results were reported against several liver damaging materials [46, 48- 50].

#### **His to logical findings:**

Liver tissue section of control group I and extract group II showed normal histological structure of hepatic lobules and organization of hepatic cords with prominent central hepatic vein. Polygonal hepatic cells were joined to one another in anastomosing plates, with borders that face either the sinusoids or adjacent hepatocytes grade 0 (Fig.3,A and B). Livers of paracetamol-treated rats group III revealed treatment-related changes associated with hepatotoxicity. Histologically, the changes in the liver were characterized by vacuolation of hepatocytes located near the liver capsule and around the terminal hepatic venule. pyknotic and lytic changes of hepatocytes nuclei were seen (Fig., 3C). Multiple focal necrotic areas scatter all hepatic parenchyma was noticed. Congestion and mononuclear cells aggregation around terminal hepatic venules and portal triad of grade 4 were observed (Fig., 3D). Similar liver cellular changes were reported in rats given paracetamol by Mahmood et al., [2].

Liver tissue from rats pretreated with extract group IV and then challenged with paracetamol showed moderate improvement as compared with paracetamol-treated group; most of the central veins appeared normal and the other one appeared congested but not dilated, the hepatocytes showed low-grade of the cellular swelling, the necrotic areas disappeared. Hyperplasia of Kupffer cells, widening of hepatic sinusoids and few number of mononuclear cells were seen (Fig., 3E) grade I.

Liver section of rats pretreated with silymarin Group V and then challenged with paracetamol showed lower intensity of mononuclear aggregation and massive ballooning degeneration of hepatocytes consequently the sinusoidal space not apparent (Fig., 3F) grade II. Extracts treated Group VI and after treatment with paracetamol then complete treatment for one week the hepatic parenchyma showed normal appearance central veins. The hepatocytes showed low-grade cellular swelling, the necrotic areas and hyperplasia of Kupffer cells disappeared, hepatic sinusoids retain irregularly radiated distribution (Fig. 3G) grade I. Liver tissue from rats treated with Silymarin Group VII showed disappearance of



**Fig (3): Rat liver tissue section stained with H&E (X400) showing**

A : Control gr I: Normal histological structure of hepatic lobule (Arrow). B : Extract treated gr II: showing

normal histological structure of hepatic lobule (Arrow). C :Paracetamol-treated gr III: Vacuolation of hepatocytes and focal necrotic areas (Arrow). D: Paracetamol-treated gr III: congestion and mononuclear cells aggregation around terminal hepatic venules and portal triad (Arrow). E : Liver tissue Pretreated with silimarin IV and challenged with paracetamol showing low-grade of the cellular swelling (Arrow). F: liver tissue pretreated with silimarin Group V and then challenged with paracetamol showing massive ballooning degeneration of hepatocytes (arrow).G : liver tissue treated with extract Group VI after treatment with paracetamol showing low-grade cellular swelling.H: liver tissue treated with silimarin Group VII after treatment with paracetamol showing massive ballooning degeneration of hepatocytes (arrows).

mononuclear cells and persistence of ballooning degeneration of hepatocytes (Fig.,3H) grade II [33].

Histological investigation proved that, *A. maurorum* extract protects liver against damage induced by (ccl4). Our study also suggested that *A. maurorum* extract can protect the liver against the injury produced by (ccl4), with unexpected behavior for enhancing the cardiac toxicity of Adriamycin in mice [35]. Sheweita et al. [37] reported that markedly reduced and attenuated the histological changes from severe to moderate alterations in livers of diabetic rats treated with *A. maurorum* extracts. Rehman et al. [38] found that *A. maurorum* extract showed excellent protection on liver architecture, almost to the level of the silimarin-treated groups, validating its hepatoprotective effects in the experimental rabbits.

### CONCLUSION

From the above results we concluded that the alcohol extract of *A. maurorum* at dose of 1000 mg/kg exhibits significant hepatoprotective and hepato therapeutic activity by reducing levels of biochemical enzymes and improved histopathological liver damage. Further studies are required to explore which active principle responsible for this hepatoprotective activity.

### Ethical approval

This study was approved from Institutional Animal Ethics Committee and in accordance with local laws and regulations.

### Authors' Contributions

AMA and HAM designed and planned this study, drafted and revised the manuscript. GT, HAM and WMA shared in plant collection, identification as well as extract, samples collection, performing the tests, manuscript writing and data analysis. M.I. collects tissue samples and histological study. All authors read and approved the final manuscript.



## ACKNOWLEDGMENTS

The authors thank departments of pharmacology and Cytology & Histology, faculty of Vet. Med., Cairo University. Dept. of botany, Faculty of Science, Cairo University. College of Biotechnology, Misr University for Science and Technology (MUST), Egypt. Animal Health Research Institute, El-Fayom. El Nasser Company. The authors declared that work was self-funded.

## REFERENCES

- [1] Cox PA. (2000). Will tribal knowledge survive the millennium? *Science*; 287: 44-45.
- [2] Mahmood N. D., Mamat S. S., Kamisan F. H., Yahya F., Kamarolzaman M. F. F., Nasir N., Mohtarrudin N., Tohid S. F. Md. and Zakaria Z. A. (2014). Amelioration of Paracetamol-Induced Hepatotoxicity in Rat by the Administration of Methanol Extract of *Muntingiacalabura* L. Leaves. *Bio Med Research International*, Article ID 695678, 10 pages. <http://dx.doi.org/10.1155/2014/695678>
- [3] Ibarra M, Hussain F and Sultan A. (2007). Ethnobotanical studies on plant resources of Ranyal hills, District Shangla, Pakistan. *Pak J Bot.*, 39(2): 329-337.
- [4] Donaldson, S. and D. Rafferty. (2003). Identification and Management of Camelthorn (*Alhagipseudalhari*). University of Nevada Cooperative Extension Fact Sheet O2-41. Available at <http://www.unce.unr.edu/publications/files/nr/2002/FS0241.pdf> (accessed May 2010).
- [5] Muhamad, G., Ajazhussain, M., Anwar, F., Ashraf, M., and Gilani, A.H. (2015). A Plant Genus Rich in Bioactives for Pharmaceuticals, 29: 1-13.
- [6] Rahmatullah, M., Khatun, M.A. and Morshed, N. (2010). A randomized survey of medicinal plants used by folk medicinal healers of Sylhet Division, Bangladesh. *Adv Nat Appl Sci* 4(1): 52-62.
- [7] Rahmatullah, M., Ferdousi, D., Mollik, M.A.H., Jahan, R., Chowdhury, M.H. and Haque, W.M. (2010). A survey of medicinal plants used by Kaverajes of Chalna area, Khulna District, Bangladesh. *Afr J Tradit Complement Altern Med* 7(2): 91-97
- [8] Donia, A. M. (2014). Biological Activity of *Chrysanthemum coronarium* L. Extracts. *Annual Research & Review in Biology* 4(16): 2617-2627.
- [9] Varshney, K. and Singh, A.K. (2008). Inventory of some ethnomedicinal plant species used by rural people of Etah district, UP, India. *Plant Arch* 8(2): 757-759.
- [10] Amani, A.S., Maitland, D.J. and Soliman, G.A. (2006). Antiulcerogenic activity of *Alhagimaurorum*. *Pharm Biol* 44(4): 292-296.
- [11] Al-Douri, N.A. and Al-Essa, L.Y. (2010). A survey of plants used in Iraqi traditional medicine. *Jordan J Pharm Sci.*, 3(2) 100-108.
- [12] Badshah, L. and Hussain, F. (2011). People preferences and use of local medicinal flora in district Tank, Pakistan. *J Med Plants Res* 5(1): 22-29.
- [13] Kouchmeshky, A., Jameie, S.B., Amin, G. and Ziai, S.A. (2012). Investigation of ACE inhibitory effects of medicinal plants used in traditional Persian medicine for treatment of hypertension: screening study. *Thrita Stud J Med Sci* 1(1): 13-23
- [14] Marashdah, M.S. and Farraj, A.I. (2010). Pharmacological activity of 2% aqueous acetic acid extract of *maurorum* roots. *J Saudi Chem Soc* 14: 247-250
- [15] Zain, M.E. Awaad, A.S., Al-Outhman, M.R. and El-Meligy, R.M., (2012). Antimicrobial activities of Saudi Arabian desert plants. *Phytopharmacol.*, 2(1): 106-113.
- [16] Amiri, M.S., Jabbarzadeh, P. and Akhondi, M. (2010). An ethnobotanical survey of medicinal plants used by indigenous people in Zangelanlo district, Northeast Iran. *J Med Plants Res* 6 (5): 749-753.
- [17] Dhalwal, K., Shinde, V., Mahadik, K.R. and Kadam, S.S. (2006). Hepatoprotective Activity of *Sidarhombifolia* ssp. *retusa* Against Thioacetamide and Allyl Alcohol Intoxication in Rats. *Pharmacology online*, 3 : P 259\_266.
- [18] Abdellatif, A.G., Gargoum, H., M., Debani, A., A., Bengleil, M., Alshalmani, S., El Zuki, N. and El Fitouri, O., (2014). Camel thorn has hepatoprotective activity against or acetaminophen induced hepatotoxicity, but enhances the cardiac toxicity of adriamycin in rodents. *Internat J. of Medical Health Pharmaceutical and Biomedical Engineering*. 8 (2), 118-122.
- [19] Bergmeyer H.U., Herder M., and Rej R. (1986). Approved Recommendation (1985). On IFCC Method for Measurement of Catalytic Concentration of Enzyme. Part 2. (IFCC Method for Aspartate Aminotransferase). *J Clin Chem Biochem*; 24: 49
- [20] Karimi G., Vahabzadeh M., Lari P., Rashedinia M., and Moshiri M., (2011). "Silymarin", a Promising Pharmacological Agent for Treatment of Diseases. *Iran J Basic Med Sci.*, 14(4): 308-317.

- [21] Hodge, H. C. and Sterner, J. H. (1943). Determination of substances acute toxicity by LD50. *Am IndHygAssoc*, 10, 93.
- [22] Stevens, K. R. and Gallo, M.A. (1982). Principles and methods of toxicology, Edited by Hayes, A.W., Student edition, Raven Press, New York, 53-77.
- [23] King P.R.N. and King E.J. (1954): Estaimation of plasma phosphatase by determination of hydrolysed phenol with amino-antipyrine. *J. Clin. Patho.* 7:322-326.
- [24] Bancroft, J.D., Stevens,A. and Turner, D.R. (1996). *Theory and Practice of Histological Techniques*.4<sup>th</sup> Ed., Churchill, Livingston, New York, London, San Francisco, Tokyo.
- [25] Plaa, G. and M. Charbonneau, (1994). Detection and Evaluation of Chemically Induced Liver Injury. In: *Principles and Methods of Toxicology*, Hayes, A.W. (Ed.). Raven Press, New York, pp: 841-846.
- [26] UK (2013). national statistics, <http://www.statistics.gov.uk/>.
- [27] Everhart, J.E. andRuhl, C.E. (2009). Burden of digestive diseases in the United States Part III: Liver, B.ary tract, and pancreas. *Gastroenterology*; 136: 1134 –1144.
- [28] WHO (2017). Data published in World health rankings. <http://www.worldlifeexpectancy.com/cause-of-death/liver-disease/by-country/>
- [29] Parra, O. M., Silva, R. A. P., Sousa e Silva, J. R. M., Hernandez-Blazquez, F. J., Peduto, L., Saad, W. A., and Saad, W. A. Jr. (1995). Enhancement of liver size by stimulation of intact rat liver with exogenous hepatotrophic factors. *Sao Paulo Med J* 113 (4) 941–947.
- [30] Yahya F., Mamat S. S., Kamarolzaman M. F. F., A. A. Seyedan, Jakius K. F., Mahmood N. D., Shahril M. S., Suhaili Z., Mohtarrudin N., Susanti D., Somchit M. N., Teh L. K., Salleh M. Z. and Zakaria Z. A. (2013).Hepatoprotective activity of methanolic extract of Bauhinia purpurea leaves against paracetamol-induced hepatic damage in rats. *Evidence-Based and Complimentary Alternative Medicine*, vol. 2013, Article ID 636580, 10 pages.
- [31] Zakaria Z. A., Rofiee M. S., Somchit M. N., Zuraini A., Sulaiman M. R., Teh L. K., Salleh M. Z. and Long K. (2011). Hepatoprotective activity of dried- and fermented-processed virgin coconut oil.Evidence-Based Complementary and Alternative Medicine, vol. 2011, Article ID 142739, 8 pages.<http://dx.doi.org/10.1155/2011/142739>
- [32] Nabavizadeh, S.and, Nabavi, M. (2010). The effect of herbal drugs on neonatal jaundice. *Iran J Pharm Res.*, 3:39–40.
- [33] Papackova Z., Heczkova M. , Dankova H., Sticova E., Lodererova A., Bartonova L., Poruba M.andCahova M, (2018). Silymarin prevents acetaminophen-induced hepatotoxicity in mice. *PLOS ONE*. <https://doi.org/10.1371/journal.pone.0191353>, 20 Pages.
- [34] Alqasoumi, S.I., Al-Rehaily, A.J., AlSheikh, A.M, and Abdel-Kader M.S. (2008). Evaluation of the hepatoprotective effect of Ephedra foliate, Alhagimaurorum, Capsella bursa-pastoris and Hibiscus sabdariffa against experimentally induced liver injury in rats. *Natural Product Sciences*,14(2): 95-99.
- [35] Gargoum H.M., Muftah S.S., Al Shalmani S., Mohammed H.A., Alzoki,A., Debani, A.I. Fituri A.H.O, El Shari F., El Barassi I., Meghil S.E. and Abdellatif A.G. (2013). Phytochemical screening and investigation of the effectof Alhagimaurorum (Camel thorn) on carbonetrachloride, acetaminophen and adriamycin inducedtoxicity in experimental animals. *Journal of Scientific and Innovative Research*, 2 (6): 1023-1033
- [36] Shaker. E., Mahmoud, H. and Mnaa, S.(2010). Anti-inflammatory and anti-ulcer activity of the extract from Alhagimaurorum (camel thorn). *Food and Chemical Toxicology*, 48 (10) 2785– 2790.
- [37] Sheweita, S.A., Mashaly, S., Newairy, A.A., Abdou, H.M. and Eweda, S.M. (2016). Changes in Oxidative Stress and Antioxidant Enzyme Activities in Streptozotocin-Induced Diabetes Mellitus in Rats: Role of Alhagimaurorum Extracts. *Oxidative Medicine and Cellular Longevity* Volume 2016, Article ID 5264064, 8 pages <http://dx.doi.org/10.1155/2016/5264064>
- [38] Rehman J. U., Akhtar N., Khan M. Y., Ahmad K., Ahmad M., Sultana S., and Asif H.M. (2015). Phytochemical Screening and Hepatoprotective Effect of AlhagimaurorumBoiss(Leguminosae) Against Paracetamol-Induced Hepatotoxicity in Rabbits.*Tropical J. of Pharmaceutical Res.*, 14 (6): 1029-1034
- [39] Ahmad, S., Riaz, N., Saleem, M., Jabbar A., Nisar-Ur-Rehman, and Ashraf H.M. (2010). Antioxidant flavonoids from Alhagimaurorum. *J. of Asian Natural Products Res*, 12 (2) 138–143.
- [40] Zidek, N., Hellmann, J., Kramer, P.J., and Hewitt P.G. (2007). Acute Hepatotoxicity: A Predictive Model Based On Focused Illumina Microarrays. *Toxicol Sci.* , 99(1):289-330.
- [41] Bhattacharyya, D., Mukherjee, R., Pandit, S., Das, N. and Sur, T.K. (2003). Hepatoprotective Effect of Himoliv, a Polyherbal Formulation. *Indian J Pharmacol.*, 47:435-40.
- [42] Bhattacharyya, D., Mukherjee, R., Pandit, S., Das, N., and Sur, T.K. (2003). Prevention of Carbon Tetrachloride Induced Hepatotoxicity in Rat by Himoliv, a Polyherbal Formulation. *Indian J,Pharmacol.*, 35:183-185

- [43] Noguchi, T., Fong, K.L., Lai, E.K., Alexander, S.S., King, M.M., Olson, L., Poyer, J.L., and Mccay, P.B. (1982). Specificity of Aphenobarbital-Induced Cytochrome P450 for Metabolism of Carbontetrachlorideto the Trichloromethyl Radical. *BiochemPharmacol.*, 31: (82) 440-443.
- [44] Slater, T.F., K.H. Cheeseman and Ingold K.U. (1985). Toxicity as a Model for Studying Free-Radical Mediated Liver Injury. *Philosophical Transactions of the Royal Society of London-Series B: Biol. Sci.*, 311(1152): 633-645
- [45] Clawson, G.A. (1989). Mechanisms of Hepatotoxicity. *Pathol.Immunopath. Res.* 8(2): 104-112.
- [46] Daly, F.F., Fountain, J.S., Murray, L., Graudins, A. and Buckley, N.A. (2008). Guidelines for the management of paracetamol poisoning in Australia and New Zealand explanation and elaboration. A consensus statement from clinical toxicologists consulting to the Australasian poisons information centres. *Med. J.Aus*, 188 (5): 296– 301.
- [47] Weber, L. W., Boll, M., and Stampfl, A. (2003). Hepatotoxicity and Mechanism of Action of Haloalkanes: as a Toxicological Model. *Crit. Rev. Toxicol.* 33, 105–136.
- [48] Faure, M., Lissi, E., Torres, R. and Vidella, L.A. (1990). Antioxidant activity of liginin and flavonoids. *Phytochem.*; 29: 3773-3775.
- [49] Jin X, Qian J and Lu Y., (2011). The role of hepatoprotective effect of a flavonoid-rich extract of *Salvia plebeia* R.Br. on carbon tetrachloride induced acute hepatic injury in mice. *J. Med.Plant Res.*, 5(9): 1558-1563.
- [50] Bagban, I.M., Roy, S.P., Chaudhary, A., Das, S.K., Gohil, K.J. and Bhandari, K.K. (2012). Hepatoprotective activity of the methanolic extract of *Fagonia indica* Burm in carbon tetrachloride-induced hepatotoxicity in albino rats. *Asian Pacif.J. Trop. Biomed.*, 1457-1460.