

Research Journal of Pharmaceutical, Biological and Chemical Sciences

Secondary Corrections Of Residual Deformities Of Mandible: A Retrospective Clinical Study.

Abhinandan Patel KN¹, Ramya Rajanna², Ravi Kumar², Vidhya N³, and AhamedIrfan Khazilane^{3*}.

¹Department of Facio-Maxillary, Sanjay Gandhi Institute of Trauma and Orthopaedics, Jayanagar East, Bangalore, India

²Department of OMFS, Siddhratha Dental College and Hospital, Tumkur, India

³Dept of OMFS, The Oxford Dental College & Research Centre, Bangalore, India

ABSTRACT

Among the facial bone fractures the second most frequently injured facial bone is mandible. In spite of many advances in diagnostic aids and treatment modalities in facial fractures, returning patients functional and esthetic components to their pre-traumatic state remains a difficult task. The most common post-traumatic complications of jaw fractures include malunion, nonunion, TMJ dysfunction and facial asymmetry. The most frequent clinical features of all the above complications is malocclusion. These complications most of the times requires secondary surgery for its correction. The purpose of our study was to evaluate the functional and aesthetic outcome of secondary corrective surgery.

Keywords: Malocclusion, Mandibular fracture, Refracture, Residual deformity.

**Corresponding author*

INTRODUCTION

Mandibular fractures are one of the most common maxillofacial injuries. Their management has been traditionally regarded as one of the corner-stones of oral and maxillofacial surgery. Despite many technological and technical advances, to consistently return patients to their pre-injury state remains one of the main challenges in the management of these injuries.[1] The most common complications are infections, malocclusion, malunion, nonunion, facial deformity etc.[2,3] Multiple and comminuted fractures of the mandible can induce stability deficits, which can lead to complications that requires re-operation.[4]

The incidence of post traumatic malocclusion is reported between [5]-20%.² Complications like malocclusion can occur due to no treatment conducted or even in treated cases. Malocclusion is a result of inadequate establishment of occlusion, lack of accurate anatomic reduction, poor adaptation and fixation of plates. Malocclusion is the main indication for secondary operative intervention after maxillofacial trauma.³ Additional surgery causes the patient increased pain, recovery time and costs for hospitalization, as well as interruption of daily life. In treating mandibular fractures, it is necessary to make the utmost effort to minimize complications.[6]

MATERIALS AND METHODS

A total of 14 subjects were operated irrespective of age, gender, primary surgery for trauma. Medically compromised patients were excluded from our study. Out of all 14 subjects participated in the study, the subjects were divided into 3 groups depending on primary site of fracture.

Group I included 5 patients with bilateral condylar fracture

Group II included 5 patients with para-symphysis fracture

Group III included 2 patients with mandibular angle fracture.

It was decided to correct the existing post-operative residual deformity by secondary corrective surgery to reposition fragments to the pre-traumatic anatomical position and achieve proper occlusion, there by establishing harmony between masticatory muscles and jaws.

Case 1:

Included all the patients from Group I who were treated for bilateral condylar fracture. Surgical procedure was planned and executed under general anesthesia following standard principles through extra oral approach. A standard bilateral pre-auricular incision and posterior ramus approach was carried out and careful dissection was done to reach malunion sites on either side. Care was taken to avoid injury to facial nerve and its branches. The miniplates used in previous surgery were removed. Segments were mobilized by re-fracturing the primary fracture site which were malunited using chisel and mallet. Inter-maxillary fixation was done to achieve desired occlusion.

A 2mm L-shaped miniplates with 6mm/8mm screws were used to secure the fractured site on either side. Wound closure was done in layers using 3-0 absorbable and non-absorbable sutures. Post-operatively healing was uneventful and desired occlusion maintained.

Case II:

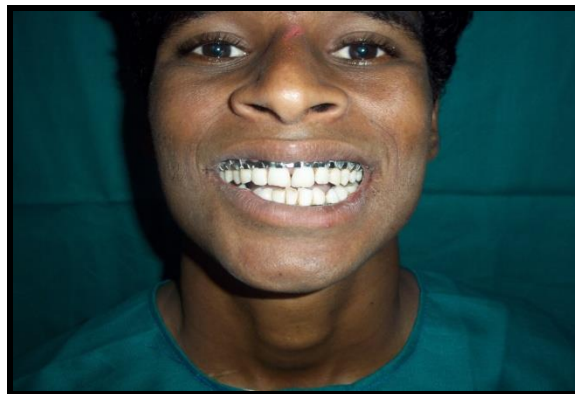Included all the patients from Group II who were treated for parasymphysis fracture. Surgical procedure was planned and executed under general anesthesia following standard principles through intra oral approach. A standard vestibular incision and intra oral approach was carried out and careful dissection was done to reach malunion sites on either side. Care was taken to avoid injury to mental nerve and its branches. The miniplates used in previous surgery were removed. Segments were mobilized by re-fracturing the primary fracture site which were malunited using chisel and mallet. Inter-maxillary fixation was done to achieve desired occlusion.

A 2.5mm miniplates with 6mm/8mm screws were used to secure the fractured site on either side. Wound closure was done in layers using 3-0 absorbable and non-absorbable sutures. Post-operatively healing was uneventful and desired occlusion maintained.

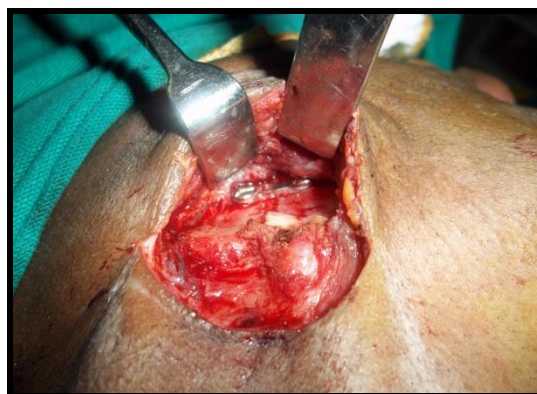Case III:

Included all the patients from Group III who were treated for bilateral mandibular angle fracture. Surgical procedure was planned and executed under general anesthesia following standard principles through extra oral approach. A standard bilateral submandibular incision was made and careful dissection was done to reach malunion sites on either side. Care was taken to avoid injury to marginal mandibular nerve and its branches. The miniplates used in previous surgery were removed. Both right and left impacted third molar were also removed if present. Segments were mobilized by re-fracturing the primary fracture site which were malunited using chisel and mallet. Inter-maxillary fixation was done to achieve desired occlusion.

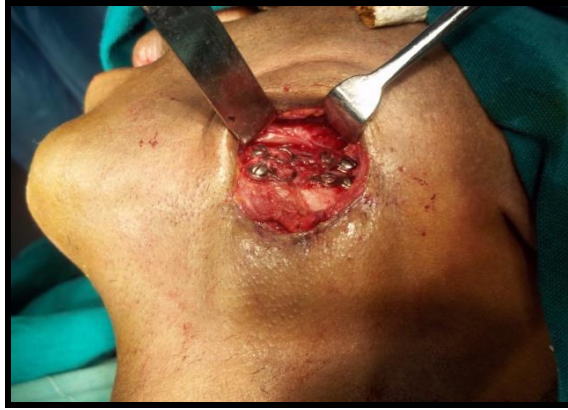A 2.5mm miniplates with 6mm/8mm screws were used to secure the fractured site on either side. Wound closure was done in layers using 3-0 absorbable and non-absorbable sutures. Post-operatively healing was uneventful and desired occlusion maintained



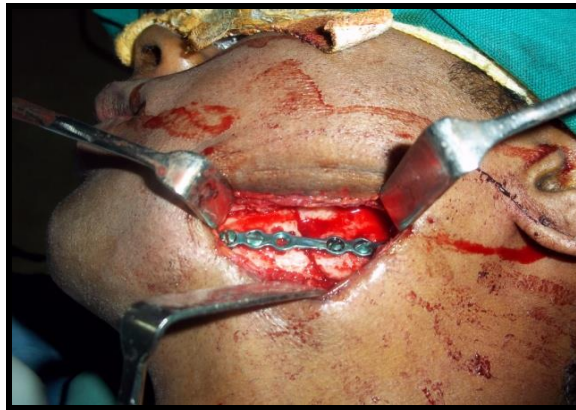
Pre – operative photograph with open bite



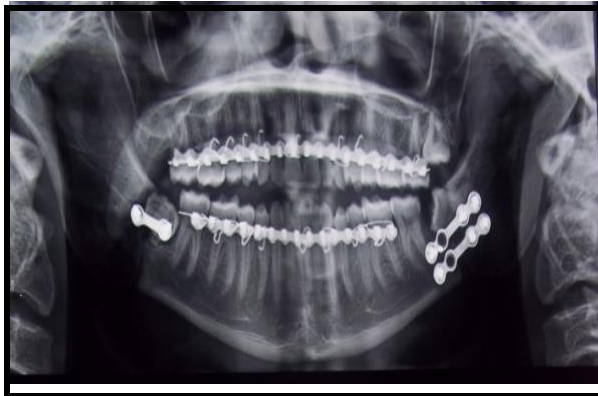Mucoperiosteal flap reflection with Risdons Submandibular incision



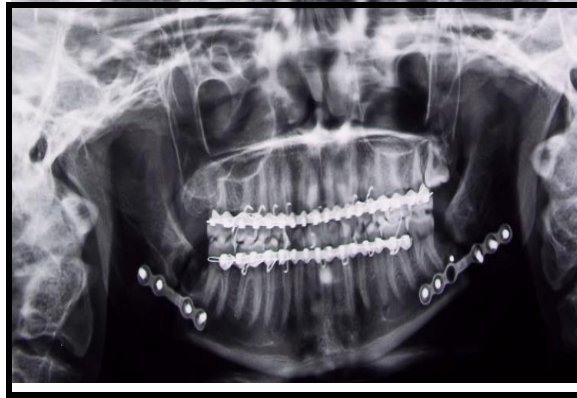Exposure of previous placed miniplates at The primary fracture site



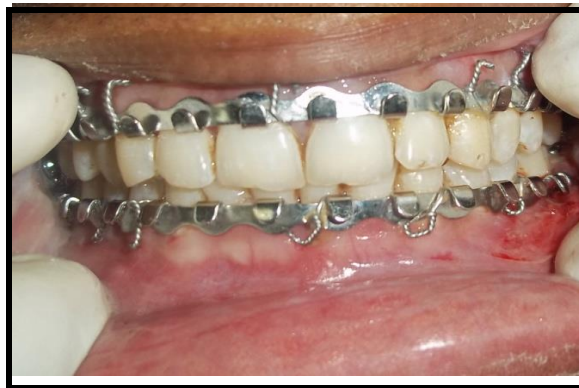Replating of intentionally re-fractured fracture segments At the primary fracture site



Pre-operative radiograph



Post-operative radiograph



Corrected malocclusion post-operatively



6 months post-operatively

DISCUSSION

The mandible is prone to complications that occur after jaw fracture reduction due to the following reasons. The mandible is the only bone in the facial region that moves and it has less bone support than the facial bones; therefore, a fracture of the mandible generally results in greater degrees of instability. Because of the muscle attached to the mandible, mandible displacement may occur even after reduction and fixation. The mandible is located in the lower part of the oral cavity, which increases the possibility of infection. The mandible has lower blood circulation than the maxilla, which contributes to the occurrence of inappropriate integration.[1, 2]

The goal of the treatment of mandibular fracture is accurate reduction of the bone segment to recover the pre-traumatic occlusion and to restore normal masticatory function, pronunciation, shape and sensation. Rigid

fixation is required to form primary callus thus there are many different techniques came into existence for fracture treatment. Even after proper planning and execution of treatment there are many complications which may appear during the post-operative period, which include

- Infection
- Non-union
- Malunion
- Malocclusion
- Non-vital teeth
- Exposure of hardware

The reasons for these complications are classified by Alpert et al as⁸

- Complications that appears after proper treatment is conducted
- Complications that are attributed to inappropriate treatment
- Complications that are due to failure of surgical treatment
- Complications that occur because no treatment is conducted

Most of the times mandibular fractures are accompanied by edema and haemorrhage, which increases difficulty in precise diagnosis. The occurrence of multiple fracture of mandible could be erroneously overlooked. Further, complications after mandible surgery can be attributed to inexperience, inadequate radiological examination or availability of proper diagnostic aids.^[11]

Mathog and boies reported that mandibular fractures are the most common fracture in the facial bone to cause malunion. malocclusion is the most common sign and symptom of malunion. Malocclusions like anterior open bite, posterior open bite, mandibular retrognathia, maxillary retrognathia etc. are the common clinical features which are seen in a malunion patient.^[6]

The treatment options available for treating mandibular fracture vary from closed reduction to more advanced options like internal rigid fixation. In cases of rigid fixation, the rigidity obtained prevents correction of technical errors without re-operation. Malunion when detected early manifests as malocclusion and should be immediately rectified by removing the hardware, achieve correct occlusion, perform good reduction and rigid fixation. Malocclusion when detected after fracture healing involves osteotomies of the bone, establishing the occlusion using a surgical splint and application of rigid fixation. Minor occlusal disparities are corrected using orthodontic therapy, crown and bridge or occlusal adjustments.^[7, 8]

Ellis et al stated that malocclusion present less than 3 months after the injury can be treated as a fresh fracture but if it is more than 3 months after trauma in a patient with full range of mandibular motion, can be approached as a standard orthognathic patient. The different types of orthognathic surgical techniques used are sagittal split, bilateral sagittal split, vertical ramus and segmental osteotomies or combination is planned based on the type of malocclusion and fracture site.

CONCLUSION

Post-operative complications like malunion, nonunion, facial asymmetry etc. which are the main causes of malocclusion, are the unsatisfactory results that may occur in the treatment of mandibular fractures. A clear understanding about the surgical anatomy, various treatment options and utilizations of diagnostic aids will help in proper planning and execution of treating mandibular fracture which in turn reduces the complications.¹⁻⁴

REFERENCE

- [1] Vega LG, Re-operative Mandibular Trauma: Management of Posttraumatic Mandibular Deformities. Oral Maxillofacial Surg Clin N Am. 2011; 23: 47–61.
- [2] Imola MJ, Ducic Y, Alderson R. The Secondary correction of post traumatic craniofacial deformities. J of head & neck surg.2008; 139:654-600.

- [3] Spitzer WJ, Vanderborght G, Dumbach J. Surgical management of mandibular malposition after malunited condylar fractures in adults' J of Cranio-Maxillofacial Surgery.1997; 25: 91-99.
- [4] Becking AG, Zijderveld SA, Tuinzing B. Management of Posttraumatic Malocclusion Caused by Condylar Process Fractures. J oral Maxillofac Surg. 1998; 56: 1370-1 374.
- [5] Kommers SC, Bergh BVD, Boffano P, Verweij KP, Dysocclusion after maxillofacial trauma: A 42-year analysis. J of craniomaxillo facial surgery. 2013:1-4.
- [6] Lindorf H, Steinhauser EW. Correction of Jaw Deformities Involving Simultaneous Osteotomy of the Mandible and Maxilla. J. max.-fac. Surg.1978;6: 239-244.
- [7] Mendonca D, Kemkere D. Avoiding occlusal dearrangement in facial fractures: an evidence based approach. Indian J Plastic Surg.2013;46(2):215.
- [8] Nakamura S, Takenoshita Y, Oka M. Complications of miniplates osteosynthesis for mandibular fractures. J of Max Surg.1994;52(3):233-38.
- [9] Kommers S, Van den bergh B, Boffano P, Verweji K, Forouzanfar T. Dysocclusion after maxillofacial trauma: A 42-year analysis. J of Cranio-Maxillofacial Surgery.2014;42(7):1083-86.
- [10] Lee S, Kim S, Moon S, Oh J, You J.Treatment of malocclusion after open reduction of maxillofacial fracture: a report of three cases. J of the Korean Association of Oral and Maxillofacial Surgeons.2014;40(2):91.
- [11] Assel L, Evaluation of rigid internal fixation of mandible fractures performed in the teaching laboratory. Journal of Oral and Maxillofacial Surgery.1993;51(12):1315-1319.