

Research Journal of Pharmaceutical, Biological and Chemical Sciences

The evolution of surgical treatment of acute destructive pancreatitis.

Azat M. Zainutdinov^{1*}, Igor S. Malkov², and Almir R. Abashev³.

¹Assistant professor of the Department of fundamentals of clinical medicine of Kazan Federal University, assistant professor of Department of surgery SBEI CPE KSMA 420141, Kazan, Fuchika Str.

²Professor, Head of Department of surgery SBEI CPE KSMA, 420139, Kazan, Zorge Str.

³Assistant professor of the Department of fundamentals of clinical medicine of Kazan Federal University 420043, Kazan, Chekhova Str. 1a,

ABSTRACT

This paper gives a brief overview of the problem of choosing the optimal treatment of acute destructive pancreatitis. At the Department of Surgery SBEI CPE KSMA, a comparative analysis of different surgical treatment of acute pancreatitis was carried out at different times. During the first period (1987-1993), 102 patients were operated, with adherence to the active surgical tactics. Operations were carried out mainly in the first week of the onset of the disease, i.e. in an aseptic stage, including 27 patients (26.5%) undergoing corpora-caudal pancreatectomy and splenectomy. Postoperative mortality in this case was 37.2%. During the second stage (1994-2000), 256 patients were operated. All operations included drainage and were carried out on different dates after the onset. Postoperative mortality was 17.3%. Since 2002, the clinic has been adhered to noninvasive therapeutic approach, when the alternative to the "early" surgical interventions is therapeutic manipulations under ultrasound or laparoscopic guidance, which reduced the overall postoperative mortality rate up to 13.4%. The mortality rate in moderate pancreatic necrosis has been reduced up to 5%, and in its severe forms - up to 26%.

Keywords: Acute pancreatitis - Laparotomy - Laparoscopy - ultrasound-guided manipulations (ultrasound investigation).

**Corresponding author*

INTRODUCTION

As the current publication show, the problem of surgical treatment of patients with pancreatic necrosis has not found its optimal solution yet. Mortality after the traditional methods of treatment of infected pancreatic necrosis remains high, ranging from 20% to 62% and higher [1-7]. The consequence of the progressive sterile and infected pancreatic necrosis is the formation of multiorgan failure [4].

Using the methods of puncture drainage of abdominal and retroperitoneal structures, performed under the ultrasound and computed tomographic guidance, have allowed revising the views on the treatment of many diseases and surgical complications, including the treatment of necrotizing pancreatitis. Some foreign authors [8-12] have published information on the effective use of minimally invasive methods of treatment in patients with infected pancreatic necrosis. The most rational method is considered to be a combination of videolaparoscopic and ultrasound techniques [12, 13, 14, 11, 15]. C.R. Carter et al. in 2000 [11] developed an original method of necrosequesrectomy performed under CT guidance with the expansion of puncture channel with a special urological bougie with an optical cannula and a balloon dilator.

MATERIALS AND RESEARCH METHODS

We have conducted the analysis of the results of surgical treatment of 499 patients with destructive forms of acute pancreatitis over the past 20 years. Depending on the way the surgical treatment of pancreatic necrosis had been changing, we have distinguished 3 time periods.

During the first period (1987-1993), 102 patients were operated. The clinic adhered at that time to the active surgical tactics in treatment of pancreatic necrosis. The operations were mainly carried out in the first week of the onset of the disease. Such operations we called "early", since they were performed in aseptic stage of the pathological process in the pancreatic parenchyma. Twenty-seven patients (26.5%) underwent corpora-caudal pancreatectomy with splenectomy. The other patients underwent various variants of omental and abdominal cavity drainage. Postoperative mortality in this case was 37.2%.

During the second stage (1994-1999), 256 patients were operated. Here, noninvasive therapeutic approach replaced the active surgical tactics. Open surgical procedures were carried out at various dates from the onset of the disease due to the absence of a positive effect of the ongoing conservative therapy subject to growing endogenous intoxication, pancreatogenic peritonitis and developing septic complications. Such operations we called "forced". All of them include drainage (laparotomy with marsupialization, drainage of omental and abdominal cavity). During this period, no resection of the pancreas was carried out in patients with pancreatic necrosis. Moreover, the rate of laparotomy decreased by three times in the first 5 days of the onset of the disease. They were replaced by diagnostic and therapeutic laparoscopy. Postoperative mortality was reduced by 2 times and amounted to 17.3% in this period. However, the lack of objective criteria for determining the indications for surgical intervention, resulted in their often performance in reactive phase (7-10 days from the onset of the disease) either during the peripancreatic infiltration stage - the operations were quite traumatic, and seldom reached the goal, or during the generalization of purulent process - the operations were retarded, which served as the basis for the revision of treatment.

Since 2000, the clinic has been adhered to noninvasive therapeutic approach, when the alternative to the "early" surgical interventions is therapeutic manipulations under ultrasound or laparoscopic guidance, conducted on the abdominal cavity (debridement and drainage, decompression cholecystostomy), the omental sac (debridement and drainage) and the retroperitoneal space. Laparotomy in this group was performed in most cases in the absence of effect of the treatment, starting from the 3rd week of the onset of the disease. The objective of the surgery is to conduct sequesterectomy and the extended drainage of omental and retroperitoneal fat. These "deferred" interventions were carried out in 186 patients.

Fiberoptic gastroduodenoscopy was performed in case of persistent pain syndrome, lasting for 12 hours, and in obstructive jaundice.

The objective of the study was to eliminate the intraductal hypertension by cannulation of the pancreatic duct, or by papillotomy in case of calculus entrapment.

Indications for laparoscopy were pancreatogenic progression of peritonitis, its combination with a destructive cholecystitis, and obstructive jaundice.

Diagnostic and therapeutic laparoscopy was performed in 256 (88%) men, and 35 (12%) women aged 17 to 84 years, undergoing treatment in the clinics of the Department of Surgery SBEI CPE KSMA. The average age was 42.4 years.

Indications for laparoscopy were a progressing pancreatogenic peritonitis, a combination of acute pancreatitis with destructive cholecystitis, a combination of acute pancreatitis with obstructive jaundice, and the need for differential diagnosis with other acute surgical diseases.

An absolute contraindication is a terminal condition.

The relative contraindications may be considered the unstable hemodynamics, previous surgeries on the stomach and pancreas, and large postoperative ventral hernias.

The tasks of laparoscopy at the diagnostic stage were the confirmation of the diagnosis and the morphological form of the disease (the presence of edema, exudate with high amylase activity, foci of steatonecrosis), revealing of signs of severe pancreatitis (hemorrhagic effusion, extensive steatonecrosis, extensive hemorrhagic impregnation), and at the stage of treatment - removal of peritoneal exudate, decompression of the retroperitoneal tissue and bile ducts.

The criteria of the severity of pancreatic necrosis according to laparoscopy are the nature of the exudate, retroperitoneal fat lesion, and the area of lesion.

Endosurgical interventions were performed under general anesthesia during pneumoperitoneum corresponding to 9-11 mm Hg. A schematic arrangement of the operating staff is shown in Figure 1.

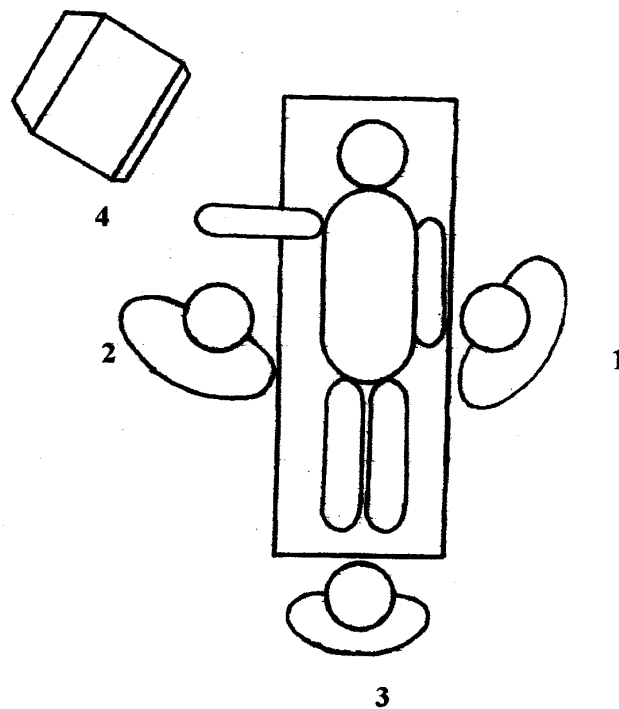


Fig. 1. A schematic arrangement of the operating staff.

1 - a surgeon, 2 - an assistant, 3 - a surgical nurse, 4 - a monitor.

Optimal arrangement of the tools in the abdominal cavity in our work was as follows. We used 4 trocars. The first 10 mm trocar for laparoscopy was introduced 1 cm above the navel along the midline of the abdomen. The second 10 mm trocar for liver and, if necessary, stomach retraction was placed right to the xiphoid process. The third trocar (5 mm) for operation in the right paracolon space and omental sac was placed along the midclavicular line at the level of the navel to the right. The fourth trocar (5 mm) for operation in the left paracolon space and for manipulation in the omental sac was placed two transverse fingers above the navel along the left midclavicular line. The trocar positioning points for diagnostic and therapeutic laparoscopy in patients with acute destructive pancreatitis are presented in Figure 2.

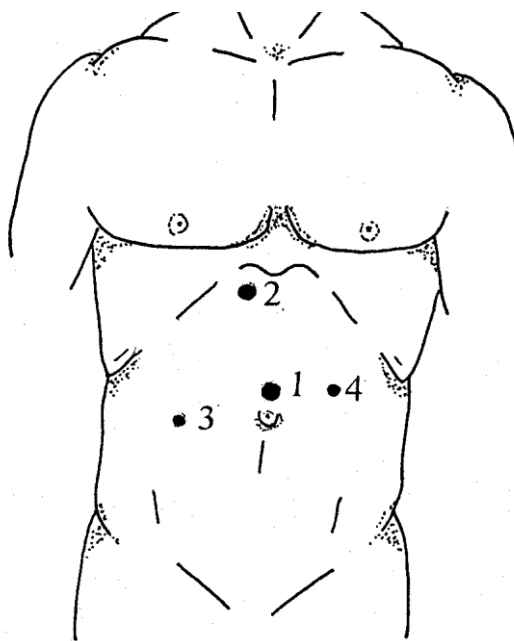


Fig. 2. The trocar positioning points for diagnostic therapeutic laparoscopy in patients with acute pancreatitis

Diagnostic and therapeutic laparoscopy for pancreatogenic peritonitis was conducted in 63% of cases on the first day of hospitalization, in 29% - after 48 hours, in 8% - at a later date. Conducting laparoscopy at different stages of hospitalization depended on the availability of pancreatogenic peritonitis and the efficiency of conservative therapy. Laparoscopy was applied for differential diagnosis in 97% of cases during the first day of hospitalization. Laparoscopy was performed according to indications, mainly in case of the clinic of pancreatogenic peritonitis and - 49%, and during the differential diagnosis - 43%. In this case, laparoscopy on the first indication in 63% of cases was performed on the first day, 29% - on the second day, and in 85 cases - on the third day. In case of differential diagnosis, laparoscopy was performed on day 1 in 97% of patients. Laparoscopy initially required the installation of trocars 1 and 3 for the inspection of the abdominal cavity. Inspection was conducted in compliance with the protocol: the abdomen was examined to detect effusion, assess its character and sample fluid for amylase activity test or "Actim-Pancreatitis" test to confirm the diagnosis or to conduct the differential diagnosis. Abdominal lavage was conducted with various antiseptics, including 0.05% chlorhexidine gluconate aqueous solution saturated with carbon dioxide to reduce the amylase activity or obtain negative results of the "Actim Pancreatitis" test using the "Brusan" apparatus.

Further, the gastro-colonic ligament, small omental sac, lig. mesocolon, paracolon space left and right were inspected. These manipulations required changing the patient's position: raise the head end, turn the body, and use additional trocars 2 and 4. In the case of a large amount of effusion in the retroperitoneal space, lig. mesocolon, and omental sac, the patients underwent the mobilization of paracolon spaces, dissection of colon-splenic ligament, opening of the lig. mesocolon, through drainage of omental sac at the lowest point, and, in the case of a local accumulation of fluid, a common drainage. Drainage of the gallbladder was

performed according to indications: hypertension biliary tract, and obstructive jaundice. The round hepatic ligament was drained for further lymphotropic therapy. The operation ended with the drainage of the abdominal cavity, if necessary, retroperitoneal cavity with the traditional drain tubes and the drain tubes of the original design.

Indications for drainage of omental sac were: aseptic omentobursitis with exudation in the volume of more than 100.0 ml, according to ultrasound data.

Thirty-eight of 291 patients underwent omental drainage, and 21 had the programmed laparoscopic debridement of their abdominal cavity with an increase in endotoxemia and enzymatic peritonitis.

Twenty-one patient, despite the primary diagnostic and therapeutic laparoscopy or the non-compliance of the clinical pattern of endotoxic shock and patho-morphologic pattern in the form of glass-like swelling and without steatonecrosis and hemorrhagic effusion, underwent the programmed laparoscopic debridement of their abdominal cavity with an increase in endotoxemia and enzymatic peritonitis. At the same time, 13 patients of them had it as a programmed debridement, when their morphological pattern served the basis for the indications for repeated laparoscopic treatment of the abdominal cavity. Eight patients underwent the enforced repeated laparoscopy due to the lack of clinical effect of the performed debridement. Repeated laparoscopic debridement in 64% of cases required the application of all trocars (1,2,3,4), (2) and compliance with the manipulation protocol set forth during the "primary" laparoscopy. The programmed debridement was conducted with 0.05% carbonated aqueous chlorhexidine gluconate solution, which had shown its effectiveness in comparison with conventional antiseptics (0.05% aqueous chlorhexidine gluconate solution, 0.9% NaCl ozonized solution) for nosocomial strains in both the experiment and clinic. The operation ended with the drainage of the abdominal cavity, if necessary, retroperitoneal cavity, and omental sac with domestic drain tubes and the drain tubes of the original design.

Debridement of purulent inflammatory processes in the retroperitoneal space and abdominal cavity on an experimental model [17] was performed, if necessary, in two sessions per day for 10-20 minutes each, depending on the stage of wound healing, without any drainage; and the antiseptic solution was prepared by bubbling carbon dioxide in 500 ml tightly sealed 0.05% aqueous chlorhexidine solution for 5 minutes to form a fine fraction antiseptic solution.

To enhance the efficiency of omental drainage, a "through" multi-hole drain was clinically developed and widely used, which is installed after the mobilization and bringing down of the splenic angle of the colon. This mobilization allows for drainage of omental sac in its most sloping site through the formed straight channel through the left lumbotomic hole, and, if necessary, for replacement of the drainage in the postoperative period. Drainage replacement is carried out from right to left along open circle (ring-wise), which corresponds to its name - "ring-drain". A drainage pipe is put on the anterior abdominal wall through the gastro-colonic ligament near the pylorus along the right midclavicular line [16].

Localization of laparoscopic drainage in the omental sac depends on two factors: the severity of the adhesive process in the omental sac, and the location of the fluid accumulation. In the case of mobile omental sac, the drainage is used both in open surgery as through drainage in most shelf sites. In the case of pronounced adhesive process in the omental sac and the accumulation of fluid near the anterior abdominal wall, common drainage is performed.

In case of pathological process spreading in the peripancreatic tissue and the retroperitoneal space, 19 patients for the purpose of decompression and exudate evacuation underwent dissection of parietal peritoneum on the outer contour of duodenum and descending colon under laparoscopic guidance. Nine patients had an original technique of omental drainage conducted.

In the case of peripancreatic infiltration, increasing signs of intoxication and detected fluid structures in the omental sac and retroperitoneal space of more than 50 ml, their puncture was performed under ultrasonic guidance with punctate Gram staining and subsequent bacteriological examination. For its implementation, an "acoustic window" is chosen for the introduction of the trocar, bypassing the large vessels and the intestinal loops. In case of the remaining pneumoperitoneum an original technique for improving the ultrasound imaging was used after laparoscopy [17].

Only in case of dilatation of the gallbladder indicating bile hypertension, the ultrasonic decompression cholecystostomy was performed. The capabilities of the ultrasonic diagnosis of retroperitoneal fat lesions are limited, and, according to our knowledge, are not more than 70%, so patients with common forms of pancreatic necrosis had undergone CT.

For this purpose, special trocars of 3-5 mm in diameter are used and drains with variable geometry of the distal portion. The number of drains is determined by the size of the affected area and the need to use flow-washing systems. Depending on the situation, 1 to 5 drainages are used. After the pus evacuation, a dynamic ultrasound is performed, which allows determining the effectiveness of drainage. For its improvement, we used bougienage of sinus tracts. If necessary, fistulography was conducted. Eight patients underwent fistula channel expansion under ultrasound and endoscopic guidance with visual inspection, debridement, sequestrectomy and drain installation of larger diameter. Further, the abscessed area was treated with the use of low-frequency ultrasound device YPCK-7H-18 with a special nozzle. Ultrasound frequency was $26.5 \text{ kHz} \pm 7.5\%$ lasting from 30 seconds to 4.3 minutes, accompanied by bacteriological monitoring. As a result, we have managed to increase the effectiveness of sloughing, and the multiplicity of sessions ranged 3 to 7, reducing thereby bacterial contamination: E.Coli - 10^3 , St. aureus - 10^3 .

The elimination of purulent intoxication and the confirmation of the cleansing of the cavities according to ultrasound data allowed to discharge patients to outpatient follow-up care with drainage. After re-hospitalization in the "cold" period of the disease, a question arose about the possibility of removing the tubes. Depending on the course of purulent inflammatory process, the drainage period ranged from 1 to 4 months. Different variants of the drainage under ultrasonic guidance in pancreonecrosis were applied in 69 patients, 39 (57%) of them underwent it as an independent method of treatment. In one case, it was noted an erosive bleeding and the formation of high-enteric fistula. We considered these complications as a result of the reevaluation of capabilities of puncture drainage, which resulted in delayed laparotomy and death.

We would like to emphasize that using this method one should take into account its real possibilities, which allow only for partial evacuation of tissue detritus and sequesters being the main sources of endogenous intoxication. Therefore, the presence of free-lying sequesters larger than 2 cm in the spread purulent focus serves as an indication for laparotomy and necrosectomy. At the final stage of surgery, marsupialization and drainage of omental sac were performed using different types of drains, developed in our clinic. The omental sac was drained predominantly with spiral drain [16], equipped with broad spaces for the evacuation of necrotic masses. Drainage may be also carried out with 10 and 5 mm trocars using laparoscopic techniques. Spiral part of the drain is placed into the omental cavity. Removal of drainage is carried out in usual manner in a dressing room without anesthesia.

RESULTS

A retrospective analysis of the treated surgical patients with destructive pancreatic necrosis revealed that the number of destructive forms of pancreatitis increases every year, the surgical activity has grown during last 4 years and even exceeded the first period of active surgical tactics at the expense of increased number of minimally invasive procedures. Mortality in recent time declines in the general group, primarily in the group of patients with moderate condition (5%, group 2 - 9.8%). It was found that the ratio of mortality from the early and late toxic postnecrotic complications has changed significantly. The early toxic complications were 86.5% in group 1 (1987-1993), and 75.7% in group 2 (1994-1999), and in time interval between 2002 and 2004 they were already 64%. Currently, mortality occurs mostly in the later stages, i.e. the stage of purulent complications.

SUMMARY

Despite the steady increase in the incidence of destructive forms of acute pancreatitis, the use of a differentiated approach, where the alternative to early surgical intervention is a therapeutic laparoscopy and puncture drainage methods under ultrasound guidance, increased the surgical activity and reduced the overall postoperative mortality rate up to 13.4%. Depending on the severity of pancreatic necrosis, the mortality rate was as follows: in moderate pancreatic necrosis it reduced up to 5%, and in its severe forms - up to 26%.

Postoperative mortality after "early" operations conducted in the first stage of acute pancreatitis (1987-1994) was 37.2%. In this case, early septic complications prevailed, reaching 86.5%. Postoperative mortality after "forced" operations (1994-1999) was reduced by 2 times - 17.3%, since the latter involved drainage (laparotomy with marsupialization, drainage of omental sac and abdominal cavity) without radicalism, and the rate of laparotomy decreased by 35% during the first 5 days of the onset of the disease. This is due to the active introduction of diagnostic and therapeutic laparoscopy. Nevertheless, the operation was quite traumatic, since carried out in reactive stage, or during generalization of purulent process - were retarded. Modern tactics (2000) are the therapeutic manipulation performed under either ultrasound or laparoscopic guidance. Laparotomy in this group was conducted mostly in case of no effect of the treatment, starting from the 3rd week of the onset of the disease. This approach allowed us to improve the surgical activity and reduce the overall postoperative mortality rate up to 13.4%. The mortality rate in moderate pancreatic necrosis has been reduced up to 5%, and in its severe forms - up to 26%. We should also emphasize that the use of diagnostic and therapeutic laparoscopy reduces the number of laparotomies, lumbotomies, and increases the effective opportunity for minimally invasive manipulation under ultrasound guidance. Using laparoscopy changed the spectrum of complications. It reduced the number of early toxic complications up to 32% and the mortality rate in these terms (12%). At the same time, it increased the number of late postnecrotic complications up to 68%, which influenced the increase in the number of puncture and drainage under ultrasound guidance.

Thus, the comparative analysis of different approaches of treatment of acute pancreatitis revealed that the most appropriate for patients is a differentiated approach with the use of minimally invasive techniques: laparoscopy, puncture under ultrasound guidance. This tactic can reduce mortality and the number of early toxic complications. At the same time, it increases the rate of late postnecrotic complications requiring their adequate treatment. Using the laparoscopic arsenal for treatment of acute pancreatitis allowed us to improve the surgical activity and reduce the overall postoperative mortality rate up to 13.4%. Depending on the severity of pancreatic necrosis, the mortality rate was as follows: in moderate pancreatic necrosis it reduced up to 5%, and in its severe forms - up to 26%. According to the initial treatment strategy of acute pancreatitis, the use of diagnostic and therapeutic laparoscopy is effective in patients with moderate aseptic and infected pancreatic necrosis. The use of laparoscopy seems to be very interesting and promising in retroperitoneal surgery in patients with acute pancreatitis.

ACKNOWLEDGEMENTS

The work is performed according to the Russian Government Program of Competitive Growth of Kazan Federal University.

REFERENCES

- [1] Beburishvili A.G., Burchuladze N.Sh., Mandrikov V.V. - Gradual treatment of acute pancreatitis and its outcomes / 9th All-Russia congress of surgeons. 1999. - Pp. 15-16
- [2] Vinnik Iu.S., Cherdantsev D.V., Miller S.V., Pervova O.V., Miller M.S. - Influence of the surgical intervention on the systemic inflammatory response syndrome in necrotizing pancreatitis / International Surgical Congress. 2003 - 31 p.
- [3] Galperin E.I., Diuzheva T.G., Dokuchaev K.V. - Minimally invasive interventions into omental and retroperitoneal fat for the prevention and treatment of infected pancreatic necrosis // International Surgical Congress. 2003, - 56 p.
- [4] Saveliev V.S., Filimonov M.I., Gelfand B.R., Burnevich S.Z. Destructive pancreatitis: diagnosis and treatment algorithm (The project is based on the proceedings of IX All-Russian Congress of Surgeons, held on September 20-22, 2000, in Volgograd.) // Consilium Medicum, 2000, Vol.2, No. 6.- OnLine.
- [5] Beger H.G., Rau B., J.Mayer, U. Pralle. Natural course of acute pancreatitis. // World J Surg 1997. V. 21(3). P 130-135.
- [6] Beger H. G, Isenmann R. Surgical management of necrotizing pancreatitis // Surg. Clin. N. Amer. 1999. Vol., 79 - No. 4 – P. 793 –800.
- [7] Isenmann R, Schwarz M, Rau B, Trautmann M, Schober W, Beger HG Characteristics of infection with Candida species in patients with necrotizing pancreatitis. // World J Surg. 2002. - V. 26. - P.372–376
- [8] Frey C.F., Brandley E.L., Beger H.G. Progress in acute pancreatitis // Surg. Gynecol. Obstet. 1988. – V. 167. P. 282–288.

- [9] Freeny P.C., Hauptmann E., Althaus S.J., et al. Percutaneous CT-guided catheter drainage of infected acute necrotizing pancreatitis: Techniques and results. // Amer. J. of Roentgenology. 1998. № 170 P. 969-975.
- [10] Lee M.J., Wittich G.R., Mueller P.R. Percutaneous intervention in acute pancreatitis. // Radiographics. 1998. №18 P. 711-724.
- [11] Carter C.R., McKay C.J., Imrie C.W. Percutaneous necrosectomy and sinus tract endoscopy in the management of infected pancreatic necrosis: An initial experience. // Ann. of Surg. 2000. №232. P. 175-180.
- [12] Grzebieniak Z., Woyton M., Kielan W. Surgical and endoscopic treatment of pancreatic pseudocysts. Przegl. Lek. 2000. № 57(Suppl 5). P. 50-52.
- [13] Cuschieri A. Pancreatic necrosis: pathogenesis and endoscopic management. // Semin. Laparosc. Surg. 2002 Mar. № 9. P. 54-63.
- [14] Hamad G.G., Broderick T.J. Laparoscopic pancreatic necrosectomy. J. Laparoendosc. Adv. Surg. Tech. 2000. №10. P. 115-118.
- [15] Baron T.H., Thaggard W.G., Morgan D.E., et al. Endoscopic therapy for organised pancreatic necrosis. // Gastroenterology. 1996. № 111. P.755-764.
- [16] Malkov I.S., Shaimardanov R.Sh. Acute pancreatitis. - Kazan. 2001, - 60 p.
- [17] Malkov I.S., Alukaev M.I., Zainutdinov A.M., Sharafislamov I.F., Kirshin A.P. A diagnostic method for diseases of the abdominal cavity and retroperitoneal space // A favorable decision on granting a patent for the invention of the Russian Federation No. 2003120741 / 021929 of 07.07.2003.