

Research Journal of Pharmaceutical, Biological and Chemical Sciences

Neurovascular Foramina of The Human Clavicle and Their Clinical Significance.

G Sowmiya*, S Sundarapandian, and V Nithya.

Department of Anatomy, SRM Medical College and research centre, Kattankulathur, Chennai.

ABSTRACT

The clavicle is a modified long bone. It is the most important bone for transmission of body weight from upper limb to the axial skeleton and for muscle attachments and is significant source for bone grafting. To study the neurovascular foramina of the human clavicle and their clinical significance This study comprised of 110 human clavicles, which were collected from the department of anatomy, SRM medical college, Chennai. Length of the clavicle, location, number and direction of the nutrient foramina of the clavicle were observed macroscopically by using non-stretchable thread, geometrical ruler, needle and hand lens. The foramen index was calculated by applying the Hughes Formula. The nutrient foramina were observed in 103 (93.6%) clavicles and found absent in 7 (6.4%). The foramen was single in 80 (72.7%) clavicles, double in 18 (16.4%), and more than 2 foramina were present in 5 (4.5%). The foramen were observed at the posterior surface of the medial 1/3rd of the clavicle in 10 (9.1%), at the inferior surface of the medial 1/3rd of the clavicle in 3 (2.7%), at the posterior surface of the middle 1/3rd of the clavicle in 70 (63.6%), at the inferior surface of the middle 1/3rd of the clavicle in 24 (21.8%), at the superior surface of the middle 1/3rd of the clavicle in 6 (5.5%), at the inferior surface of the lateral 1/3rd of the clavicle in 7(6.4%). The for a minal index was 47.31%. The nutrient foramina of the human clavicle was present mostly in the posterior surface when compared to inferior surface of the middle 1/3rd of the clavicle , the nutrient foramina of the clavicle were often multiple and directed towards the acromion end. Knowledge of the localization of the nutrient foramen can be useful in certain surgical procedures to preserve the microcirculation.

Keywords: Clavicle, Nutrient Foramen, Nutrient Artery, Foraminal Index

**Corresponding author*

INTRODUCTION

The clavicle or collar bone is the only long bone that lies in the horizontal plane. It differs from the other long bones, does not possess a medullary cavity. It has a sternal end and an acromial end and it is divided into medial 2/3rd and lateral 1/3rd. At the inferior surface, presence of groove for subclavius muscle [12], at the lateral end of the groove there is presence of a foramen called nutrient foramen. Some authors say that a small foramen may be present in the middle one third of the clavicle, along the inferior surface. This foramen transmits the nutrient artery a branch of suprascapular artery and supraclavicular nerve. Anatomically this foramen is present in 2-6% of the population. It is important that the arterial supply be preserved in free vascularised bone grafts, so that the osteocytes and osteoblasts survive [1]. Clinical fracture of a long bone is usually accompanied by rupture of the nutrient artery with variable disruption of the peripheral vessels associated with periosteal detachment. The nutrient artery is the principle source of blood to a long bone particularly during its active growth period. Some authors reported that, the clavicle is supplied by periosteal arteries and no nutrient artery was found. However, few authors have suggested that the supra scapular artery supplies the middle third of the clavicle by a nutrient branch. An absence of nutrient foramina in some bones has been observed, in which case the periosteal vessels become the sole source of the blood supply Knudsen et al. (1989) [7]. Nutrient foramen is important in relevance to fracture treatment. Though clavicle developed from intra membranous origin it comes under the long bone, so it has its own nutrient artery, it does not depend on it. When there is no foramen in the clavicle, the blood supply is comes from the periosteal network. The blood supply of the clavicle has three sources they are supra scapular artery, thoracoacromial artery and the internal thoracic artery. The topographical knowledge of these foramina is useful in certain operative procedures to preserve the circulation of the clavicle.

MATERIALS AND METHODS

The study included 110 adult human clavicles (56 right sides and 54 left sides) which were obtained from the anatomy department of SRM medical college hospital and research centre, Chennai. The bones were free from gross pathological changes and damages. A magnifying lens was used to observe the foramina. The nutrient foramina were distinguished by the presence of a well marked groove leading to the foramen, often slightly raised edge of the foramen at the commencement of the canal. For the direction of the canal a fine stiff wire was passed through the foramen to confirm its direction [1].

The number and topography of the foramina in relation to specific surfaces were analysed. The lengths of the clavicles were measured by using an inelastic thread and each was divided into three equal parts and the location of the foramen was noted. The location of the foramen in relation to the surface of the clavicle also was observed. A needle was used to distinguish the patency of the foramen. All the findings were tabulated and analysed statistically by using student 't' test. The foramen index (FI) was calculated for each clavicle by applying the Hughes formula [1, 10, 11 & 13], dividing the distance of the foramen from the sternal end (D) by the total length of the bone (L), which was multiplied by 100.

$$FI = D/L \times 100$$

The foramen index was determined for all the clavicles and the foramina were topographically classified with respect to 1/3 regions (medial 1/3, middle 1/3 and lateral 1/3). The data were morphologically analyzed and tabulated.

RESULTS

Number of nutrient foramina of the clavicle Fig (1)

The statistical analysis shows that the nutrient foramina were observed in 103 (93.6%) clavicles and found absent in 7 (6.4%). The foramen was single in 80 (72.7%) clavicles, double in 18 (16.4%), and more than 2 foramina were present in 5 (4.5%). [Table1].

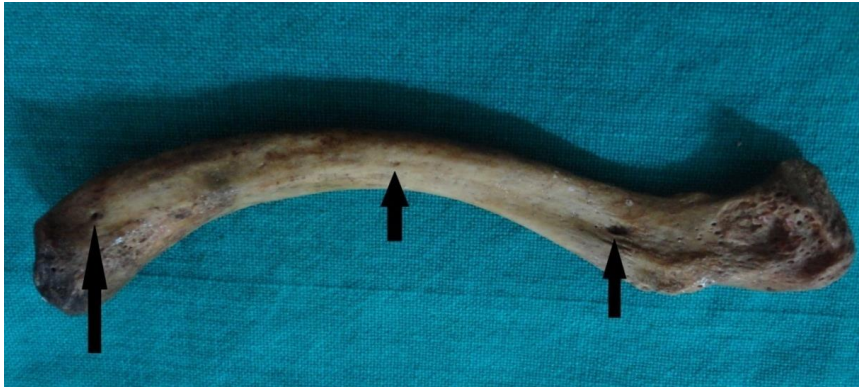

Figure 1: Clavicle with multiple foramen.

Table I: Number of nutrient foramina of the clavicle.

Presence of foramina	Number of foramina	Percentage%
Absent	7	6.4 %
Single	80	72.7%
Double	18	16.4 %
Triple	4	3.6%
More than 3	1	0.9%
Total	110	100%

Topography of the nutrient foramina in right and left side Fig (5, 7, 6, 3,2&4)

The foramen was observed at the middle 1/3 region in 100 (90.9%) clavicles, at the medial 1/3 region in 13 (11.8%) clavicles and at the lateral 1/3 region in 7 (6.3%) clavicles. The foramen was on the inferior surface in 34 (30.9%) clavicles, on the posterior surface in 80 (72.7%) clavicles and on the superior surface 6 (5.4%) clavicles. The foramen were observed at the posterior surface of the medial 1/3rd of the clavicle in 10 (9.1%), at the inferior surface of the medial 1/3rd of the clavicle in 3 (2.7%), at the posterior surface of the middle 1/3rd of the clavicle in 70 (63.6%), at the inferior surface of the middle 1/3rd of the clavicle in 24 (21.8%), at the superior surface of the middle 1/3rd of the clavicle in 6 (5.5%), at the inferior surface of the lateral 1/3rd of the clavicle in 7(6.4%). [Table 2]

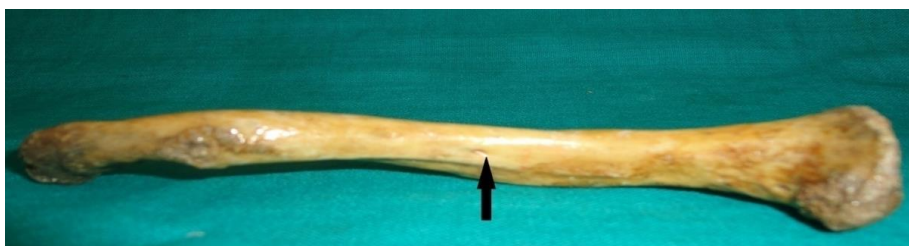

Figure 2: Nutrient foramen in the posterior surface of the clavicle

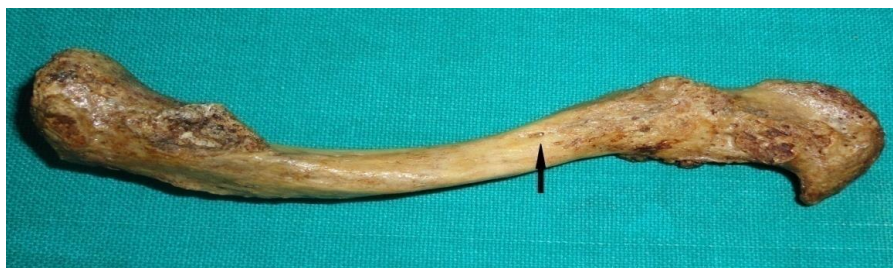

Figure 3: Nutrient foramen in the inferior surface of the clavicle.



Figure 4: Nutrient foramen in the superior surface of the clavicle.



Figure 5: Location of the nutrient foramen in the medial 1/3rd of the clavicle.

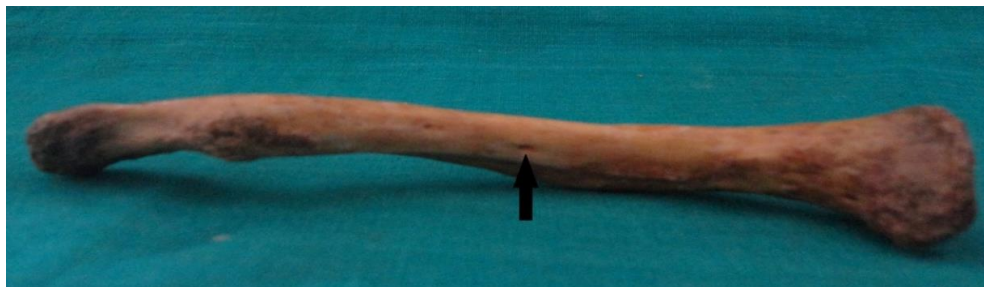


Figure 6: Location of the nutrient foramen in the middle 1/3rd of the clavicle.



Figure 7: Location of the nutrient foramen in the lateral 1/3rd of the clavicle.

Table 2: Topography of the nutrient foramina in right and left side

Topography of NF	Right side	Left side
Posterior medial 1/3	4 (40%)	6 (60%)
Inferior medial 1/3	0	3 (100%)
Posterior middle 1/3	39 (59.7%)	31 (44.3%)
Inferior middle 1/3	10 (41.7%)	14 (58.3%)

Superior middle 1/3	5 (83.3%)	1 (16.7%)
Inferior lateral 1/3	5 (71.4%)	2 (28.6%)
Mean foraminal index	6 (46.91)	54 (47.93)

Direction of the nutrient foramen Fig (8)

In 98 (95.1%) clavicles, the foramen were directed toward the acromial end and in 5 (4.8%) clavicles had medially directed foramina [Table 4]. The average whole length of the human adult clavicle was 10.9 – 16.9cm and the mean value of the whole length was about 142.68mm (14.268 ± 1.2035). The average distance of the nutrient foramen from the sternal end of the clavicle was about 0 - 11.6 cm and the mean value of the sternal end was about 67.65mm (6.765 ± 2.3404) [Table 5]. By using Hughe’s formula the mean foraminal index was 47.31%. The average length of the clavicle was 14.4cm. By using Hughes’s formula the mean foraminal index was 47.31% [Table 5].

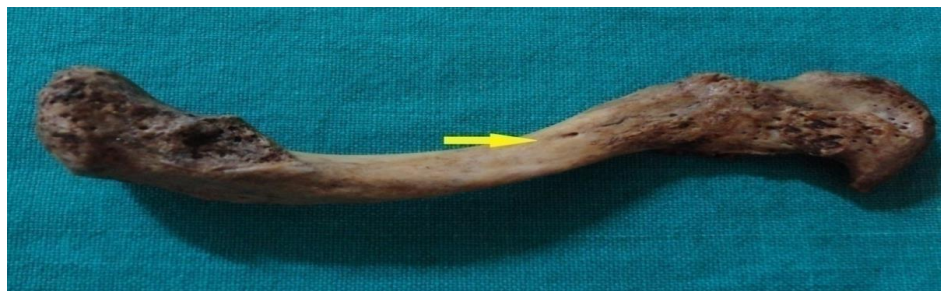

Figure 8: Direction of the nutrient foramen towards the acromial end.

Table 3: Topography of the Nutrient foramen, Number and Percentage

LOCATION OF THE FORAMINA	NUMBER	PERCENTAGE %
At the posterior surface of medial 1/3 rd	10	9.1
At the inferior surface of medial 1/3 rd	3	2.7
At the posterior surface of middle 1/3 rd	70	63.6
At the inferior surface of middle 1/3 rd	24	21.8
At the superior surface of middle 1/3 rd	6	5.5
At the inferior surface of lateral 1/3 rd	7	6.4

Table 4: Direction of the nutrient foramen

S.no	Direction	Number	Percentage
1.	Sternal end	5	4.8%
2.	Acromial end	98	95.1%

Table 5: Mean and Standard Deviation of the whole length and the sternal end

	Mean	SD
Whole length	14.268	1.2035
Sternal end	6.765	2.3404

SD – standard deviation
Hughe’s index = 47.31%

Table 6: Descriptive statistics of topography, Number of the nutrient foramen.

Topography of NF	X ²	DF	P
Posterior middle 1/3	3.379	1	0.06
Inferior middle 1/3	0.677	1	0.411
Posterior medial 1/3	0.364	1	0.546
Inferior lateral 1/3	1.493	1	0.222
Superior middle 1/3	2.97	1	0.084
Inferior medial 1/3	2.974	1	0.085

DISCUSSION

Rahul rai et al., (2014) [11] observed that the most of the clavicles contained nutrient foramina at middle 1/3 region and on posterior surface. Hetalben G.Patel et al., (2014) [4] suggested that all foramina were directed towards the acromial end, which shows that the sternal end of the clavicle is the growing end. The position of the foramen was not constant. It is mostly at the posterior surface in 79.16% clavicles and in middle 1/3 region in 82.29%. Nita A Tanna., (2015) [13] observed that the most of the clavicles contained nutrient foramina at the middle 1/3rd region and on the posterior surface. The foramen index was 49.01. It gives the position of the nutrient foramen. Pushpalatha M et al., (2015) [10] reported that the neurovascular foramen was observed in 96.1% of the clavicles. Our findings suggest that it is more common on its posterior surface. The foramen is often multiple and directed towards the acromial end.

Knudsen et al. (1989) [7] stated that the clavicle get nourishment through the suprascapular, thoracoacromial and internal thoracic arteries. According to these authors, the clavicle is supplied by periosteal arteries and not by the nutrient artery. Kumar et al. (1989) [6] reported that these nutrient foramina contain medial fascicle of the supraclavicular nerve along with the nutrient artery. Few authors hypothesize that with respect to the development of the blood supply to the clavicle, there could be nutrient artery to the primary centre of ossification and to the late secondary centre at the sternal end of the clavicle. It was explained that the clavicle growth would be in an acromio-sternal direction.

Many theories have been put forward to account for the direction of the foramina and also the anomalously directed ones. Among them, the ‘periosteal slip’ theory of Schwalbe and the vascular theory of Hughes are widely accepted the literature [5]. Patake SM and Mysorekar VR (1977) [9 & 8] opined that the number of foramina does not seem to have any significant relation to the bone. They described that the number of foramina may not have relation to the number of ossification centres, because the femur, which is having one primary centre, usually has two foramina and the clavicle with two primary centers, has generally a single foramen. It was suggested that the direction of nutrient foramina is determined by growing end of the bone. In our present study, we observed that most of the foramina were directed towards the acromial end, which shows that the sternal end of the clavicle is the growing end. The present study supports the reports of Fischer et al (1978) [2] and carret, Kumar et al., (1989) [6] and Havet et al. (2008) [13] that the clavicle has nutrient foramina and is supplied by nutrient artery.

Eric Havet et al., (2008) [3] reported that the arterial supply of the clavicle to clarify the pathological mechanism and the surgical procedure of non-unions. The main blood supply to the middle third of the clavicle is periosteal artery. The nutrient foramen of the clavicle is present at the inferior surface [12]. But the present investigation observed that the topography of the foramen was not constant, it was not present at the anterior surface of the clavicle, but mostly at the posterior and the inferior surfaces. We suggest that the model of standard textbooks of anatomy needs revision. According to most of the authors opined that the clavicle obtains nutrition from the periosteal vascular network.

CONCLUSION

According to previous works on the nutrient foramen of the human adult clavicle was present in the inferior surface, at the lateral end of the groove for subclavius muscle or the posterior surface. In the present study it was found that the nutrient foramina of the human clavicle was present mostly in the posterior surface when compared to inferior surface of the middle 1/3rd of the clavicle , the nutrient foramina of the

clavicle were often multiple and directed towards the acromion end. Knowledge of the localization of the nutrient foramen can be useful in certain surgical procedures to preserve the microcirculation. Surgical procedure such as coracoclavicular ligament repair, bone grafting, surgical procedure for internal fixation and also for biomedical engineers for designing the model of the clavicle

ABBREVIATION

NF - Nutrient foramen
 χ^2 - Chisquare
DF - Degree of freedom
SD - Standard Deviation

REFERENCES

- [1] B.V.Murlimanju. Neurovascular foramina of the human clavicle and their clinical significance, *surg Radiol Anat* 2011;33:679-682.
- [2] Fischer LP, Carret JP. Vascularisation artérielle des os chez l'homme. *Bull Assoc Anat* 1978; 62:419-454
- [3] Havet E, Duparc F, Tobenas-Dujardin A-C, Muller J-M, Delas B, Freger P (2008) Vascular anatomical basis of clavicular non-union. *Surg Radiol Anat* 30: 23-28.
- [4] Hetalben G. Patel, Dayanand B, C.A.Pensi, nutrient foramen of the dry human clavicle and their clinical significance (2014)
- [5] Hughes H. The factors determining the direction of the canal for the nutrient artery in the long bones of mammals and birds. *Acta Anat (Basel)*. 1952; 15(3):261-280
- [6] Kumar R, Lindell MM, Madewell JE et al (1989) The clavicle: normal and abnormal. *Radiographics* 9: 677-706.
- [7] Knudsen FW, Andersen M, Krag C (1989) The arterial supply of clavicle. *Surgical Radiological Anatomy* 11: 211-214
- [9] Mysorekar VR, Diaphysial nutrient foramina in human long bones, *J Anat*, 1967, 101 (Pt 4):813-822.
- [10] Patake SM, Mysorekar VR, Diaphysial nutrient foramina in human metacarpals and metatarsals, *J Anat*, 1977, 124 (Pt 2):299-304.
- [11] Pushpalatha M, Sharmadha K. L, Meenakshi P. "Topographic Anatomy and Morphology of Nutrient Foramen of the Clavicle: An Osteological Study". *Journal of Evidence based Medicine and Healthcare*; Volume 2, Issue 6, February 9, 2015; Page: 729-735.
- [12] Rahul Rai, Shrestha S, Kavitha B. Morphological and topographical anatomy of nutrient foramen in human clavicles and their clinical importance. *IOSR-JDMS* 2014; 13(1):37-40.
- [13] Standring S (ed) (2006) *Gray's anatomy. The anatomical basis of clinical practice*, 39th edn. Churchill Livingstone, Spain, pp 817-818
- [14] Tanna NA, Tanna VA. Anatomical variation in position, direction, and number of nutrient foramina in clavicles. *Int J Med Sci Public Health* 2015; 4:357-359