

Research Journal of Pharmaceutical, Biological and Chemical Sciences

Topical Clobetasol (0.025%) and Tacrolimus (0.1%) in the Management of Oral Lichen Planus: A Comparative Study.

Milanjeet Kaur¹, Noopur Managoli Kulkarni², Rahul Kathariya^{3*}, Sharath Chandra Bontha⁴, Sunanda C Chavva¹, and Mamatha B Krishna¹

¹Panineeya Mahavidyalaya, Institute of Dental Science & Research Centre, Hyderabad-500060, India.

²Department of Oral Pathology & Microbiology, Pandit Deendayal Upadhyay Dental College, Solapur- 13255, Maharashtra, India.

³Dental Galaxy, 1443 Shukrawar Peth, Bajirao Road, Pune-411002, India.

⁴Department of Oral Medicine and Radiology, Swargiya Dadasaheb Kalmegh Smruti Dental College, Nagpur-441110, India.

ABSTRACT

Oral lichen planus (OLP), an autoimmune disorder is notorious for its recurrences and recalcitrant cases. Recent clinical trials show Clobetasol 0.025% to be as effective as 0.05% concentration which is the usual concentration used to treat OLP. The aim of this study was to compare the effectiveness of topical Clobetasol 0.025% (concentration less than that is used clinically) and topical Tacrolimus 0.1% in a mucoadhesive base for the management of symptomatic OLP in the South Indian population. Forty patients (26 females and 14 males) clinically and histologically diagnosed with oral lesions consistent with OLP were recruited. The patients were divided into 2 groups: Group 1: Clobetasol 0.025% and Group 2: Tacrolimus 0.1% ointment and were treated for 4 weeks and then followed up for 6 months. At the end of the treatment period, symptom, and grading scores were less in both the groups. However, when both the drugs were compared statistically, no significant difference was found between the two groups. Within the limitations of the present study, it can be concluded that topical Clobetasol 0.025% is as effective as 0.1% topical Tacrolimus ointment.

Keywords: Oral Lichen Planus; Topical Clobetasol; Topical Tacrolimus.

**Corresponding author*

INTRODUCTION

Oral lichen planus is a mucocutaneous disorder with a prevalence of approximately 1-2% [1]. Various existing treatment options of OLP include topical and systemic corticosteroids, topical and systemic retinoids, cyclosporins, griseofulvin, hydroxyquinone, dapsone, mycophenolate, CO₂ laser, thalidomide, lower molecular weight heparin etc [2]. Among these topical corticosteroids is the most accepted treatment modality for OLP.

Clobetasol propionate in a concentration of 0.05% used clinically is probably one of the most effective drugs used in the topical management of OLP. It is an analogue of prednisolone which has anti-inflammatory, antipruritic, vasoconstrictive and immunosuppressive properties [3,4]. Recently, Tacrolimus (FK 506), an immunosuppressant macrolide lactone antibiotic produced by *Streptomyces tsukubaensis* has also shown promising results [5].

There are no reported studies in the published literature on comparison of topical 0.1% Tacrolimus and 0.025% Clobetasol ointment (less than that is used clinically) for treatment of OLP in Indian population. The commonly used oral ointments are not mucoadhesive, so we especially prepared a mucoadhesive base for better treatment outcome of both the topical ointments.

MATERIALS AND METHODS

This study was conducted on 40 clinically and histopathologically confirmed cases of symptomatic atrophic and erosive Oral Lichen Planus of Panineeya Dental college, Hyderabad. The research project was approved by the Institutional Scientific and Ethical Committees and Review Boards. All the participants were clearly explained the need and design of the study. All the patients received complete verbal and written information about the study and informed consent was taken from those willing to participate voluntarily.

Patients who were elder than 18 years of age, with clinically and histopathologically confirmed symptomatic OLP were included in the study. Patients suffering from any other systemic diseases; mucosal diseases or skin lesions which may be associated with oral lesions; patients on any drug therapy which may cause or cure Lichen Planus like lesions; and pregnant and lactating mothers were excluded from the study. All recruited patients were divided into two age and sex matched groups to receive one of the two treatment modalities.

Group 1: 20 Patients received Clobetasol propionate in 0.025% concentration

Group 2: 20 Patients received Tacrolimus in 0.1% concentration

Drug preparation:

Both the drugs were prepared in a mucoadhesive base. Tacrolimus drug (Glenmark pharmaceuticals) and Clobetasol propionate in powder form was obtained. Drugs were prepared in College of Pharmacy, Guru Nanak Group of Institutions, Ibrahimpatanam. Powder form of the drug was weighed over an electronic weighing machine by using a piece of butter paper (weight of butter paper was subtracted). The drugs were then mixed with orabase and preservatives (methyl and propyl paraben) in a homogenizer with speed regulator to achieve a final concentration of 0.025% of Clobetasol propionate and 0.1% of Tacrolimus. 100 grams of orabase was prepared by mixing 20 gms of hydroxypropylcellulose, 10 gms of Carbapol and sufficient quantity of water.

Investigations:

Patients were subjected to complete blood investigation (Hb%, total RBC, total WBC, differential leucocyte count) and random blood sugar analysis. Incisional biopsies were done once all the parameters were satisfied.

Patients were asked to apply medication after food 3 times daily for 4 weeks.

The clinical data were scored according to the criteria scale used by Thongprasom and Co Workers [6]:

- Score 0: no lesions
- Score 1: hyperkeratotic lesions
- Score 2: atrophic areas $\leq 1 \text{ cm}^2$
- Score 3: atrophic areas $\geq 1 \text{ cm}^2$
- Score 4: erosive areas $\leq 1 \text{ cm}^2$
- Score 5: erosive areas $\geq 1 \text{ cm}^2$

The lesion was graded by two different examiners and accordingly average score was given at each visit.

The symptom score was obtained using a visual analogue scale (VAS). The VAS consisted of a 10 cm horizontal line marked 0 (= no pain) to 10 (= most severe pain). Patients were requested to mark the scale at each visit.

Recall was done every 15 days and clinical effects of treatment were graded for size of the lesion and pain and burning sensation for 6 weeks. The patients were also instructed to refrain from eating, drinking, and talking for at least 30 minutes after application of the drug. After which the patients were advised to gargle and swish off the medication. Patients were also instructed not to swallow the medication. After a therapy of 4 weeks patients were examined again after 15 days to note the signs of recurrence. Patients were also instructed to report again after 3 and 6 months or whenever they develop any signs of recurrence.

Statistical analysis:

Data was calculated as means, standard deviation and standard error of mean. Results were compared by using SPSS 19.0 version software. Non parametric test i.e. Mann Whitney U test was used to compare the efficacy of both the drugs.

RESULTS

The age of the patients in two groups varied from 18-66 yrs and most patients were above 40 yrs of age (55%). Out of 40 patients, 26 were females (65%) and 14 were males (35%). The male to female ratio was 1:1.8. All the patients had atrophic/erosive type of OLP and several patients had additional reticular lesions as well. Among them, 22 had atrophic type (55%) and 18 had erosive type of Lichen Planus (45%). Lesions were found most commonly on buccal mucosa and vestibule (36 i.e. 46.15%), followed by attached gingiva (17 i.e. 21.79%), tongue (14 i.e. 17.94%), labial mucosa and vestibule (5 i.e. 6.41%), palate (4 i.e. 5.12%) and floor of the mouth (2 i.e. 2.56%) (Figure 1).

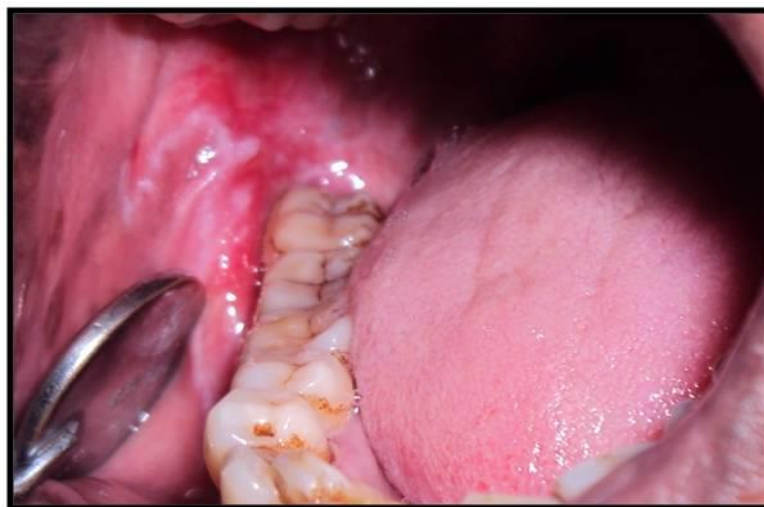

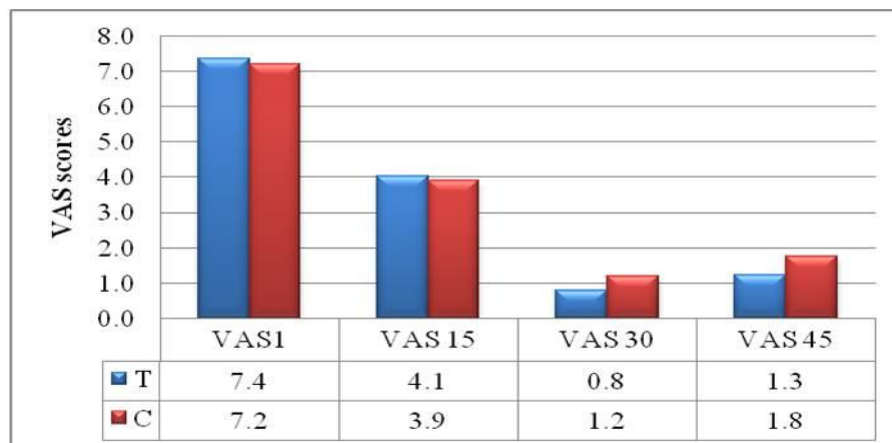
Figure 1: Erosive Lichen Planus before treatment.

The complaint of burning sensation was universal to all patients. All patients showed improvement after initiation of the therapy. At the end of the trial, none of the patients reported any major adverse drug reactions to either of the drugs. None of them developed oral candidiasis as the duration of study was small and none of the patients were immunocompromised. None had difficulty in applying the drug except 3 patients who complained of burning sensation on applying Tacrolimus during the initial period which resolved within 4-5 days. Even during that period those 3 patients found a decrease in discomfort caused by spicy food. Analyzing data in terms of efficacy of both the drugs using Mann Whitney U test showed no statistically significance i.e. p value was >0.05 between the two groups. There was no statistical difference between signs and symptoms but a substantial proportion of the subjects (70%) achieved complete remission. Score 1 was taken as healed lesion. 16 patients of Tacrolimus group (80%) and 12 patients of Clobetasol propionate group (60%) achieved complete remission after 30 days. (Figure 2).

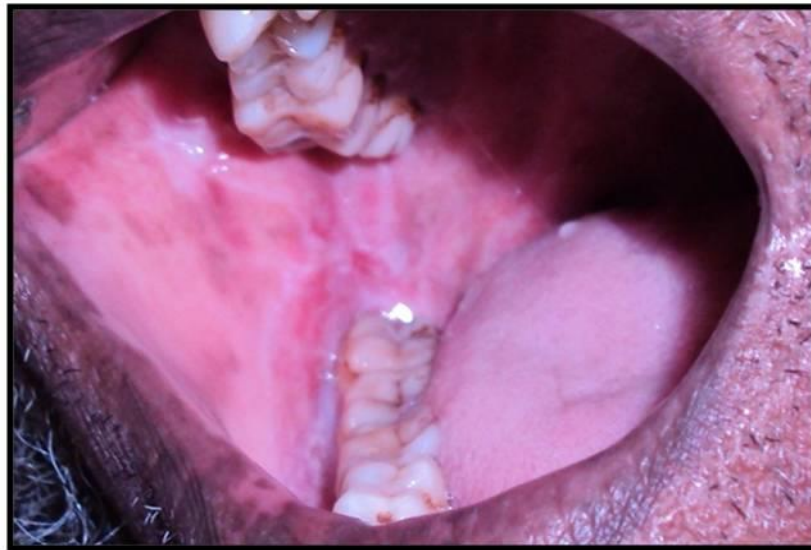

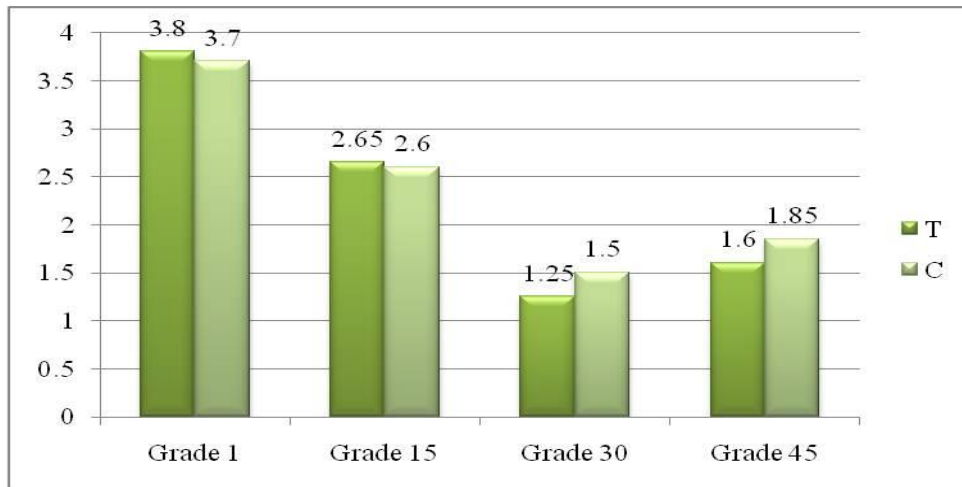
Figure 2: Same patient after treatment.

Relationship between the initial visit VAS scores and VAS score after 30 days of treatment in both the groups was observed. In Clobetasol group initial VAS scores of 9-10 reduced to 3-2 after 30 days of treatment while it ranged from 0-2 in Tacrolimus group. Initial VAS scores of 8-3 changed to 0-3 in both the groups. Again, a rise in VAS score was observed within 15 days of discontinuation of the therapy in both the groups but more so in Clobetasol group. The mean value of VAS was 7.4 in Tacrolimus and 7.2 in Clobetasol drug group which reduced to 0.8 and 1.2 respectively after 30 days and 1.3 and 1.8 respectively after 45 days showing a better response in Tacrolimus drug group (Graph 1).



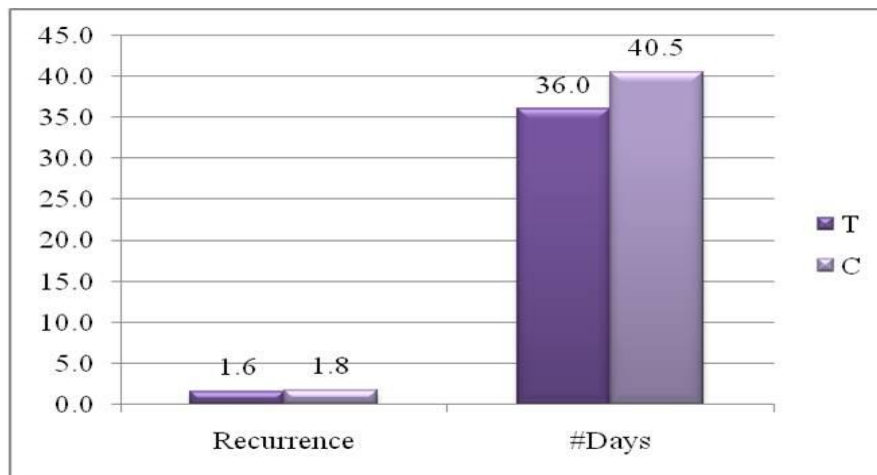
Graph 1: Bar diagram comparing vas scores of both the drugs at every 15 days interval over a period of 45 days.

Similarly, a decrease in the clinical grading score was seen during the treatment phase with a rise after discontinuation of the therapy. The mean initial grading scores were 3.8 for Tacrolimus drug group and 3.7 for Clobetasol drug group which reduced to 1.25 and 1.5 after 30 days and 1.6 and 1.85 after 45 days respectively in both the groups (Graph 2).



Graph 2: Bar diagram every 15 days interval over a comparing grading of both the drugs at period of 45 days.

In Tacrolimus group 8 patients (40%) had no recurrence even after 6 months of discontinuation of the therapy while 12 (60%) reported recurrence. Similarly 5 (25%) patients in Clobetasol propionate group had no recurrence while 15 (75%) reported recurrence. Out of these 6 in Tacrolimus group and 7 in Clobetasol group developed recurrence within 15 days after discontinuation of the therapy. At the same time recurrence was seen in a mean time period of 36 days in Tacrolimus group while in Clobetasol group recurrence was seen in a mean time of 40.5 days (Graph 3).



Graph3: Bar diagram comparing recurrence in both drug groups.

DISCUSSION

OLP is an autoimmune disorder with relapses and remissions. Treatment is aimed primarily at reducing the length and severity of symptomatic outbreaks. Absence of control group was the major limitation of the study. But on ethical grounds especially in cases of atrophic and erosive lichen planus patients giving placebo for one month was not acceptable.

The age of the patients in present study varied from 18-66 yrs with an average of 40.3 years similar to other studies as 43.6 yrs and 45.53 by Thongprason *et al.* 2003 [7] and Corrocher *et al.* 2008 [8]. In contrast to

the present study the mean age was 50-60 years in many previous studies [9, 10, 11, 12 and 13]. In the present study, ratio of male to female was 1:1.8 while it was 1:1.2 to 1:3 showing female preponderance in all the studies.[4,8,9,14 & 15] .

We found lesions most commonly on buccal mucosa and vestibule similar to the previous studies by Carbone M 2003 [9] and Radfar L *et al.* 2008 [15]. Tongue was the second most common site in studies by Carbone M *et al.* 2009 [9] Laeijendecker 2006 [11] and Carbone M *et al.* 1999 [4], whereas in our study, attached gingival was found to be the second most common site. None of the patients had skin lesions in our study.

Hegarty AM *et al.* 2002 suggested that least potent topical steroid should be used for treatment of OLP, [16] contradictory to many other studies which suggest the use of most potent corticosteroid like Clobetasol propionate for treatment and to get faster relief [4, 8, 15, 17 and 18]. In a recent study 0.025% of Clobetasol is found to be equally effective in treatment of OLP when compared to 0.5% [9]. Other topical agents like Tacrolimus have also been used in cases resistant to topical steroids or cases in which corticosteroids is contraindicated and was found to be very effective. [19, 20-22]. Radfar L *et al.* 2008 found Tacrolimus (0.1%) to be as useful as Clobetasol (0.05%) in treatment of OLP [15] while we found 0.025% of clobetasol propionate also to be equally effective. Contradictory to the above, Corrocher G *et al.* 2008 found Tacrolimus 0.1% to be more effective than Clobetasol propionate 0.05% in treatment of OLP [19].

Topical Clobetasol propionate 0.05% showed no response in 4.4% cases of OLP in a study by Carbone M *et al.* 2003 whereas in our study all patients responded well to the treatment [10]. The usual treatment period with Clobetasol is 2 weeks. However, longer treatment periods have been proposed for refractory disease [8].

Corrocher G *et al.* 2008 reported no significant changes in biochemical measures after 4 weeks of treatment with Tacrolimus 0.1% and Clobetasol Propionate 0.5% [8]. Similarly, Vente C *et al.* 1999 reported 5 out of 6 cases with no systemic blood levels of Tacrolimus anytime during therapy but in one case blood levels of 9- 15µgm/l were noted with no signs of systemic side effects. They suggested that this might be due to extensive erosions and more frequent applications by the patient [19]. So, in the present study the biochemical measures of drugs in the blood was not done.

Initial burning sensation was noted by 3 patients of Tacrolimus group in our study similar to previous studies [11, 19] but it did not lead to discontinuation of treatment in any of the patients. Other side effects of Tacrolimus like intermittent headaches, taste disturbance and patchy pigmentation of the oral mucosa were not reported. Muzio LL *et al.* 2001 compared Clobetasol in three different preparations and noted no adverse effects. But 7 out of 10 cases developed pseudomembranous candidiasis. They suggested that this can be avoided by use of topical antifungals prophylactically [17].

Hegarty AM *et al.* 2002 who compared two steroid preparations, fluticasone propionate spray and betamethasone sodium phosphate mouth rinses in OLP patients reported side effects of steroids like nausea, swollen mouth, bad taste and odor, dry mouth, sore throat, red painful tongue and pseudomembranous candidiasis [16]. In a recent trial by Carbone M *et al.* and in our study also no adverse effects like moon face, hirsutism or gastralgia was present after two months of treatment with topical clobetasol propionate [9]. This might be due to the short period of the treatment, less potency of Clobetasol propionate and immunocompetent patients. However, Gonzalez Moles M and Scully C 2010 noted that HPA inhibition was substantial with aqueous Clobetasol propionate when used three times daily during initial treatment phase [23].

Recurrence of the lesions was common after discontinuation of the therapy in both the drug groups i.e. 60% in Tacrolimus group and 75% in Clobetasol propionate group. Corrocher G *et al.* 2008 also reported recurrence in their study 2 weeks after discontinuation of the therapy. They suggested that an abrupt discontinuation of topical corticosteroids may have resulted in some rebound effect in the Clobetasol group during the follow up period. This might be the reason of more recurrence in our study too [8]. More stable results can be obtained by tapering of the dose and using Ketoconazole and amitriptyline with clobetasol propionate [18].

Conrotto *et al.* 2006 also noted less stable results with more side effects in Clobetasol group when compared to cyclosporine for 2 months [24]. Recurrence is reported in all the studies. [11, 19, 21]. This shows that both Clobetasol and Tacrolimus have only a palliative effect rather than curative effect. As FDA has considered Tacrolimus to be not so safe a drug, Radfer L *et al.* 2008 suggested that Tacrolimus should be considered only in recalcitrant cases and should be substituted by other alternative agents after 6 weeks [15].

CONCLUSION

Both Clobetasol propionate and Tacrolimus helps in symptomatic treatment of OLP patients. Topical Clobetasol 0.025% is as effective as 0.1% topical Tacrolimus ointment. Tacrolimus 0.1% can be used in patients where Clobetasol propionate is contraindicated or if the patients are refractory to treatment by Clobetasol. Clobetasol propionate in concentrations of 0.025% is equally effective as 0.05%. Further research should be planned on larger sample with prolonged follow up to evaluate the long term effects of both the drugs. Alternative treatment modalities and newer drugs should be tried as recurrence is the most common problem of both the drugs.

REFERENCES

- [1] Rajendran R. Oral lichen planus. *J Oral Maxillofac Pathol* 2005; 9: 3-5
- [2] Eisen D, Carrozzo M, Sebastian JVB and K Thongprasom. Oral lichen planus: clinical features and management. *Oral Diseases* 2005; 11: 338–349
- [3] Rodstrom PO, Hakeberg M, Jontell M and Nordin P. Erosive oral lichen planus treated with Clobetasol propionate and triamcinolone acetonide in Orabase: A double-blind clinical trial; *Journal of dermatological treatment* 1994; 5 (1): 7-10.
- [4] Carbone M, Conrotto D, Carrozzo M, Broccoletti R, Gandolfo S and Scully C. Topical corticosteroids in association with miconazole and chlorhexidine in the long-term management of atrophic-erosive oral lichen planus: a placebo-controlled and comparative study between Clobetasol and fluocinonide. *Oral Dis* 1999; 5 (1): 44-9
- [5] Bhuvana K, Sarala N, Singh G and Kumar TN. Topical Tacrolimus: Pharmacological aspects. *Int J Biol Med Res* 2010; 1(4): 337-340.
- [6] Boyd AS and Neldner KH. Continuing Medical education: Lichen Planus. *J Am Acad Dermatol* 1991; 25(4): 593-619.
- [7] Thongprasom K, Luengvisut P, Wongwatanakij A and Boonjatturus C. Clinical evaluation in treatment of oral lichen planus with topical fluocinonide acetonide: a 2-year follow-up. *J Oral Pathol Med* 2003; 32 (6): 315-22.
- [8] Corrocher G, Di Lorenzo G, Martinelli N, Mansueto P, Biasi D, Nocini PF *et al.*. Comparative effect of Tacrolimus 0.1% ointment and Clobetasol 0.05% ointment in patients with Oral Lichen Planus. *Clin Periodontol* 2008; 35: 244-249.
- [9] Carbone M, Arduino PG, Carrozzo M, Caiazzo G, Broccoletti R, Conrotto D *et al.*. Topical Clobetasol in the treatment of atrophic erosive oral Lichen Planus: a randomized controlled trial to compare two preparations with different concentrations. *J of Oral Pathol Med* 2009; 38: 227-233
- [10] Carbone M, Goss E, Carrozzo M, Castellano S, Conrotto D, Broccoletti R *et al.*. Systemic and topical corticosteroid treatment of oral lichen planus: a comparative study with long-term follow-up. *J Oral Pathol Med* 2003; 32 (6): 323-9.
- [11] Laeijendecker R, Tank B, Sybren K and Neumann HAM. A Comparison of Treatment of Oral Lichen Planus with Topical Tacrolimus and Triamcinolone Acetonide Ointment. *Acta Derm Venereol* 2006; 86: 227–229.
- [12] Xia J, Li C, Hong Y, Yang L, Huang Y and Cheng B. Short-term clinical evaluation of intralesional triamcinolone acetonide injection for ulcerative oral lichen planus. *J Oral Pathol Med* 2006; 35 (6): 327-31.
- [13] Nolan A, Badminton J, Maguire J and Seymour RA. The efficacy of topical hyaluronic acid in the management of oral lichen planus. *J Oral Pathol Med* 2009; 38 (3): 299-303.
- [14] Gonzalez-Moles MA, Ruiz-Avila I, Rodriguez-Archilla A, Garcia PM, Aguado FM, Martinez AB *et al.*. Treatment of severe erosive gingival lesions by topical application of Clobetasol propionate in custom trays. *Oral Surg Oral Med Oral Pathol Oral Radiol Endod* 2003; 95: 688-92
- [15] Radfar L, Wild RC and Suresh L. A comparative treatment study of topical Tacrolimus and Clobetasol in Oral Lichen Planus. *Oral Surg Oral Med Oral Pathol Oral Radiol Endod* 2008; 105: 187-93

- [16] Hegarty AM, Hodgson TA, Lewsey JD and Porter SR. Fluticasone propionate spray and betamethasone sodium phosphate mouthrinse: a randomized crossover study for the treatment of symptomatic oral Lichen Planus. *J Am acad Dermatol* 2002; 47 (2): 271-279.
- [17] Muzio LL, Valle AD, Mignogna MD, Pannone G, Bucci P, Bucci E *et al.*. The treatment of oral aphthous ulceration or erosive Lichen planus with topical Clobetasol Propionate in three preparations: a clinical and pilot study on 54 patients. *J Oral Pathol Med* 2001; 30: 611-7.
- [18] Javadzadeh A, Vatanpour H, Delavarian Z, Momajed A, Esmaeily H, Vatanpour M *et al.*. Efficacy of Clobetasol, Ketoconazole and Amitryptiline Mouthwash on Oral Lichen Planus. *Iranian Journal of Pharmaceutical Research* 2008; 7 (3): 171-178.
- [19] Vente, Reich, Rupprecht and Neumann. Erosive mucosal lichen planus: response to topical treatment with Tacrolimus. *British Journal of Dermatology*; 140 (2); 338 – 342.
- [20] Lener EV, Brieva J, Schachter M, West LE, West DP and El-Azhary R. Successful Treatment of Erosive Lichen Planus with Topical Tacrolimus. *Arch Dermatol* 2001; 137; 419-422.
- [21] Oliver V, Lacour JP, Mousnier A, Garraffo R, Monteil RA and Ortonne JP. Treatment of chronic erosive Oral Lichen Planus with Low concentrations of Topical Tacrolimus. *Arch dermatol* 2002; 138: 1335-38.
- [22] Stoopler ET, Sollecito TP and DeRossi SS. Topical Tacrolimus for Treatment of Oral Lichen Planus. *The Internet J of Dermatology*; ISSN 1531-3018.
- [23] Gonzalez-Moles M and Scully C. HPA-suppressive effects of aqueous Clobetasol propionate in the treatment of patients with oral lichen planus. *J Eur Acad Dermatol Venereol* 2010; 10. (Epub ahead of print).
- [24] Conrotto D, Carbone M, Carrozzo M, Arduino P, Broccoletti R, Pentenero M *et al.*. Cyclosporin vs. Clobetasol in the topical management of atrophic and erosive oral lichen planus: a double-blind, randomized controlled trial. *Br J Dermatol*. 2006; 154 (1): 139-45.