

# Research Journal of Pharmaceutical, Biological and Chemical Sciences

## Hemangiomatous Ameloblastoma: A Dilemma on Its Occurrence: A Rare Case.

Chatterjee Ananjan<sup>1</sup>, Pillai Arun Gopinathan<sup>2\*</sup>, Priya Shree<sup>3</sup>, and Madhuresh Kumar<sup>4</sup>.

<sup>1</sup>Senior Lecturer, Oral & Maxillofacial Pathology, Buddha Institute of Dental Sciences, Patna-20, India.

<sup>2</sup>Senior Lecturer, Oral & Maxillofacial Pathology, Sri Sankara Dental College, Varkala, Akathamuri, Kerala, India.

<sup>3</sup>Post Graduate, Oral & Maxillofacial Pathology, Buddha Institute of Dental Sciences and Research, Patna-20.

<sup>4</sup>Senior Lecturer, Department of Oral and Maxillofacial Pathology, Buddha Institute of Dental Sciences and Research, Patna-20.

### ABSTRACT

Hemangiomatous Ameloblastoma is a rare benign neoplasm while considering the histopathological diversity. In this report we describe a 35 year old male patient with a swelling in the left mandibular region showing various clinical and radiographical features. This article clearly depicts the distinct variation in the histopathologic pattern and also emphasizes the occurrence and pathogenesis of the rare lesion which might lead to surgical complications.

**Keywords:** Ameloblastoma, Hemangioma, Hemangiomatous Ameloblastoma.

*\*Corresponding author*

## INTRODUCTION

Earlier in 1885 this tumour was designated as an Adamantinoma by Malassez but was renamed to Ameloblastoma in the year 1930 by Ivey and Churchill.[1] Ameloblastoma is the most common odontogenic neoplasm [2,3] and was first described by Falkson in 1879, and since then, a number of cases have been reported with various histopathologic variations.[2] Earlier found to be second most common odontogenic tumor ,after odontoma but a study conducted by G. Sriram and Shetty RP in an Indian Institution reveals ameloblastoma to be most common (61.5%) odontogenic neoplasm in India.[3]

In the literature, a rare variant called hemangiomatous ameloblastoma (HA) was originally described as an ameloblastoma. The origin of the vascular component of the HA is not completely resolved, and both the histologic and radiologic features differ from those of the accepted types of ameloblastomas.[4] This article presents the clinical, radiological and histopathological features and a discussion on its occurrence and its clinical behaviour.

## CASE REPORT

A male patient aged 35 years reported in our Oral and Maxillofacial Pathology Unit with a swelling in his lower left back tooth region since past 2 years. Patient presented with the history of trauma followed by swelling which started as small size and gradually increased to attain the present size with no associated pain. There was no history of any systemic illness. Past dental history and personal history was found to be not significant. Extraoral examination revealed a diffuse swelling in left body of mandible measuring about 2 x 2.5 cms extending from the body till the angle of the mandible (Figure1). The swelling was hard in consistency with no tenderness. Skin over swelling was normal with no local rise in temperature.

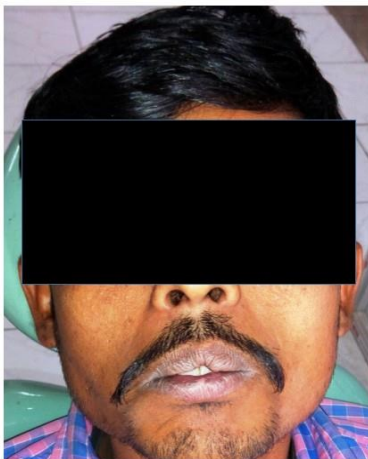

Figure 1

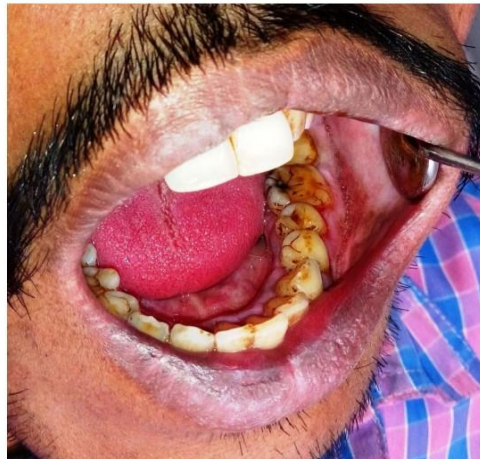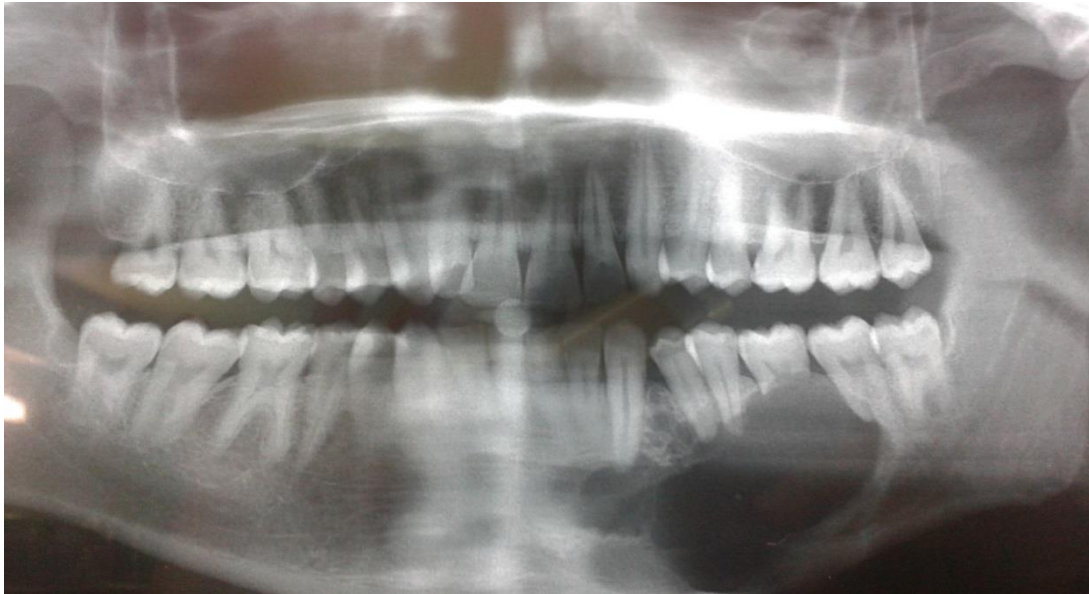


Figure 2

**Figure1: Extra oral swelling seen on the left body of the mandible.**

**Figure 2: Intra oral swelling with buccal & lingual expansion of the cortical bone.**

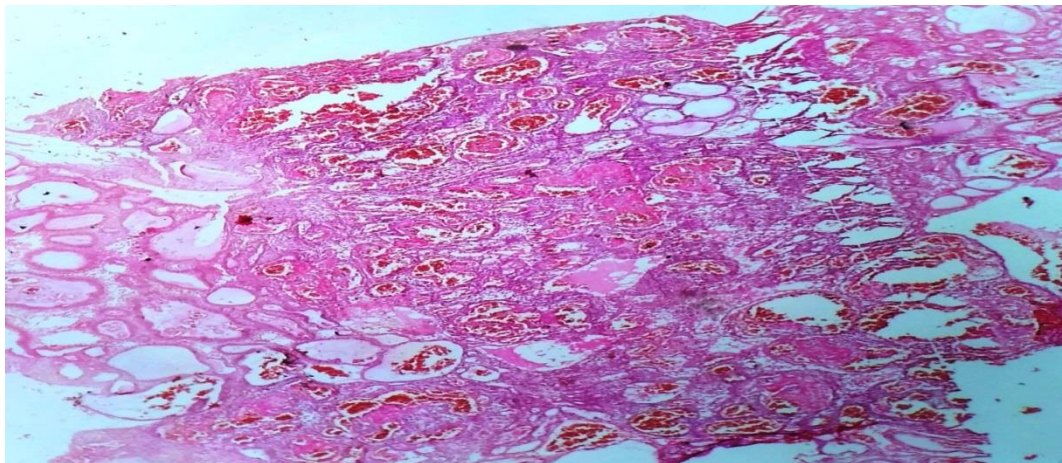
Intraoral examination revealed that the swelling was measuring around 2.5 x 2cm, extending antero-posteriorly from distal part of 1<sup>st</sup> premolar till retromolar region with expansion of buccal and lingual cortex, the extent of swelling was confirmed on palpation (Figure 2). Swelling was hard in consistency. Mucosa over the swelling was normal. No tenderness on palpation .OPG revealed a well defined unilocular radiolucency extending from the apical region of 33 till the mesial aspect of 37 and also extending towards the lower border of the mandible. Root resorption was noted in respect to 34,35,36,37 (Figure 3).



**Figure 3 :Orthopantomograph revealed a unilocular radiolucency extending from the apex of 34 to the mesial aspect of 37 and also root resorption was noted in respect to involved teeth.**

Radiological Differential Diagnosis of Central Hemangioma, Ameloblastoma and Central Giant Cell Granuloma, Odontogenic Keratocyst were made. A Provisional Diagnosis of Ameloblastoma and Clinical Differential Diagnosis of Central Giant Cell Granuloma, Odontogenic Keratocyst were made. Enucleation was carried out and multiple bits were sent for histopathological examination.

Microscopic examination of hematoxylin & eosin stained section revealed large cystic spaces of varying shapes and sizes and each cystic spaces are lined by odontogenic epithelium (Figure 4).



**Figure 4 : Photomicrograph shows numerous cyst like spaces of varying shapes and sizes with vascularity. (Hematoxylin & Eosin stain, 40x).**

The odontogenic epithelium consists of peripherally placed tall columnar ameloblast like cells and centrally placed stellate reticulum like cells (Figure 5). The odontogenic epithelium is arranged in anastomosing cords arranged in a back to back pattern giving a plexiform type of arrangement. A vascular component was also predominant in the connective tissue stroma consisting of numerous blood filled endothelial lined blood vessels of varying shapes and sizes. Focal areas showed compressed odontogenic epithelial component by large blood vessels (Figure 6). Considering the features a diagnosis of Hemangiomatous Ameloblastoma was made.



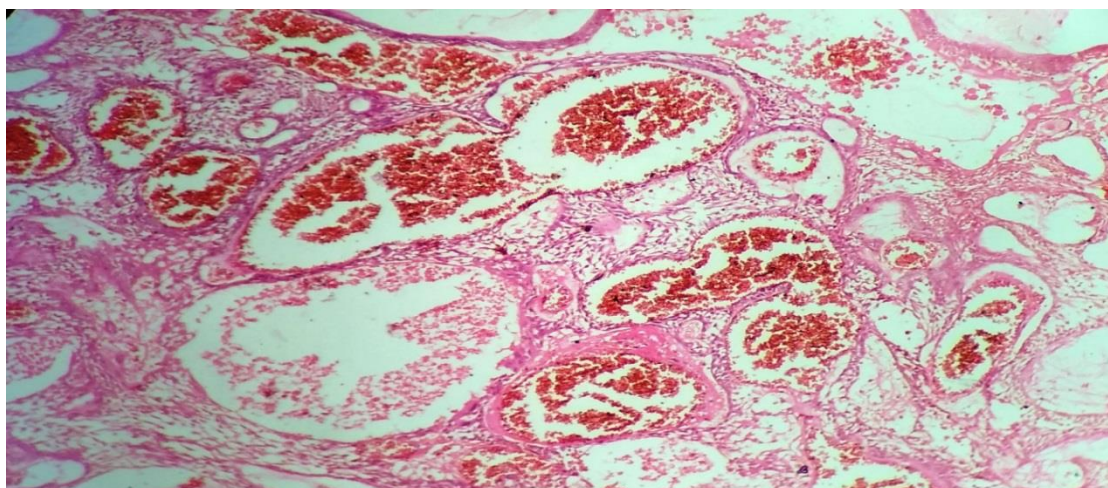


Figure 5. Photomicrograph shows large blood filled areas along with coexistence of odontogenic epithelium. (Hematoxylin & Eosin stain, 200x).

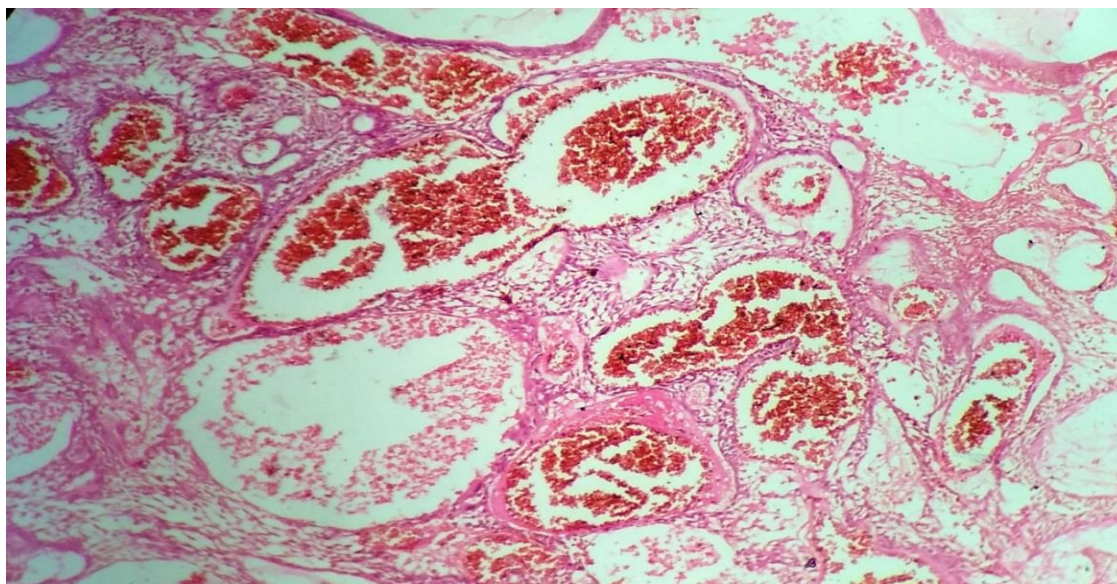


Figure 6. Photomicrograph shows odontogenic epithelium in a back to back arrangement, focal areas showing blood vessels compressing the odontogenic epithelium. (Hematoxylin & Eosin stain, 400x).

#### DISCUSSION

Ameloblastoma is one of the most common odontogenic tumour and comprises of 11% of all of them.[2,3] Ameloblastoma can be classified based on clinico-radiological features into three types: solid or multicystic, unicystic, and peripheral type.[5] Odontogenesis is a complex process and any alteration from normal process results in odontogenic neoplasms. In ameloblastoma there is faulty differentiation of enamel organ to the point of enamel formation. [6,7] Histopathological variants of ameloblastoma have been described in the literature which are follicular (most common), plexiform, acanthomatous, granular (most aggressive), basal cell and desmoplastic. [7]

Among all the variants follicular and plexiform ameloblastoma is said to be the common types. Reports of variants like clear cell, papilliferous, keratoameloblastoma and a very rare pattern HA have also been described. Studies have shown that all the mentioned histological variants do not differ significantly in either biological behaviour of the tumour or its prognosis after treatment. Desmoplastic and HA are exceptions with the former thought to be less aggressive and the later due to its extreme vascular component cause surgical complications.[6,7,8]

HA is a solid multicystic ameloblastoma (SMA) in which a part of the tumor contains spaces filled with blood or large endothelial-lined capillaries, first described by Kuhn in 1932. Van Rensburg et al also reported a case of this rare tumor variant in a 26-year old woman who had a gradually enlarging symptomatic swelling in the posterior region of the left mandible which was later diagnosed as HA. [6,9]

The origin of the vascular component of the HA is still debatable and several theories have been postulated; among them are excessive stimulation of angiogenesis during tumor development and trauma such as tooth extraction. It has further been suggested that the HA represents a collision tumor. Whether the vascular component of the HA is part of the neoplastic process? or whether it represents a separate neoplasm, or is a hamartomatous malformation remains to be explored. Lucas believed that the unusual vascularity is not due to a neoplastic process. According to Lucas, there is an entire absence of vasoformative activity. In the process of formation of stromal cysts in the ordinary type of plexiform ameloblastoma, the blood vessels often persist and dilate instead of disappearing; thus, it is likely to represent a purely secondary change. [4,6,7,9]

The probable theories proposed to explain the pathogenesis of the vascular component of hemangiomatous ameloblastoma are:

#### **EXCESSIVE ANGIOGENESIS DURING TUMOUR DEVELOPMENT.**

During amelogenesis, capillaries associated with the outer enamel epithelium provide the profuse blood supply necessary for enamel completion. Aisenberg MS in 1950 stated that in the HA, there is abnormal proliferation of blood vessels and they probably become part of the tumor. Another school of thought also postulated that excessive stimulation of angiogenesis during tumor development by inductive influences such as those that occur during odontogenesis or by other factors may result in the overgrowth of vascular elements in the odontogenic ectomesenchyme or in adjacent connective tissue. [4,7,9]

#### **SECONDARY CHANGES**

Lucas, viewed that vascular component of hemangiomatous ameloblastoma was purely a secondary change. According to him cystic degeneration occurs in stroma in plexiform ameloblastoma, and during the cysts formation some blood vessels instead of diminishing may persist and dilate resulting in vascular component as seen in hemangiomatous ameloblastoma. [6,8]

#### **TRAUMA**

Numerous researches propose that, a traumatic incident such as a tooth extraction may provoke excessive proliferation of epithelial cell rests of Malassez, in the periodontal ligament which might lead to tumor formation. Tissue damage is repaired involving the formation of granulation tissue in which proliferating endothelial cells and new capillaries are prominent. [4,7,9]

Various authors supported this thought stating that, a disturbance in the repair of neoplastic odontogenic tissue may result in excessive granulation tissue formation or the development of an abnormal vascular component. [6,7,9]

#### **COLLISION TUMOUR**

Another school of thought is that two separate tumors grow in the same area and collide, and the tumor elements get intermingled. Thus they named it as "Collision Tumor". [7] Smith et al regarded that the HA is histologically similar to one of the other recognized types of ameloblastoma and not as a distinct histologic entity. He thought the blood supply to these tumors was variable and that circumstances other than the number and size of the vessels influenced the blood supply. [10] Whether the vascular component of the HA is part of the neoplastic process, represents a separate neoplasm, or is a hamartomatous malformation has not been satisfactorily resolved. [7,9,11]

The histopathological variant of ameloblastoma (HA) has been very rarely reported in literature and radiographically it resembles a unilocular well defined radiolucency which is not seen in conventional SMA. Hence we can say that HA radiographically resembles unicystic type while histopathologically resembles

plexiform type with prominent vascular component. The biologic behaviour of this tumour is thought to be similar to the conventional type of ameloblastoma but due to lack of cases reported in literature the proper etiopathogenesis, clinical course and its recurrence potential is not clearly understood.

### CONCLUSION

The reported case was clinically symptomatic, radiographically mimicked ameloblastoma but based on the histopathological findings a diagnosis of Hemangiomatous Ameloblastoma was made. Thus due to limitation of number of cases it is difficult to confirm a diagnosis based on clinical & radiological finding alone. This article clearly depicts the distinct variation in the histopathologic pattern of ameloblastoma. Finally it is crucial that the radiologists, surgeons and pathologists should assimilate all the relevant information and come up with an accurate diagnosis for appropriate management.

### REFERENCES

- [1] Suk Keun Lee, Yeon Sook Kim; Current Concepts and Occurrence of Epithelial Odontogenic Tumors: I. Ameloblastoma and Adenomatoid Odontogenic Tumor; The Korean J Pathol 2013 Jun ; 47(3) : 191-202
- [2] Cawson RA, Odell EW, Porter S. Cawson's Essentials of Oral Pathology and Oral Medicine, 7<sup>th</sup> ed. Spain ;Elsevier, 2003 p 121-22
- [3] Shafer W.G, Hine M.K, Levy B.M. Text book of Oral pathology 4<sup>th</sup> ed. Philadelphia: W.B.Saunders Company;1997.p143-60
- [4] Swapnil Santosh Deore, Aarti M. Mahajan, Pradeep G L, Vishakha Chaudhari. Plexiform Hemangiomas of Ameloblastoma: An Uncommon Variant Of Ameloblastoma; Indian Journal of Dental Sciences 2016 Mar ;1(8): 76-79
- [5] Neville B.M, Damm D.D, Allen C.M, Bouquot J.E. Oral and Maxillofacial Pathology. 2<sup>nd</sup> ed; New Delhi: Elsevier; 2002.p. 356-70.
- [6] Reichert P.A, Philipsen H.P. Odontogenic Tumours and Allied Lesions 1<sup>st</sup> ed; London: Quintessence Publishing Co Ltd; 2004.p.43-67
- [7] Maruthi Devi Kasangari, Kiran Gundamaraju, Mandapati Jyothsna, Andy Venkata Subash, Kumbakonam Aravind . Hemangiomatous Ameloblastoma- A Case Report of a Very Rare Variant of Ameloblastoma. J Clin Diagn Res; 2015 May; 9(5):8-10
- [8] Adisa AO, Lawal AO, Olusanya AA, Arotiba JT. Hemangiomatous ameloblastoma: report of a case. Nig Dent J 2010 July – Dec;18(2): 73-75
- [9] Jois HS, Mohan Kumar KP, Mandali SK, Waghrey S; A mixed neoplasm of intraosseous Hemangioma with an Ameloblastoma: a case of collision tumor or a rare variant? Clin Pract. 2012 Jan 1; 2(1): e5
- [10] Smith JF. The controversial ameloblastoma. Oral Surg Oral Med Oral Pathol; 1968 Jul;26(1):45-75.
- [11] Avinash P. Tamgadge, Dharendra G. Sirur, Sudhir S. Bhalerao , Treville Pariera , Sandhya A. Tamgadge ; Hemangiomatous Ameloblastoma: A Case Report of a Rare Variant of Ameloblastoma; IJCD • 2010; Nov;1(2):16-19.