

Research Journal of Pharmaceutical, Biological and Chemical Sciences

Posteroanterior Cephalometric Analysis: Method of Assessment of Craniofacial and Dental Changes in Subjects with Crossbite.

Lidija Kanurkova*¹, Gabriela Kjurchieva Chuchova², Cvetanka Bajrektorova Misevska³, Aleksandra Dorakovska⁴, Marija Maneva⁵, and Ana Sotirovska Ivkovska⁶.

¹Professor, Department of Orthodontics, Faculty of Dentistry Skopje, Macedonia;

²Assoc. professor, Department of Orthodontics, Faculty of Dentistry Skopje, Macedonia;

³Assoc. professor, Department of Orthodontics, Faculty of Dentistry Skopje, Macedonia;

⁴Orthodontist, Private Specialist Dental Office of Orthodontics, Skopje, Macedonia;

⁵Assistant, Orthodontist, Department of Orthodontics, Faculty of Dentistry, Skopje, Macedonia;

⁶ Professor, Department of Pediatric and Preventive Dentistry, Faculty of Dentistry Skopje, Macedonia;

ABSTRACT

The fact, that the degree of malocclusion increases with the facial growth, suggests the early diagnosis and treatment will facilitate establishment of functional and aesthetic individual optimum. The aim of this study was to describe dental arch dimensions, facial maxillary and mandibular skeletal structures; type of crossbite and to determine the occlusal plane tilt in subjects with transversal malocclusion with crossbite on the right side. The study group consisted of 120 patients of both gender with equal distribution, from the Department of Orthodontics, Faculty of Dentistry, Skopje previously not orthodontically treated; 60 had unilateral posterior crossbite on the right side, and 60 subjects had normal occlusion. The age of the patients ranged between 13 and 18 years. Cephalometrics postero-anterior Ricketts analysis determine facial, maxillary, mandibular and dental width, angle which illustrates the type of crossbite, asymmetry degree, occlusal plane tilt. Cephalometrics measurements showed that the patients with posterior crossbite had constriction on the corpus maxillae with skeletal, lingual crossbite, 28 patients had diverging on the occlusal plane with TMJ disorders. Cephalometrics measurements showed that the patients with transversal disharmony had lingual crossbite with oral inclination of maxillary buccal teeth, and diverging on the occlusal plane.

Keywords: Cephalometrics postero-anterior analysis, crossbite, asymmetry, TMJ disorders

**Corresponding author*

INTRODUCTION

Growth and development of orofacial region is a dynamic and complex process and its intensity varies in different periods of life, resulting in skeletal and soft tissues changes that form and create the occlusion. The parallel processes of apposition and resorption of the bone tissue together with its remodeling and differential growth of the soft tissues lead to significant changes in the area of face and cranium in the postnatal period. Thus, the face of an adult differs a lot from the face of a newborn, the harmonic growth of this system ensures the correct relation between the jaws, right position of the teeth in dental arches, balanced facial relations, together with good functional occlusion and aesthetics.

Facial asymmetry occurs when the central line of the face is not straight and each side of the face looks different [1]. It can involve the jaw line and other features of the face differing. Usually, the condition is not noticeable, though it depends on the degree of asymmetry. Facial asymmetry is most commonly influenced by jaw problems and their abnormal growth [2]. The external appearance of the patient depends of the constitutional composition of its skeleton, position of the facial bones in relation to the cranial base; the relation between upper and lower jaw; the manner of their intercuspitation, the thickness of the soft tissue which overlies the face skeleton, and the dimension of nose, lips and the chin, as well [3].

Solow and Tallgren [4], and Posnick [5], showed that statistical correlations exist between the predominant mode of respiration, head posture, and some facial features. Because of impaired breath function, a narrow irregularly developed palate in the early childhood may be formed. Linder-Aronson's [6] research indicates that tongue has formative influence to the development of palate and maxillary dental arch. He emphasizes that number of factors has influence to the development of the face and dental arches, and that it is difficult to define if the genetic factor, presence of bad habits, impaired breath function or other exogenous factor may be more dominant. The placement of the maxillary teeth in the alveolar processes depends primarily on width and configuration of the hard palate. If such a narrow palate in the early childhood is formed, and without proper orthodontics treatment, it will keep that configuration during whole life [7]. The maxillary dental arch in these patients will be compressed palatally, resulting in forming narrow maxillary dental arch, with not enough space for positioning the teeth. Their spot in the dental arch will be closer to raphe palatine mediana, which will lead to occurrence of dental asymmetry and formation of cross-bite in the posterior region.

Cross-bites are transversal occlusal abnormalities in bucco-oral direction, in which mandibular posterior teeth overlap the maxillary teeth in the buccal side, or a particular group of teeth in the posterior region does not occlude with antagonists. This malocclusion has plenty of symptoms and it occurs in the primary dentition and continues in the mixed and permanent dentition. If it is left untreated this malocclusion leads to skeletal deformation.

Depending on the localization, crossbite may be formed as: unilateral crossbite, localized only at one side in the dental arch and bilateral crossbite, localized in both sides in the dental arch. The upper jaw is usually symmetrically narrow, with the lower jaw being with normal dimension, or wider than the upper jaw. It can be demonstrated with few variations of its expression: locally crossing of some teeth in the posterior region; crossing of a group of teeth or whole posterior side of the teeth. There are four levels of crossbite. It can vary from cusp-to-cusp position, to total buccal or lingual absence of contact. Every level of crossbite may be present in patients with malocclusion class I, II, or class III [8].

The occlusal contact pattern of the teeth also influences stability of the masticatory system. It is important that when the condyles are in their most stable position in the fossae and the mouth is closed, the teeth occlude in their most stable relationship. The inappropriate intercuspitation of the teeth leads to changes in the direction of the occlusal forces, causing a stress on the periodontal membrane and alveolar bone of the affected tooth, which induces occurring of traumatic occlusion and periodontal disease predisposition. As a result of irregular intercuspitation of posterior teeth in bucco-oral direction, a disruption in the function of mastication occurs. On the side of mastication, a face musculature hypertrophy occurs, whereas the development of the opposite side of the face is getting slower, which can result in hypotrophy. The face does not meet the normal biometric average dimension, so a face asymmetry is present [9].

Figure 2. presenting cranial width (Zr-Zl), is a distance between lateral left and right zygomatico-frontale landmarks; facial width (ZA-AZ), distance of the left and right zygion point on the zygomatic arch;maxillary width (Jl-Jr), distance between point jugale located on the corpus maxillae; mandibular width (AGor-AGol), distance between bigonial point. dental arch width; intercanine maxillary cephalometric width (A3-3A); intercanine mandibular cephalometric width (B3-3B); intermolar maxillary cephalometric width (A6-6A); intermolar mandibular width (B6-6B); molar relation A6/B6, on the left side and molar relation on the right side 6A/6B.

The vertical reference plane showing the facial midline is between point spina nasalis anterior – menton (SNA-Me). This measurement presents maxillo-mandibular midline and it is constructed as a straight line passing through crista galli and anterior spine nasalis anterior (Figure 2), perpendicular to a straight line between the intersections of the innominate line of the greater wing of the sphenoid bone and the lateral orbital margins [1].

Craniofacial angle which presenting type of the crossbite type, is the angle between points zygomatico-frontale–antegonion–jugale <Zr-Agor-Jr, <Zl-Agol-Jl, and this angle illustrates the maxillo-mandibular relation. Facial symmetry is shown with the left and right angle of the face, between point zygion-antegonion-zygomatico-frontale, <ZA-Agor-Zr, <AZ-Agol-Zl (figure3).

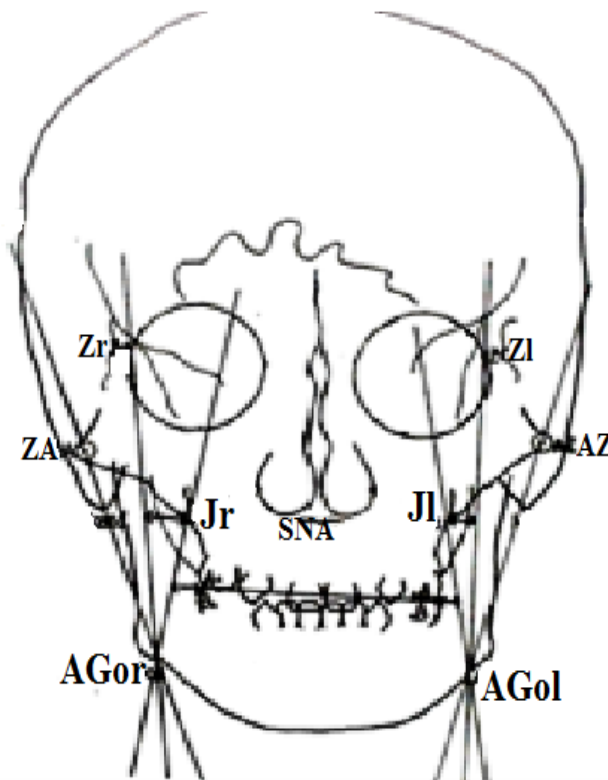


Figure 3. Cephalometrics craniofacial angular measurements used in postero- anterior Ricketts analysis

The angle <Zr-Agor-Jr, <Zl-Agol-Jl between points zygomatico-frontale–antegonion–jugale, presenting maxillo-mandibular relation.

On frontal cephalometric radiographs the occlusal plane tilt is defined as a difference between the height of the occlusal plane at the distal side on the left and right molars to the line which connects zygomatico-frontal sutures (Zl-A6/ Zr-A6). This variable represents inclination of the frontal occlusal plane relation (figure 4) which is usually connected with possibility for TMJ disorders [10].

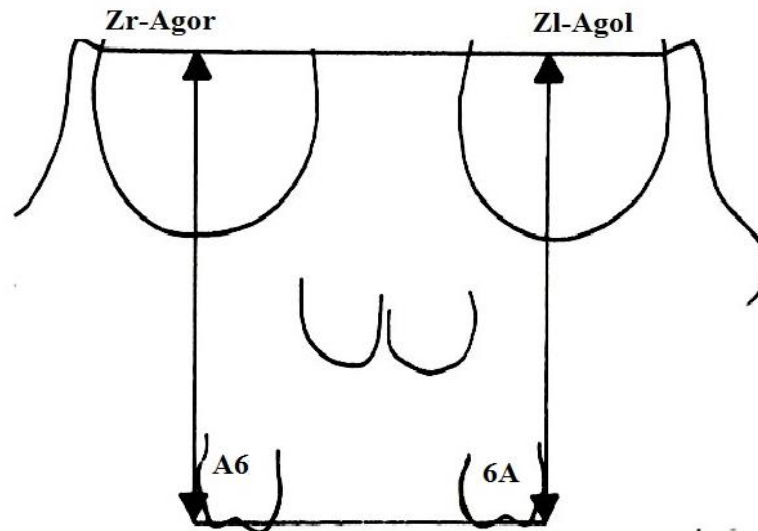


Figure 4. Vertical linear cephalometrics measurements presenting inclination of occlusal plane

Symmetry in maxillo-mandibular region and type of the facial asymmetry is measured with linear cephalometrics [1] difference between point zygomatico-frontale and antegonion on the left and right side, (Zl-Agol), (Zr-Agor). This variables presents position of condyle and its maxillo-mandibular relation (Zl-Agol), (Zr-Agor), (figure 5).

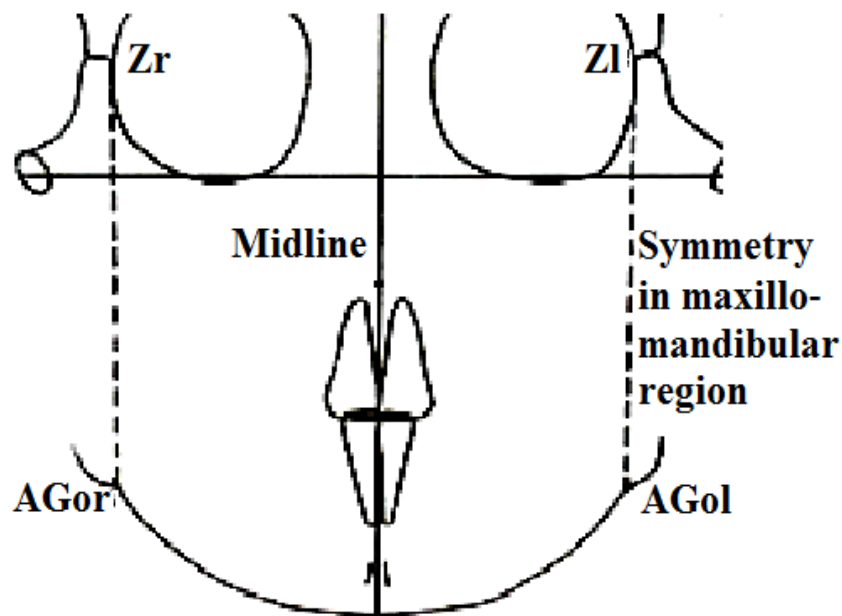


Figure 5. Ricketts analysis presenting facial symmetry with linear cephalometrics measurements

Results from our findings were analyzed with Statistical SPSS 7.0; Student's t-test. Student's t-test was used to determine statistical significance between the two groups, patients with posterior crossbite and patients with normal occlusion. The level of significance was set at p-values of $p < 0.05$.

RESULTS

Roentgenograms, such as the postero-anterior view and submental vertex, three-dimensional image of the patients face, and computerized tomographic images are important methods for diagnosis and quantification of asymmetries [11-12].

Transversal clinical observation was complemented by facial postero-anterior cephalometrics radiography analysis, according to Ricketts method [1]. In this study postero-anterior cephalometrics measurements showed that the patients with unilateral crossbite in the right side had constriction on the corpus maxillae, asymmetrical configuration of the upper jaw in the level of the point jugale, improperly developed lower jaw in the point antegonion. This finding was usually reported in similar investigative studies which are also confirmed by our results [10 -13]. Distance between right and left skeletal point jugale (Jr-Jl) on the corpus maxillae showed lower values 68.75 mm in the patients with unilateral cross bite on the right side compared with the values 71.1 mm of the patients with normal occlusion which present control group. For this variable t-test show a high statistical significance ($p < 0.01$). Patients with a crossbite had constriction on the corpus maxillae in the level of the point Jugale (table 1). High statistical significance for the distance between right point jugale to the middle median plane Jr-Midline was found, as well, which indicates that there is a compression of corpus maxillae on the right side of the face in the area of point jugale.

Table 1. Linear facial cephalometrics measurements (mm) in the patients with crossbite on the right side

Cranial and facial linear cephalometrics measurements Ricketts P-A analysis	Patients with unilateral crossbite on the right side n=60		Patients with normal occlusion n= 60		" t "	p
	Mean	SD	Mean	SD		
Zr - Zl	101.65	4.32	102.21	6.3	0.57	0.571
Zr-Midline	50.72	2.82	50.95	3.4	0.40	0.687
Zl- Midline	50.89	1.95	51.25	3.17	0.75	0.455
ZA - AZ	128.65	5.35	131.1	8.4	1.91	0.059
ZA- Midline	64.31	3.79	65.62	4.5	1.72	0.087
AZ- Midline	65.75	3.21	66.37	5.4	0.76	0.446
Jr - Jl	68.75	3.63	71.1	4.4	3.19	0.0018**
Jl- Midline	34.79	2.21	36.2	2.4	3.348	0.0011**
Jr- Midline	33.79	1.98	35.13	2.5	3.25	0.0015**
Agor - Agol	87.54	3.39	88.89	6.1	1.49	0.137
Agor-Midline	43.45	2.32	44.8	3.7	2.39	0.018*
Agol- Midline	43.51	2.04	44.4	3.7	1.63	0.112

$p < 0.05$ * low statistical significance, $p < 0.01$ **high statistical significance, $p < 0.001$ ***very high statistical significance

Table 2. Linear dental cephalometrics measurements (mm) in the patients with crossbite on the right side

Dental linear cephalometrics measurements Ricketts P-A analysis	Patients with unilateral crossbite on the right side n=60		Patients with normal occlusion n= 60		"t "	p
	Mean	SD	Mean	SD		
A3 - 3A	32.14	2.4	35.1	2.7	6.35	0.001***
A3-Midline	16.37	1.8	17.4	1.8	3.13	0.0022**
3A-Midline	16.53	1.6	17.1	1.6	1.95	0.053
B3 - 3B	28.4	1.8	29.1	2.6	1.71	0.089
B3-Midline	13.65	1.6	14.2	2.2	1.56	0.120
3B- Midline	14.51	1.7	14.5	1.5	0.03	0.973
A6 - 6A	59.93	3.6	64.5	5.9	5.12	0.001***
A6- Midline	29.72	2.2	32.1	3.2	4.75	0.001***
6A- Midline	30.77	2.2	31.7	3.4	1.78	0.078
B6 - 6B	61.73	3.5	62.5	5.7	0.89	0.374
B6- Midline	31.17	2.0	31.1	3.0	0.15	0.880
6B- Midline	30.29	2.4	31.1	3.3	1.54	0.127
A6 / B6	+2.31	0.8	0.9	0.5	11.58	0.001***
6A / 6B	0.92	1.1	1.1	0.5	0.89	0.372

$p < 0.05$ * low statistical significance, $p < 0.01$ **high statistical significance, $p < 0.001$ ***very high statistical significance

The dental cephalometrics parameters showed asymmetric occlusion, dental asymmetry in the level of canine and molar relation, midline discrepancies, narrow maxillary dental arch in the level of canine and molars, and a palatal inclination of the maxillary posterior teeth was diagnosed (table 2).

Cephalometric angular measurements between point zygomatico-frontale, antegonion and jugale <Z-Ago-J, which determines the type and degree of crossbite in the patients with unilateral crossbite had a large value of 19.7 degree. These values compared with control group 14.5° showed very high statistical significant difference $p < 0.001$. This fact indicates that the patients with crossbite of the right side had skeletal lingual crossbite (table 3).

Table 3. Angular cephalometrics measurements used in Ricketts P-A analysis

Cephalometric angular measurements	Patients with unilateral crossbite in the right side n = 60		Patients with normal occlusion n= 60		" t "	p
	Mean	SD	Mean	SD		
<ZA-Agor-Zr angle of symmetry on the right side	14.31°	1.96	13.7°	2.4	1.52	0.130
<AZ-Agol-Zl angle of symmetry on the left side	14.14	1.95	14.4	1.8	0.76	0.449
<Zr-Agor-Jr angle of crossbite on the right side	19.7°	1.52	14.5°	1.8	17.09	0.001***
<Zl-Agol-Jl angle of crossbite on the left side	15.5	1.97	14.9	1.7	1.79	0.077

$p < 0,05$ * low statistical significance, $p < 0,01$ **high statistical significance, $p < 0, 001$ ***very high statistical significance

Fronto-facial plane, which is the distance between the point's zygomatico-frontale and antegonion (Z-Ago), determines the symmetry of the face in the level of maxillo-mandibular structures i.e. symmetry of the face in the vertical direction. This distance should be with the same values on both sides of the face. In our study 28 patients with a unilateral crossbite in the right side, had asymmetry in the vertical direction which confirms the fact that skeletal changes occurred in the orofacial region.

Occlusal plane tilt was measured as a distance between the points obtained by line perpendicular on the distal area of the first maxillary molars to the occlusal plane. This line was not parallel to zygomatico-frontal plane, which indicates that among 28 patients despite formation of dental asymmetry, skeletal changes in this area were formed as well. This finding was usually reported in similar investigative studies which are also confirmed by our results. While in the 32 patients inclination of the occlusal plane regarding to the mandibular plane Agol-Agor has occurred, which indicates to the fact that, they had a dental crossbite (table 4).

Table 4. Cephalometrics measurements (mm) for condylar position and inclination of occlusal plane at patients with crossbite

Cephalometrics linear measurements	Patients with unilateral crossbite in the right side n = 28		Patients with normal occlusion n= 60		"t"	p
	Mean	SD	Mean	SD		
Zr-Agor	93.85	5.58	101.5	5.6	8.16	0.001***
Zl - Agol	97.92	6.59	101.4	8.6	2,5	0.014*
Zr – A6	74.67	4.39	76.5	6.4	1.83	0.070
Zl – 6A	76.29	5.41	76.7	6.6	0.37	0.711

$p < 0,05$ * low statistical significance, $p < 0,01$ **high statistical significance, $p < 0, 001$ ***very high statistical significance

DISCUSSION

Crossbite are malocclusions with a wide range of symptomatology, leading to dental arch deformities and tooth malposition, causing skeletal alterations of the orofacial region, temporomandibular joint disorders and facial asymmetry. Some studies described [14-17] that a result of irregular growth and development of this region, changes that may determine forming dentofacial malformations where the deviation from the normal is so remarkable that it can give the reflection of the patient face appearance, occlusion and articulation, may occur.

In the studies of Moyers [18] crossbites and facial asymmetries are classified as: dental, muscular, skeletal and combined. Dental crossbite is formed as a result of the early loss of deciduous teeth, incorrect eruption of permanent teeth due to insufficient space in the dental arch, or improper placement of tooth germ, incorrect labio-lingual or mesio-distal axial inclination of teeth. Early extraction of permanent teeth results in inclination or rotation of the adjacent teeth to the empty space, and the occurrence of dental asymmetry [19].

In patients with posterior crossbite and midline deviation orthodontic treatment is necessary to rehabilitate the asymmetric muscular activity between the crossbite and the other side and the changed position of the condyle caused by mandibular deviation.

Muscle type of crossbite occurs as a result of the adjustment of orofacial muscle to the early contact of certain teeth early contact of teeth results in lateral deviation of the mandible, where it is placed in adaptable compensatory position, and it is dislocated to one or another side of the face, determining distortion of the harmony of patient's face. This type of crossbite is also called forced crossbite and the early contact is usually in the region of canine. The lower jaw is placed diagonally regarding the upper, since the mandible moves in the transverse and sagittal direction.

Both capitulum of the mandible move asymmetrically [20]. One moves distally up, and the other on the balance side, down and mesially. In this type of asymmetric occlusion, buccal occlusion of one side of the dental arch and on the opposite, lingual occlusion is formed.

Continuous, traumatic occlusion and improper movement of the condyle of the mandible on the articular tissue and articular capsule, after a period causes sensory response, which leads to pain of varying intensity, which spreads to neighboring regions. An increased muscle tone in stomatognathic system occurs, sometimes demonstrating trismus, followed by limited movements of the mandible or a subluxation of TMJ. If the cause which determines distortion in function of the joint is not removed, first adaptive changes occur, then degenerative changes follow [16]. Joints will be exposed to progressive changes, abrasion of the disc, thinning of cartilage and bone changes. As a result of improper adaptation of the joint there are pathological changes, occurrence of subluxation and slackness of joints, mostly on the opposite side of the cross-bite and for that reason it comes to the formation of laterognathia. The laterognathia can be true or forced.

The true laterognathia occurs due to the existence of asymmetry of any part of the masticatory system: irregular growth of the ramus mandibulae, asymmetric morphology of the temporomandibular joint, misalignment of transversal and vertical growth of the craniofacial structures. In these laterognathias, inclination of the occlusal plane in relation to the cranial base occurs, despite the morphological disorders in the orofacial system, it comes to functional deviations as well [21].

Sometimes, these laterognathias have high degree of expression, so orthodontic treatment is difficult [22], or they are the main cause for the occurrence of relapses of these anomalies. In patients with laterognathia, they have facial asymmetry: the position and appearance of the lips, the curvature of the nose, and the chin deviation [23].

Skeletal crossbites are formed due to apically tight developed upper jaw or undeveloped jaws in the area of teeth roots [18]. Because of this, radicular constriction is formed, which is the reason for the emergence of gnathic compression. The palate in this type of crossbite is insufficiently developed and there is skeletal deficiency due to which the teeth are placed palatally. In some patients they are inclined buccally, to

establish contact with the mandibular teeth, so that it comes to dental partial compensation and occurrence of crossbite teeth [24].

Posterior crossbites have six possible explanations: (1) The upper arch is too narrow, (2) the lower arch is too wide, (3) a lateral functional shift occurs during closure of the mandible with premature tooth contacts deflect the mandible laterally during closure and the upper and lower arch widths are normal, (4) one or more teeth are displaced toward the palate in the maxillary alveolar ridge, (5) one or more teeth are displaced toward the buccal side of the mandibular alveolar ridge, and (6) combinations of the above explanations [25-27].

The number of teeth in crossbite can vary from one upper tooth and one lower tooth to all the posterior teeth on one or both sides of the arch. The number of teeth involved in crossbite is a guide to the severity of the problem: the more teeth involved, the more difficult is the treatment [28].

A lot of studies [11,29-31] have determined that radiographic cephalometry has been one of the most important diagnostic tools in orthodontics. If a facial asymmetry is observed in an orthodontic patient, a postero-anterior (PA) cephalometric radiograph can be taken to the severity of the asymmetry. In diagnosis and treatment planning, the orthodontist must recognize the various characteristics of malocclusion and dento-facial deformity; define the nature of the problem, including the etiology if possible; and design a treatment [32].

Facial asymmetries and development of the orofacial area can be better assessed from a transverse analysis of postero-anterior cephalometric radiographs and the specific needs and desires of the individual. Postero-anterior cephalogram in fact, contains important diagnostic information which shows level and type of asymmetries, in our study 28 patients had mandible asymmetry with inclination of the frontal occlusal plane with facial asymmetry. This finding was usually reported in similar investigative studies [1,10,29,33] which are also confirmed by our results. Unilateral crossbite very often is associated with condylar deviations and in some cases are signs and symptoms of temporomandibular joint disorders [34-35].

CONCLUSION

In this study cephalometrics measurements showed that the patients with transversal disharmony had constriction on the corpus maxillae and the angle which shows the type of crossbite, had large values in the patients with unilateral crossbite. Patients had skeletal, lingual crossbite, lingual inclination of maxillary posterior teeth, and diverging on the occlusal plane. In our study 28 patients with a unilateral crossbite in the right side, had occlusal plane tilt, they had asymmetry in the vertical direction which confirms the fact that skeletal and TMJ changes occurred in the orofacial region.

Early detection of crossbite and their timely and proper treatment will establish a proper function in orofacial system. The choice of treatment depends on the type and extent of crossbite, the patient's age and etiological factor that has caused its forming. Success of treatment at the patients with asymmetry depends on skeletal or dental changes. Dental and small skeletal asymmetries and functional mandibular asymmetries are most often treated by orthodontic therapy. Skeletal asymmetries are preferably treated with a combination of orthodontics appliances and orthognathic surgery.

REFERENCES

- [1] Ricketts MR, Roth HR, Chaconas JS, Schulhof JR, Engel AG. Orthodontic diagnosis and planning. Volume 1, Denver: Rocky Mountain, Data Systems, 1982: 42-143.
- [2] Graber T, Vanarsdall R. Orthodontics-Current principles and techniques. Elsevier Inc, 2011:139.
- [3] Moss ML. The functional matrix hypothesis revisited. The epigenetic antithesis and the resolving synthesis. Am J Orthod Dentofac Orthop 1997; 112(4):410-417.
- [4] Solow B, Tallgren A. Head posture and craniofacial morphology. Am J Phys Anthropol 1976;44:417-436.
- [5] Posnick B. Craniovertical angulation and morphogenetic variables in children: a cephalometric study, thesis. Chapel Hill: University of North Carolina; 1978.

- [6] Linder-Aronson S, Backstrom A. A comparison between mouth and nose breathers with respect to occlusion and facial dimensions. *Odontol Rev* 1980;11:343–376.
- [7] Linder-Aronson S. Respiratory function in relation of facial morphology and the dentition. *Br J Orthod* 1979; 6:59–71.
- [8] Kanurkova L, Gjorgova J. Occlusal and facial aspects in children with posterior crossbite in the permanent dentition. *Balkan Journal of Stomatology* 2004; 8(1):67-70.
- [9] Pinto AS, Buschang PH, Throckmorton GS, Chen P. Morphological and positional asymmetries of young children with functional unilateral posterior crossbite. *Am J Orthod Dentofacial Orthop* 2001; 120:513–520.
- [10] Trpkova B, Major P, Nebbe B, Prasad N. Craniofacial asymmetry and temporomandibular joint internal derangement in female adolescents: a postero-anterior cephalometric study. *The Angle Orthodontist* 2000; 70 :81 – 88.
- [11] Grayson BH, Cutting C, Bookstein LF, Kim H, McCarthy GJ. The three-dimensional cephalogram: Theory, technique, and clinical application. *Am J Orthod Dentofac Orthop* 1988; 94 (4):327-337.
- [12] Melnik KA. A cephalometric study of mandibular asymmetry in a longitudinally followed sample of growing children. *Am J Orthod Dentofac Orthop* 1992; 101 (4): 355-366.
- [13] Kusayama M, Motohashi N, Kuroda T. Relationship between transverse dental anomalies and skeletal asymmetry. *Am J Orthod Dentofacial Orthop* 2003; 123 (3): 329-37.
- [14] O’Byrn LB, Sadowsky C, Schneider B, BeGole AE. An evaluation of mandibular asymmetry in adults with unilateral posterior crossbite. *Am J Orthod Dentofac Orthop* 1995; 107 (4): 394-400.
- [15] Kusayama M, Motohashi N, Kuroda T. Relationship between transverse dental anomalies and skeletal asymmetry. *Am J Orthod Dentofacial Orthop* 2003; 123 (3): 329-37.
- [16] Okeson JP. Management of temporomandibular disorders and occlusion. 6th ed. St Louis: Mosby, 2008:285–331.
- [17] Nerder PH, Bakke M, Solow B. The functional shift of the mandible in unilateral posterior crossbite and the adaptation of the temporomandibular joints: a pilot study. *Eur J Orthod* 1999; 21:155-166.
- [18] Moyers ER, Van der Linden F, Riolo LM, McNamara AJ. Standards of Human occlusal development. Michigan: Monograph, Number 5 Craniofacial growth series, 1976: 49-181.
- [19] Nakamura S, Miyajima K, Nagahara K, Yoko Y. Correction of single-tooth cross bite. *J Clin Orthod* 1995;29(4):257-67.
- [20] Hesse LK, Artun J, Joondeph RD, Kennedy BD. Changes in condylar position and occlusion associated with maxillary expansion for correction of functional unilateral posterior cross bite. *Am J Orthod Dentofac Orthop* 1997; 11 (4): 410-418.
- [21] Buranastidporn B, Hisano M, Soma K. Temporomandibular joint internal derangement in mandibular asymmetry. What is the relationship? *Eur J Orthod* 2006; 28(1):83-88.
- [22] Kecik D, Kocadereli I, Saatci I. Evaluation of the treatment changes of functional posterior cross bite in the mixed dentition. *Am J Orthod Dentofacial Orthop* 2007; 131: 202-215.
- [23] Nanda R, Margolis JM. Treatment strategies for midline discrepancies. *Sem Orthodontics*, 1996; 2(2):84-89.
- [24] Nakamura S, Miyajima K, Nagahara K, Yoko Y. Correction of single-tooth crossbite. *J Clin Orthod* 1995; 29 (4): 257-267.
- [25] Bishara S, Burkey P, Khartouf J. Dental and facial asymmetries: a review. *Angle Orthod* 1994; 64 (2): 89 -98.
- [26] Schellhas KP, Pollei SR, Wilkes CH. Pediatric internal derangements of the temporomandibular joint: effect on facial development. *Am J Orthod Dentofacial Orthop* 1993; 104 :51–59.
- [27] Pirttiniemi PM. Associations of mandibular and facial asymmetries-a review. *Am J Orthod Dentofacial Orthop* 1994;106:191–200.
- [28] Primožič J, Richmond S, Kau CH, Zhurov A, Ovsenik M. Three-dimensional evaluation of early crossbite correction: a longitudinal study. *Eur J Orthod* 2011;10:198.
- [29] Athanasiou , A. E. Orthodontic cephalometry , London : Mosby – Wolfe, 1995.
- [30] Schmid W, Mongini F. A computer-based assessment of structural and displacement asymmetries of the mandibule. *Am J Orthod Dentofac Orthop* 1991; 100(1):19-34.
- [31] Saccucci M, Polimeni A, Festa F, Tecco S: Do skeletal cephalometric characteristics correlate with condylar volume, surface and shape? A 3D analysis. *Head Face Med* 2012, 8: 10-15.
- [32] Staley SR, Reske TN. *Essentials of Orthodontics: Diagnosis and Treatment*. Blackwell, 2011.



- [33] Kawakami M, Yamada K, Inoue M, Kawakami T, Fujimoto M, Kirita T: Morphological differences in the temporomandibular joints in asymmetrical prognathism patients. *Orthod Craniofacial Res* 2006; 9: 71-76.
- [34] Villegas C, Uribe F, Sugawara J, Nanda R. Expedited correction of significant dentofacial asymmetry using a “surgery first” approach. *J Clin Orthod* 2010; 44(2):97-103.
- [35] Myers DR, Barenie JT, Bell RA, Williamson EH. Condylar position in children with functional posterior cross bites before and after crossbite correction. *Pediatr Dent* 1980; 2(3):190–194.
- [36] Zhang J, Jiao K, Zhang M, Zhou T, Liu XD, Yu SB, Lu L, Jing L, Yang T, Zhang Y, Chen D, Wang MQ: Occlusal effects on longitudinal bone alterations of the temporomandibular joint. *J Dent Res* 2013; 92: 253-259.