

Research Journal of Pharmaceutical, Biological and Chemical Sciences

The Use of Low Level Laser Therapy for Pain Reduction During Fixed Orthodontic Treatment.

Snezana Pesevska^{1*}, Marija Maneva², Kiro Ivanovski³, Maja Pandilova¹, Silvana Georgieva¹, Sonja Mindova⁴, Stevica Ristoska⁴, Emilija Stefanovska⁴, Gabriela Curcieva Cuckova⁵, Gordana Apostolova⁶, Elena Apostolova⁷, Filip Koneski⁷

¹DMD, MSc, PhD, Associate professor, Department of Periodontology and Oral Pathology, Faculty of Dentistry, Ss. Cyril and Methodius University, Skopje, R. Macedonia

²DMD, Assistant, Department of Orthodontics, Faculty of Dentistry, Ss. Cyril and Methodius University, Skopje, R. Macedonia

³DMD, MSc, PhD, Professor, Department of Periodontology and Oral Pathology, Faculty of Dentistry, Ss. Cyril and Methodius University, Skopje, R. Macedonia

⁴DMD, MSc, PhD, Assistant research professor, Department of Periodontology and Oral Pathology, Faculty of Dentistry, Ss. Cyril and Methodius University, Skopje, R. Macedonia

⁵DMD, MSc, PhD, Assistant professor, Department of Orthodontics, Faculty of Dentistry, Ss. Cyril and Methodius University, Skopje, R. Macedonia

⁶DMD, MSc, PhD, Assistant, Department of Oral Surgery, Faculty of Dentistry, Ss. Cyril and Methodius University, Skopje, R. Macedonia

⁷DMD, Postgraduate Student, Faculty of Dentistry, Ss. Cyril and Methodius University, Skopje, R. Macedonia

ABSTRACT

The aim of this study was to evaluate the effectiveness of the biostimulative laser treatment in pain reduction in patients with fixed orthodontic appliances. Fifteen patients were treated with low energy level biostimulative diode laser, used 2 minutes per quadrant immediately after placement of fixed orthodontic appliances and in the following four days. The control group of 15 patients received analgesic therapy for period of five days. The pain was assessed subjectively as strong, medium or no pain. The pain disappeared in 20% of the subjects in the examined group after the first day, while in 60% and 26.6% of the subjects medium and isolated pain was still present at day 2 and 3, respectively. The pain disappeared in all the patients treated with laser at day 5. In the control group, strong pain was present in all the subjects the first day, decreasing to 60% of strong pain and 20% medium pain the second day. After day three, the control group demonstrated medium localized pain in 40% of the cases, which dropped to 26.6% after the fourth day, suggesting delayed pain reduction, compared to the laser treated group. Our results suggest that the low energy laser treatment can successfully be used for pain reduction during the initial discomfort period after placing fixed orthodontic appliances.

Key words: low lever laser treatment, analgesics, pain, fixed orthodontic appliances.

**Corresponding author*

INTRODUCTION

Applying fixed orthodontic appliances usually is a reason for some level of discomfort and pain, which can play a key role not only for the cooperation with the patient, but for the treatment success, as well. (1, 2, 3) Literature reports show that the fear of pain is a very important reason for discouraging the patient to agree for this kind of orthodontic treatment. (4) Reducing the pain after the initial applying of the arch is especially important. Most of the patients feel pain 4 hours after the arch applying, gaining the highest level after 24 hours and its lowering in the next few days. (5)

For managing the pain with orthodontic origin, several different methods are recommended: use of nonsteroidal anti-inflammatory drugs (NSAIDs), anesthetic gels, splints, low level laser therapy (LLLT), transcutaneous electrical nerve stimulation (TENS) and vibrational stimulation. (6) The conventional therapeutic approach in dealing with this problem during the fixed orthodontic therapy is oriented towards the usage of medicaments which dominantly have analgesic and anti-inflammatory effects, but in the same time the initial arch should produce limited force. (7) Most of the reports have confronted views for the efficiency and the necessity of NSAIDs use during the orthodontic treatment. (8, 9, 10) Taking into consideration the negative effects of the analgesics, some researchers are seeking for safe alternative methods in reducing the pain, such as the LLLT. (11) There is a number of reports regarding the wide spectrum of biological effects of the laser, including the analgesic effect (due to changes in the cell membrane potential), activating the microcirculation and higher metabolism, immunostimulation, stimulation of the epithelization, as well as the anti-inflammatory effect. (12-17) Some reports approve the positive effects in dealing with this kind of pain (18, 19), while some do not. (20)

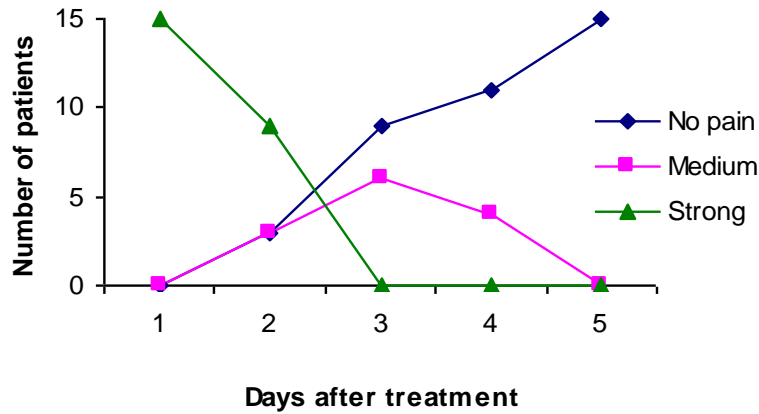
The aim of this study was to evaluate the effectiveness of the biostimulative laser therapy in the treatment of the pain in patients with fixed orthodontic appliances.

MATERIAL AND METHODS

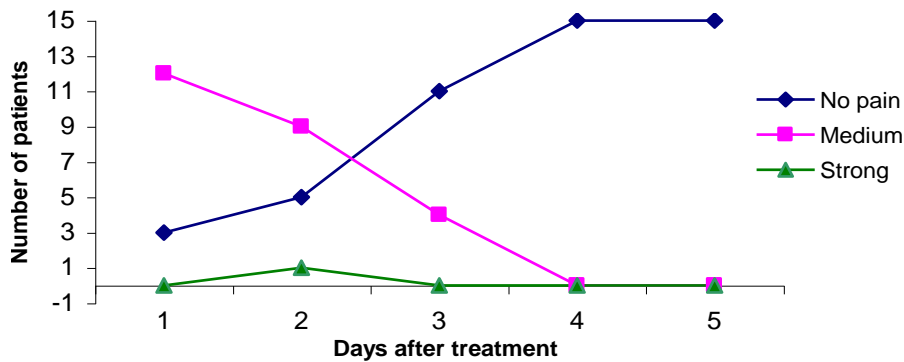
A total of 30 patients with fixed appliances were evaluated in the Clinic for oral pathology and periodontology in Skopje immediately after the arch placing. In 15 patients representing the examined group, a laser treatment was performed right after the applying of the orthodontic appliance and in the following 4 days. Scorpion D-405 7A[®] laser device was used, with wavelength of 630-670 nm, output of 20 mW, and intensity of 220 mW/cm². The duration of each treatment was 2 minutes by area, with one area representing a buccal or oral side in one jaw quadrant and optical attachments with angle of 30° were used. The patients from the control group (n=15) received analgesic treatment with daily administration of 0.5 g metamizol sodium (Analgin[®]). The pain was evaluated daily and assessed subjectively as total absence of pain, moderate and strong pain. The results were statistically analyzed and graphically presented.

RESULTS AND DISCUSSION

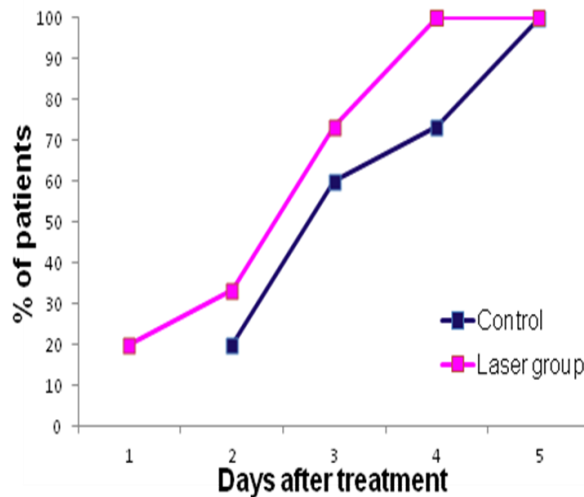
The dynamics of pain in control group during the 5-day period is showed in Graph 1. On the first day, strong pain was verified in 100% of patients, which persisted during the second day in 60%, while moderate pain was a dominant subjective feeling in 40% of the patients on the third day, which lowered to 26,6% on the fourth day. None of the patients experienced pain on the fifth day of the study. Graph 2 shows the pain distribution in the examined group. The pain was absent in 20% (3) of patients on the first day, while moderate and isolated pain was present in 60% and 20% of the patients during the second and third day, respectfully. During the fourth and fifth day, pain was detected in none of the patients treated with laser. The comparison between the data for total absent of pain (Graph 3) shows that the low level laser therapy demonstrated a therapeutic effect immediately after the first visit, and was a reason for total relief of the pain in 20% of the patients, compared to the analgesic therapy which did not have effect during this period. This trend of notable analgesic effect of the laser continued during the all therapeutic period, which led to total absent of pain in all of the patients from the examined group on the fourth day, compared to the control group, in which the pain was present in 11 (73,3%) of the patients.



Graph 1. Pain reduction in the control group



Graph 2. Pain reduction in the laser treated group



Graph 3. Complete pain reduction

The bad aesthetics, discomfort and pain which occur due to teeth movements after applying orthodontics forces in fixed technique are the dominant factors in accepting and adapting to this type of therapy. Literature data indicates to inconsistency in the percent of patients who refer to occurring and lasting of the pain after applying a fixed orthodontic appliance. Daily pain variations with highest level of pain in the evening and night hours were previously reported. Usually the pain lasts for 2-3 days and gradually lowers after 5 to 6 day. (5,6) The results in our study also showed notable presence of pain on the first day in all

examinees in the control group and moderate pain in 80% of the patients in the examined group, as well as a trend for its gradually decreasing on the next observed days. It is most likely that the pain is due to the acute inflammatory reaction as a result not only of the application of the fixed orthodontic appliance, but because of the initial teeth movement, as well. The swelling and increased tissue pressure are other mechanical factors in the development of the pain. Number of mediators (serotonin, bradykinin, PGE) are also involved in the mechanism of pain occurrence, by increasing the local vasodilatation and capillary permeability and by altering the sensitivity and receptivity of the receptors in the specific area. By this way, the pain threshold gets very low, that the nociceptors became much more sensitive to the stimulus, just like the mechanoreceptors. For pain relief, most of the orthodontists prescribe NSAIDs, which inhibit the prostaglandin production. Their administration in low doses on the first or second day of the initial phase would not considerably affect the process of movement. Nevertheless, most of these medicaments have side effects to the teeth movement if used in a long period of time (due to the inhibition effect to the prostaglandins). (21) The systemic side effects should not be neglected, as well. (22-24) There are a lot of reports for using these analgesics in orthodontic practice; there is a view-point for their usage as a first choice medicament, regardless the type (ibuprofen, acetaminophen or aspirin), because of the lack of evidence for the efficiency of the laser therapy and other non-pharmacological modalities. (11)

In our study, the examinees from the control group were recommended to take Analgin (0,5 g metamizol sodium), which was the reason for the absence of strong pain after the third day, but the total absence was noted after the fifth day (Graph 1). This is in accordance with the reports which support the efficiency of the analgesic therapy. (10, 21, 25) Literature review showed the most prescribed analgesics are NSAIDs, while there are no reports for the usage of metamizole medicaments during the orthodontic treatment. Metamizole belongs to the group of non-opioid analgesics. The mechanism of its action is still not well elucidated, but it is thought that it and its metabolite (4-N-Methylaminoantipyrin) inhibit the pain through effect to prostaglandins, so it is likely that this is the reason for its similar effect to the one of the NSAIDs. By our opinion, the similarity in the mechanism of action of the Analgin with the NSAIDs is the reason for the results which prove its analgesic effect in this study.

The analgesic effects of the low level laser light are used in different clinical conditions. Laser analgesics is a therapeutic modality which benefit is the non-invasive manner, the easy application and absence of negative tissue responses. Thus, it is worth to review its potential for applying in orthodontics. The dominantly positive and verified experiences in minimizing the pain during fixed orthodontic treatment speak not only for the laser light's anti-inflammatory and analgesic effect, but for the quicker teeth movement and alveolar bone remodeling, which minimizes the discomfort and pain in the initial phase of fixed orthodontic treatment and reduce the treatment time. The extraordinary clinical effects from the laser to the relief of pain in the initial teeth movement during the fixed orthodontic treatment (1, 19) are a strong reason for the clinical applying to overcome the trend for elucidation of its biological mechanisms.

The mechanism of analgesics of the laser therapy is due to the direct effect of the laser to the nerve fibers, with that stabilizing their depolarization potential, but also to the effects to the cell's and biochemical processes during the inflammatory response (20, 27). Because the immediate analgesic effect was not noted, but it was demonstrated 24-48 hours after the application (Graph 2), the results in this study support the hypothesis that the analgesics is mainly due to the laser effect to the inflammatory process.

LLLT may have a positive effect in orthodontic patients not only immediately after applying the initial arch, but generally in preventing and treating the pain during the treatment- changing of arch, use of separators etc. Turhani et al. (1) showed that laser irradiation in one session immediately after applying the appliance, reduces the pain after 6 and 30 hours, which is not in accordance to our results. Tortamano et al. (19) concluded that the lasers (GaAlAs, 830 nm, output energy 30 mW) are efficient in the time of applying the arch, because the patients reported lower pain and pain intensity during the most painful day. During the laser treatment, the pain got lower quicker, as well.

The evaluation of the LLLT effect to the pain in orthodontic treatment in the studies (26, 27) showed that the pain intensity in the laser group is on lower level, but not statistically significant from the control group. Won Tae Kim et al. (28) reported that the effect of the laser therapy is not superior, but reduce the pain in its highest level, compared to the groups with placebo and analgesic. In other study (29), significant differences were found between LLLT and placebo groups, with LLLT group showing lower average values of

the pain level for the whole period of time. Contrary, Esper et al. (20) reported that there was no significant reduce of pain in laser group, compared to placebo group. The inconsistency in these reports is due to the modalities of its applying manner, like one-session (1, 19, 30), or multiple-session therapy during a few days (18, 26), which can be the reason for the different efficiency of the laser therapy. It is thought that the more frequent laser irradiation in the period of discomfort or pain may lead to significant reduce in their perception. After the laser therapy, in the examined group a reduction of pain was noted in the second visit, with complete absence of pain in 3 patients (20%) (Graph 2), which is in accordance with a part of the reports (27, 29), which also verified the considerable pain reduction in patients treated with laser. The fact that the laser induces fast pain relief after the first therapy and a total reduce of pain after the fourth day, compared to the control group where the strong pain relief was noted after the third day in 60% and complete absence of pain was noted after the fifth day, is another prove for the laser analgesics effect (Graph 1). Taking into consideration these findings and that PGE2 is one of the most important chemical mediators in the acute phase of inflammation which is also a factor responsible for pain production, we propose the connection between the laser induced inhibition of PGE2 and block of the cyclooxygenase with the reduction of pain (31), and we interpret our results in this context.

Biomicroscopic investigations and periodontal condition show that the gingival circulation becomes normal after the laser therapy, while the capillary permeability and venous congestion reduces, which lead to quick correction of the inflammation and pain reduction (32). The positive effects of the laser to the circulatory dynamics are approved by many researches (31, 33, 34). The complex effect of LLLT is a reason for the results in this study. Further researches for different manners of laser therapy in specifying the modality of its use, its dose and application are necessary, so it can be verified as efficient clinical procedure which will have a significant contribution in orthodontics.

CONCLUSION

The low level laser therapy in a non-invasive and safe procedure which can be successfully used for pain management during fixed orthodontics treatment. Further researches are necessary to elucidate and specify the possible mechanisms of pain reduction with laser therapy.

REFERENCES

- [1] Turhani, D., Scheriau M, Kapral D, Benesch T, Jonke E,& Bantleon, HP. Am. J. Orthod. Dentofacial. Orthop.,2006;130(3): 371-377.
- [2] Young, AN., Taylor, RW., Taylor SE, Linnebur SA,& Buschang PH. Angle Orthod. , 2006; 76(2): 251-259.
- [3] Bird SE, Williams K, Kula K. Am. J. Orthod. Dentofacial. Orthop. 2007;132:504–510.
- [4] Keim RG. J. Clin. Orthod. 2004;38:641-2.
- [5] Polat O., Karaman, Al.,& Durmus, E. Angle Orthod., 2005;75(5): 791-796.
- [6] Narkhede Sameer , Karthik Shetty ,Shushma Sonawane ,Nitin Gadhiya. IJDPMS, 2013;Vol (1) Issue (3):15-23.
- [7] Bernhardt MK, Southard KA, Batterson KD, Logan HL, Baker KA, Jakobsen JR. Am. J. Orthod. Dentofacial Orthop. 2001;120:20–27.
- [8] Paulose J. Indian Dentist Research and Review, 2009; 4: 56-58.
- [9] Reddy, C. Munish, Ahuja, N. K. Reddy, Vandana. Indian Journal of Dental Sciences . 2010; Vol. 2 Issue 3:7-9.
- [10] Krasny M., M Zadurska, G Cessak and P Fiedor. Acta Poloniae Pharmaceutica and Drug Research. 2013;Vol. 70 No. 3 :573-577.
- [11] .Xiaoting L., Yin T., Yangxi C. Angle Orthodontist. 2010; 80: 925-32.
- [12] Snezana P., Marija N., Icko Gj., Nikola A., Kiro I., Salvador N., Sebastiano A.. Lasers in Medical Science.2012;Vol. 27, Issue 2:377-381.
- [13] 13. Obradović R., Lj. Kesić, S Pesevska, Lasers in Medical Science.2009;Vol. 24, Issue 3 447-451,
- [14] Mărtu S, Amalinei C, Tatarciuc M, Rotaru M, Potârniche O, Liliac L,et al. Rom J. Morphol. Embryol. 2012;53:111-6.
- [15] Amorim JC, de Sousa GR, de Barros Silveira L, Prates RA, Pinotti M, Ribeiro MS. Photomed. Laser Surg. 2006;24:588-94.
- [16] Lui J, Corbet EF, Jin L. J. Periodontal Res. 2011;46:89-96.

- [17] Bjordal JM, Johnson MI, Iversen V, Aimbire F, Lopes-Martins RA. Photomed. Laser Surg. 2006;24:158-68.
- [18] Doshi-Mehta G, Bhad-Patil WA. Am. J. Orthod. Dentofacial Orthop. 2012;141:289–297.
- [19] Tortamano A, Lenzi DC, Haddad AC, Bottino MC, Dominguez GC, Vigorito JW. Am. J. Orthod. Dentofacial Orthop. 2009;136:662–667.
- [20] Esper MA, Nicolau RA, Arisawa EA. Lasers Med. Sci. 2011;26:657–663.
- [21] Poveda-Roda R, Bagán JV, Jiménez-Soriano Y, Gallud-Romero L. Med. Oral. Patol. Oral Cir. Bucal. 2007;12:10-8.
- [22] Nandita Shenoy, Siddarth Shetty, Junaid Ahmed, AshokShenoy K. Orthodontics Journal of Clinical and Diagnostic Research. 2013;Vol7(6): 1258-1260.
- [23] Bradley Rebecca, Pamela E. Ellis, Peter Thomas, Hugh Bellis, Anthony J. Ireland, et al. Am. J. Orthod. Dentofacial Orthop. October 2007; 132 (4): 511-17.
- [24] Oscar R. Arias, Maria C. Marquez-Orozco. Aspirin, acetaminophen, and ibuprofen: Am. J. Orthod. Dentofacial Orthop. September 2006; 130(3): 364-70.
- [25] Sergl H.G., Klages, U., Zentner, A. Am. J. Orthod. Dentofacial Orthop. 1998;114:684–691.
- [26] Youssef M, Ashkar S, Hamade E, Gutknecht N, Lampert F, Mir M. Lasers Med. Sci. 2008;23:27–33.
- [27] Lim HM, Lew KK, Tay DK. Am. J. Orthod. Dentofacial Orthop. 1995;108:614-22.
- [28] Won Tae Kim, Mohamed Bayome, Jun-Beom Park, Jae Hyun Park, Seung-Hak Baek, and Yoon-Ah Kook. The Angle Orthodontist. 2013, Vol. 83, No. 4: 611-616.
- [29] Nóbrega Celestino, Edina Mariko Koga da Silva, and Cristiane Rufino de Macedo. Photomedicine and Laser Surgery. 2012; 31(1): 10-16. doi:10.1089/pho.2012.3338.
- [30] Rodrigo Duarte Farias, Luciane Quadrado Closs, and Sergio Augusto Quevedo Miguens Jr .
- [31] The Angle Orthodontist. 2016; Vol. 86, No. 2:193-198. doi: <http://dx.doi.org/10.2319/122214-933.1>
- [32] Suresh Snophia, Satyanarayana Merugu, Nimisha Mithradas, Sivasankari. SRM Journal of Research in Dental Sciences. 2015; Vol. 6, Issue 1:53-56.
- [33] Ihsan FR. Photomed. Laser Surg. 2005;23:289–94.
- [34] Hayashi H, Terao A, Kunimatsu R, Kawata T. PLoS ONE. 9(6): e100066. doi:10.1371/journal.pone.0100066
- [35] Viegas VN, Abreu ME, Viezzer C, Machado DC, Filho MS, Silva DN, et al. Photomed. Laser Surg. 2007;25:467-73.