

Research Journal of Pharmaceutical, Biological and Chemical Sciences

Protective Effect of Aqueous Extract of *Annona muricata* Leaves Against Copper Induced Hepatotoxicity in Experimental Rats.

Buter Samin¹, Edy Fachrial², Refilda³, Zulkarnain Chaidir³, and Almahdy^{4*}.

¹Department of Radiology, Faculty of Medicine, University of Prima Indonesia, Medan, North Sumatera, Indonesia.

²Laboratory of Molecular Biology, Faculty of Medicine, University of Prima Indonesia, Medan, North Sumatera, Indonesia.

³Department of Chemistry, Faculty of Mathematics and Natural Science, Andalas University, Padang, West Sumatera, Indonesia.

⁴Faculty of Pharmacy, Andalas University, Padang, West Sumatera Indonesia.

ABSTRACT

This present study investigated the protective effect of *A. muricata* leaves antidote against Cu(II) induced toxicity in experimental rats. Administration of Cu(II) (1000 mg/L) intraperitoneally in experimental rats lead to the increasing of liver and kidney function parameters and oxidative stress parameters including SGOT, SGPT, urea, creatinine and malondialdehyde (MDA). Histological analysis of liver tissue indicate that administration of Cu(II) resulted in central vein dilation, swelling of hepatocytes and necrosis. Pre treatment with *A. muricata* leaves antidote significantly reduced the levels of liver and kidney function parameters and oxidative stress in rats. Decreased levels of SGOT, SGPT, urea, creatinine and MDA were 23,64%, 63,51%, 27,12, 44,37% respectively, compared with rats that were administered with Cu(II) alone. Histologically, pre treatment with *A. muricata* leaves antidote is able to reduce the effects of damage to the liver structure due to toxicity of Cu(II)

Keywords: *Annona muricata*, Cu(II), oxidative stress, antidote

*Corresponding author

INTRODUCTION

Heavy metals is defined as metallic elements that have high density compared than water and could induce toxicity even at low levels of exposure. Because of its usefulness in the field of industry, agricultural, medical and applied technology, led to widespread distribution in the environment, leading to negative effect to human health [1]. One of the heavy metal is copper (Cu), even though essential for life, but it could lead toxic effect at higher concentration [2].Copper is the catalyst that could lead to oxidative stress through the formation of reactive oxygen species (ROS) and causing tissue damage by lipid peroxidation [3]. Copper sulphate is the most common copper salt, and it absorbed into the systemic circulations from gastrointestinal tract, lungs and skin. The gastrointestinal absorption of copper is influenced by a number of factors including its chemical form. Absorbed copper binds to plasma albumin and amino acids in the portal blood and transported to the liver where is is incorporated into ceruloplasmin and released into plasma [4].Exposure to copper cause negative effect on the liver including increased activity of alanine aminotransferase (ALT), aspartat aminotransferase (AST), alkaline phospatase (AP), malondialdehyde (MDA), hepatocellular necrosis and effects on renal [5].

Annona muricata Linn (Annonaceae) is a low branching, bushy tree and native to Caribbean and America, but now has spread in various tropical countries throughout the world. The previous studies revealed the leaves of *Annona muricata* Linn showed various pharmacognostic properties including antimicrobial [6], antidiabetic [7] and anti spasmodic [8]. Samin et al [9] reported that the leaves of *A.muricata* effectively could be used as a biosorbent for adsorption of copper with adsorption capacity up to 6,14 mg/g. The study on utilization of *A. muricata* leaves in combating copper toxicity has not been done. Chaidir et al [10] reported *Annona muricata* seeds could use as potential adsorbent of rhodamin B from aqueous solution withbiosorption capacity 53,376 mg/g. The present study concerning in utility of *A. muricata* leaves antidote as hepatoprotector in experimental rats induced by copper.

MATERIALS AND METHODS

Preparation of antidote of *A.muricata* leaves

The leaves are washed with running water then air dried at room temperature for 2 weeks. The leaves that have dried then milled into powder form using blender. 2 g of powdered leaves of *A. muricata* diluted with distilled water while keeping mashed, then transferred into a beaker glass and add distilled water up to 120 mL. The obtained solution then heated to boil and then filtered using filter paper. The filtrate was stored in a sealed bottle and use to treat animals as needed. The experimental rats provided with a nutritionally adequate diet and drinking water *ad libitum* during the study

Animals

Male white rats weighing approximately 140-160 g were obtained from Andalas University, Padang, Indonesia for experimental purpose. The Animal Ethics Committee of Andalas University has approved the experimental protocol. The experimental rats provided with a nutritionally adequate diet and drinking water *ad libitum* during the study

Chemicals

CuSO₄.5.H₂O was purchased from Merck (Darmstad, Germany)

Experimental Design

Male white rats were randomly divided into 3 groups of 3 rats in each group and treated by oral gavage. Group 1 was the control group, only received distilled water. Group 2 was the antidote-treated group. The rats received 5 mL x bw/200 g bw for one week, the on the 8th days, followed by injection of 1 mL x bw/200 g bw CuSO₄.5.H₂O 1000 mg/L intraperitoneally. Group 3 was given 1 mL x bw/200 g bw CuSO₄.5.H₂O 1000 mg/L intraperitoneally. Following 5 hours later, the animals were killed under light anesthesia chloroform. The aliquot of blood was taken for biochemical analysis and oxidative stress. Liver tissue was excised and fixed in 10% formalin solution for histological studies.

Biochemical analysis and oxidative stress

Oxidative stress was estimated by determined the malondialdehyde (MDA) level in serum. For the procedures is as follows, 3 test tubes, each containing distilled water, serum and MDA standard solution were prepared. In each tube was added 2,5 mL of 5% trichloroacetic acid (TCA) and centrifuged for 10 minutes at a speed 2000 rpm. The obtained filtrate then removed by using pipette and added to the new test tube. 1,5 mL Na thio barbituric then were added into each tube, homogenized and then heated in water bath. Read the absorbance at 530 nm. Two reagents method (Substrate Start) was used to determined the level of liver function parameters.

Histopathology analysis

The liver was washed with sterile saline water and fixed in 10% formalin for approximately 17 hours in room temperature. The tissue then washed under running waters and dehydrated. The slice of tissue (5-6µm) was stained with hematoxylin and eosin and examined under the microscope

Statistical analysis

All quantitative measurements were analyzed using one way analysis of variance (ANOVA) with using Statistical Package for Social Science ver 16.0 (SPSS ver 16) and followed by Bonferroni test and Tukey test.

RESULT AND DISCUSSION

Effect of *A.muricata* leaves antidote on liver and kidney function parameters

Effect pre treatment with *A.muricata* leaves antidote on SGPT, SGOT and MDA level was showed in Table.1. MDA levels in group II had increase significantly compared to group I (control) up to 56%. Subsequently in group III, the froup pre treated with *A.muricata* leaves antidote, MDA level was significantly decreased until undetectable level. Lipid peroxidation is a mechanism of cellular damage that occurs in plants and animals and was used as an indicator of oxidative stress in cells and tissues. The elevated levels of MDA in group II is an indicator of the damage to cell membranes, which mostly composed by lipids. In addition, the end product of lipid peroxidation could be mutagenic and carcinogenic [11].

Table 1. The mean level of malondialdehyde (MDA), SGOT and SGPT

No	Parameters	Group 1 (Control)	Group 2 (Cu (II) treatment)	Group 3 (pre treatment with antidote)
1	Malondialdehyde (MDA) (mg/dl)	2,09	3,17	2,76*
2	SGOT (U/L)	26,43	70,63	53,93*
3	SGPT (U/L)	33,43	171,4	62,53*
4	Urea (mg/dL)	13,1	35,13	25,6*
5	Creatinine (mg/dL)	0,51	1,69	0,94*

*P<0,05 compare to Group 2

Based on the table above, in group III, administration of Cu (II) intraperitoneally did not increased the levels of MDA. The protective effect is probably due to antioxidant content in *A.muricata* leaves including flavonoid, alkaloid and terpenoid. Gavakumulya [12] reported that aqueous extract of *A.muricata* leaves are rich in various secondary metabolites and antioxidants, saponin, terpenoid, flavonoid, coumarin and lactones, anthraquinone, tannin, cardiac glycosides, phenols and phytosterols. Antioxidants play a role in preventing oxidative stress by free radicals, by scavenging, inhibit lipid peroxidation or metal ion chelation.

SGOT and SGPT are the marker for liver activity [13]. SGOT or AST are plasma non-functional enzyme that is normally located in the hepatocytes, gills, kidneys, muscles and other organs. SGPT or ALT is a key metabolic enzyme that is released if there is damage to heptocytes. These enzymes have a role in converting protein into glycogen which is "fuel" to the body during toxicity due to the oxidative stress in the liver [14]. Based on the result, there is significantly elevated levels of SGPT and SGOT in rats in group II, so that is expected that there is damage to the liver due to Cu (II) exposure. Administration of *A.muricata* leaves

antidote were able to significantly reduced the SGOT and SGPT levels. This indicate the protection effects of flavonoids against copper toxicity. In addition the protective effect of *A.muricata* leaves might be due to chelating effects of Cu (II). Almansour [15] reported that protective effect found in soy beans extract against the toxicity of copper particularly protection of the liver, are mainly caused by flavonoids contained in soybeans. Hasish and Elgami [16] reported the administration of curcumin extract on experimental mice that were exposed with copper could restore the levels of liver enzyme marker (AST, ALT, ALP and GGT) near to normal level. The decrease on liver enzyme activity in the group with administration of curcumin showed therapeutic and protective effects of curcumin.

Based on the results, there is a significant decrease of urea and creatinine levels in group 3 compared to group 2. This indicates that pre treatment with *A.muricata* leaves antidote has protective effect against kidney damage induced as a result of exposure to heavy metals. Arthur et al [17] reported that phytochemical screening of *A.muricata* leaves showed that *A.muricata* contains saponins, flavonoids, tannins and glycosides. These compound contribute to the treatment of various diseases, including treatment for kidney impairment.

Histopathology Analysis

The protective effect of *A.muricata* leaves antidote against Cu (II) induced hepatotoxicity were analyzed histologically as shown in Figure 1.

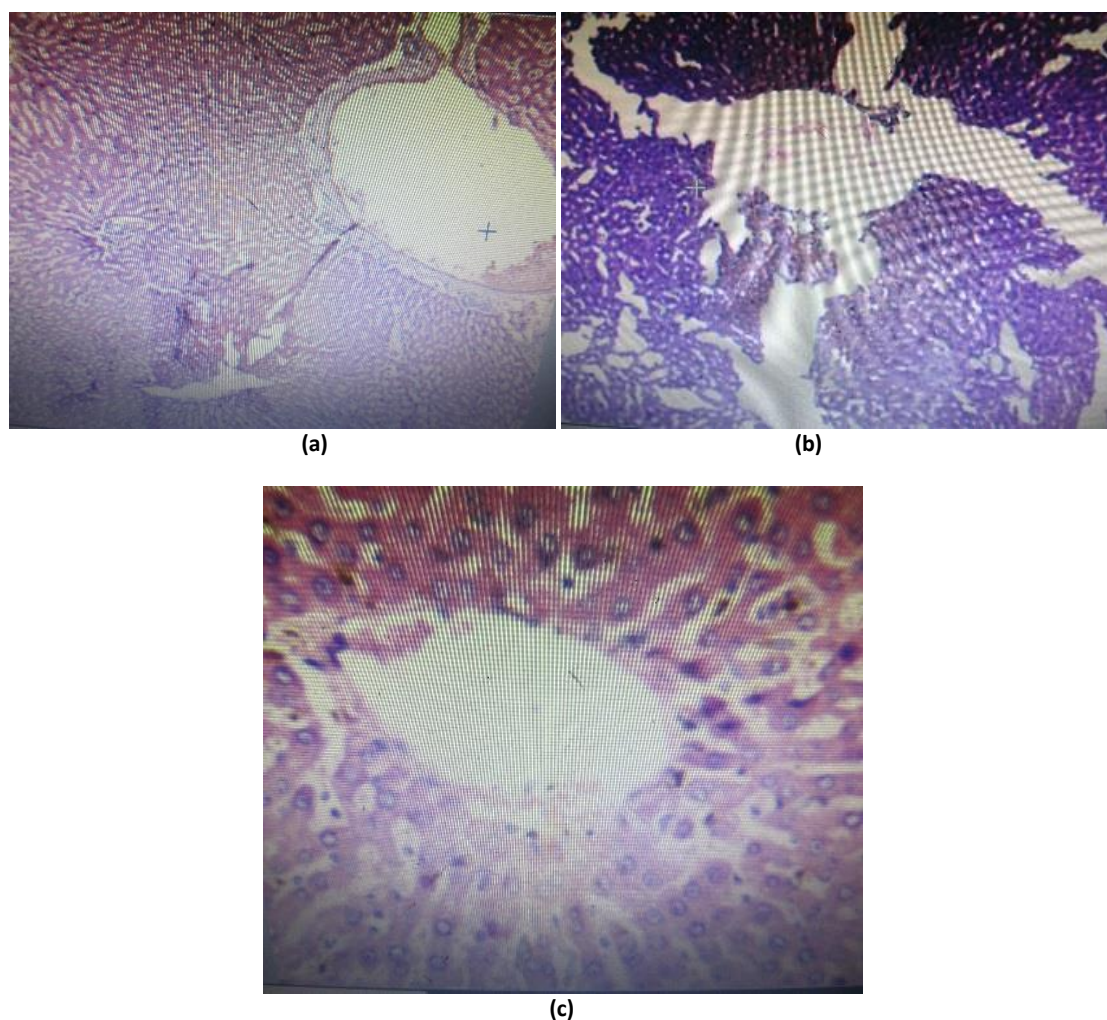


Figure 1. Histology analysis of experimental rat's liver, (a) Photomicrograph of rats liver in control group, only treated with distilled water during experimental, (b) photomicrograph of rats liver in group 2 (administration with Cu (II) 1000 mg/L), slices of liver tissue consisting of lymphocytes, arranged to form a sinusoid with dilated central vein and swelling of hepatocytes, (c) photomicrograph of rats liver in group 3 (pre treatment with *A.muricata* antidote), lobules and central venous appear in normal structure.

Various damage of tissue liver due to exposure to copper have been frequently reported. Mohammed et al [18] the administration of copper with 1/5 LD50 dose for 6 months led to hyper eosinophils tubular epithelial cells, necrosis, nuclei pyknotic, and loss of cell structure. Baskar et al [19] reported exposure with copper sulphate 100 mg/L for 5 months in mice resulted in hepatocellular degeneration and necrosis. Multifocal infiltration of lymphocytes and plasma cells are also observed, there is also a central vessel dilation filled with erythrocytes. Once copper enters the bloodstream, liver is the first organ to undergo deposition of copper. Copper toxicity is generally indicated by the occurrence of liver cirrhosis, hemolysis and necrosis of the liver cells, causing the release of enzyme markers of liver function including SGOT and SGPT into the bloodstream so the levels of that enzyme is increased in serum [18]. A variety of liver damage is also triggered by the increased activity of lipoyxygenase, which is an enzyme that catalyzes the lipid peroxidation, particularly unsaturated fatty acids. Exposure to heavy metals will form free radicals and increases the levels of malondialdehyde which is a product of lipid peroxidation, an indicator of oxidative stress, and increased levels of malondialdehyde is directly related to the concentration of the heavy metals.

Pre treatment with *A.muricata* leaves antidote could reduce the effects of the damage caused by copper exposure that induces oxidative and lipid peroxidation. This is due to antioxidant content and free radical scavenging activity in *A.muricata* leaves. Baskar et al [19] reported the antioxidant activity of ethanolic extract of 3 species soursop leaves. *A.muricata* with concentration 500µg/L indicate a maximum scavenging activity up to 90,05%, followed by hydroxyl radical scavenging activity up to 85,88%, despite *A.muricata* leaves extract demonstrated moderate lipid peroxidation inhibition. This high antioxidant activity is probably due to the presence of compounds that are known as acetogenins, which plays an important role in free radical scavenging.

CONCLUSION

Cu(II) exposure in experimental rats will lead to changes level of serum biochemical parameters including liver function enzyme, kidney function enzyme and oxidative stress indicators. Pre treatment with *A.muricata* leaves antidote is able to restore the levels of serum biochemical parameters and indicators of oxidative stress approximately to normal level. This means *A.muricata* leaves antidote could reduce the toxic effect of copper exposure in rats. Liver histology analysis indicate that exposure to copper could cause damage to liver cells such as hepatocytes swelling and necrosis. Pre treatment with *A.muricata* antidote leaves could reduce the damage of the liver that might be due to high content of antioxidant and free radical scavenging activity

REFERENCES

- [1] Tchounwou PB, Yedjouy CG, Patlolla AK, Sutton J. NIH Public Access 2014 :101 : 133-164
- [2] Velkova Z, Stoytcheva M, Gochev V. J.BioSci.Biotech 2012 : 1 (2) : 163-169
- [3] Hashish EA and Elgami SA. Indian Journal of Clinical Biochemistry 2015: 1-11
- [4] Sakhae E, Babaei H, Abshenas J, Azari O, Kheirandish R, Ebrahimi-Meymand F. Veterinary Research Forum 2011: 2 (4) : 232-237
- [5] Mohammed SA, Bakery HH, Abuo Salem ME, Nabila AM, Elham AE. Benha veterinary Medical Journal 2014 : 27 (1) : 146-156
- [6] Osuala FN, Ohadoma SC. Asian Journal of Pharmaceutical Technology & Innovation 2015: 03 (12) : 132-136
- [7] Adeyemi D, Oriji E. Afr J Tradit Complement Altern Med 2008 : 6 (1) : 62-69
- [8] De Souse O. W J Biotech 2010 : 11(5) : 2067-2078
- [9] Samin B, Fachrial E, Almahdy, Munaf E, Refilda, Chaidir Z. Journal of Chemical and Pharmaceutical Research 2015. 7 (9S) : 22-27
- [10] Chaidir Z, Furqani F, Zein R, Munaf E. Journal of Chemical and Pharmaceutical Research 2015; 7(4) : 879-888
- [11] Bharali MK. Journal of Global Biosciences 2013. 2 (5) : 121-125
- [12] Gavakumulya Y, Elella FA, Wamunyunkoli F, Ael-Shemy H. Asian Pacific Journal of Tropical Medicine 2014. 7 (1) : 355-363
- [13] Alagammal M, Sakhtidevi G, Mohan VR. Journal of Advanced Pharmaceutical Sciences 2013. 3 (1) : 385-393



- [14] Rajamanickan V and Mysthuswamy N. Maejo International Journal of Science and Technology 2008. 2 (01) : 192-200
- [15] Almansour MI. International Journal of Zoological Research 2008. 4 (3) : 165-175
- [16] Hashish EA and Elgami SA. Ind.J.Clin.Biochem 2015.4-11
- [17] Arthur FKN, Woode E, Terlabi EO, Larbie C. European Journal of Experimental Biology 2011. 1 (4) : 115-124
- [18] Mohammed SA, Bakery HH, Abuo Salem ME, Nabila AM, Elham AE. Benha Veterinary Medical Journal 2014. 27 (1) : 146-156
- [19] Baskar R, Rajeswari V, Sathish Kumar T. Indian Journal of Experimental Biology 2007. 45 : 480-485