

# Research Journal of Pharmaceutical, Biological and Chemical Sciences

## Cytomorphological Changes Hepatorenal System Combined With Fever Poisoning Xenobiotics.

Papunidi Konstantin Khristoforovich\*, Kadikov Ilnur Ravilevich, Saitov Vadim Rasimovich, Tremasov Mikhail Yakovlevich, Tremasova Anna Mikhailovna, Sunagatullin Faruk Akhmadullovich, and Smolentsev Sergey Yurievich<sup>1</sup>.

Federal Center for Toxicological, Radiation and Biological Safety, Russia, 420075, Kazan, Nauchny Gorodok-2  
<sup>1</sup>Mari State University, Russia, 424000, Yoshkar-Ola city, Lenin Square 1.

### ABSTRACT

In toxicological aspect how «scenario» of interaction of toxic substances will develop is of a great interest, at complex application? And especially the toxins having various nature of an origin. For clarification of features of similar of a protsessametodama of histology and electronic microscopy, we have put experiment on the combined poisoning of pigs with dioxin and T-2 toxin in doses of 1/400 LD<sub>50</sub> and 2 PDK. The analysis of cytomorphological changes in a liver and kidneys shows the following pathological violations: dystrophic phenomena, deskvamation centers, chromatin consolidation, increase in perinuclear space, cytoplasm enlightenment, existence very large vacuole, sharp reduction of a granular endoplasmic reticulum, lack of a glycogen, change of a form of small tsitopody, disintegration of slot-hole diaphragms, destruction of mitochondrions. The findings suggest that the influence pathologic expressed toxicants tested when combined admission to the pigs hepatorenal system.

**Keywords:** pigs, hepatocytes, epiteliotsit, dioxin, T-2 toxin.

*\*Corresponding author*

## INTRODUCTION

Under natural conditions dwellings biological objects are affected by a complex of substances, many of which are a consequence of human activity. It is well known that dioxins and dioxin-like polychlorinated biphenyls.

It is well known that dioxins and dioxin-like polychlorinated biphenyls supertoxicants are capable of accumulating in the food chain, enter the body of animals and humans, often with unpredictable consequences [7, 3, 18, 8, 10, 12].

Continuous and serious threat to human health and pets are mycotoxins – biogenous poisons, including T-2 toxin [5, 1, 9, 20, 22, 13].

Besides shift of the hematologic, biochemical and immunological statuses [15, 16, 19, 11,17, 14] at influence of xenobiotics, in an organism of animals depending on a dose and a form of intake of toxins there are changes of microscopic and submicroscopic structures that in turn is of important interest to basic researches.

Despite a set of articles of the bodies devoted to ultrastructural researches subjected to toxic influence, the analysis of scientific literature confirms the actual lack of the works concerning a problem of the combined impact of various xenobiotics on an organism of farm animals. This direction, are the purpose of scientific researches, the staff of department of toxicology of the Federal center of toxicological, radiation and biological safety [2, 4, 21].

## MATERIALS AND METHODS

Researches are conducted on pigs of breed "Large-white", reached 2-month age, with a live weight from 14 to 17 kg. For morphological researches, control and skilled individuals brought out of experiment according to «The international recommendations about carrying out medicobiological researches with use of laboratory animals». For the morphological analysis studied histo- and ultrastructure of cages of a parenchyma of a liver and cortical substance of kidneys. Applied to experimental chronic intoxication of pigs:

- 2,3,7,8-tetrachlordibenzol-para-dioxin (further dioxin), produce PO "Khimprom" Bashkortostan (Ufa);
- Crystal T-2 the toxin, laboratories mycotoxins FGBNU «FTsTRB-VNIVI» (Kazan) meeting the requirements of GOST 10-07-301-86 and not differing in physical and chemical parameters and toxic properties from the existing standards.

During experiments supported identical conditions of keeping and feedings of experimental and control animals, according to zootechnical norms.

Experiment continued 45 days. The first group was biological control and received a usual diet. Animals of the second group were subjected to the daily oral combined priming 2,3,7,8-THDD in a dose of 15 mkg/kg of body weight that corresponds 1/400 LD<sub>50</sub> and T-2 toxin at the level of 2 PDK (200 mkg/kg of a forage).

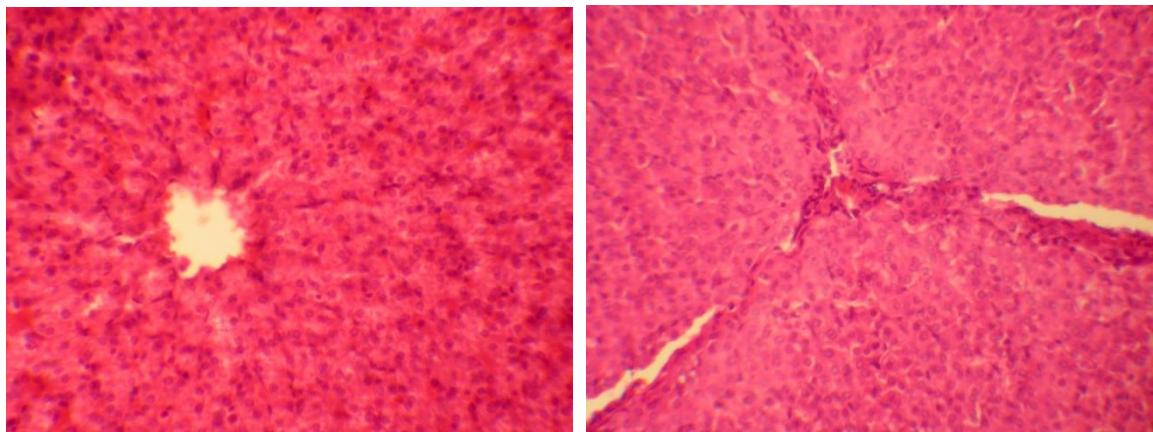
For histologic researches samples of fabrics fixed 10% neutral formalin, after dehydration filled in paraffin. Histologic cuts received by means of the arch microtome, painted Ehrlich's hematoxylin-eosin water. Microphotographing was carried out on installation: microscope of Leica DM 1000, Leica DFC 320 digital camera (Germany).

For electronic microscopy preparation of the selected material was carried out to the poklassicheskoy scheme [6]. Samples fixed in 1% glutaraldehyde solution (SERVA, Germany) on 0,1M the phosphatic buffer (PH 7,4) of 12 hours in the refrigerator. Post-fixing was carried out in 2% solution of a four-oxide of osmium (The Moscow chemical plant) on the same buffer by 2 hours. After material dehydration in spirtakhhkusochna of samples concluded in mix the eponovykh (Epon 812, DDSA, MNA, DMP-30) of pitches (Fluka). Ultrathin cuts received on the LKB III 8800 ultramicrotome, were mounted on electronic and microscopic grids and painted uranilatsetaty (1 hour) and lead citrate (1,5 min.). Studied in an electronic microscope of JEM 100CX-II («Jeol»),

Japan). Shooting was carried out on a phototechnical film of AGFA ORTHOCHROMATIC. Digitization of negatives was made on the EPSON PERFECTION 4990 PHOTO scanner with the resolution of 600 dpi. The end result was processed by means of the ACD SeeProv.6 programs. and Axio Vision Rel. 4.8 (Carl Zeiss).

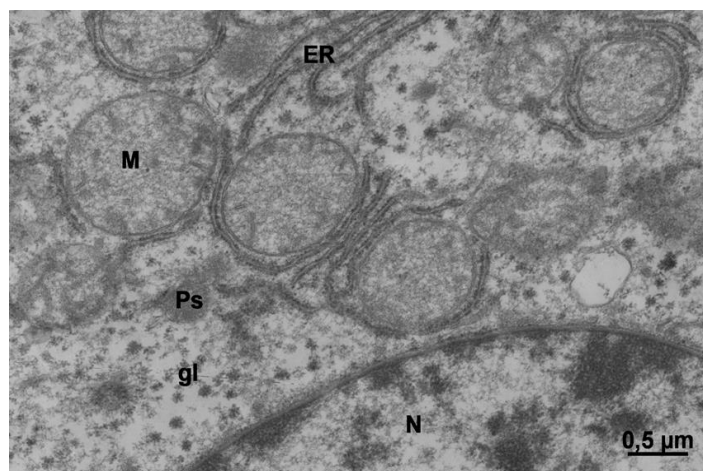
**RESULTS OF RESEARCHES**

A When the light-optical study of histological sections of the liver of the control group of pigs found areas that have typically lobular structure. Hepatic lobule hepatic form long beams, consisting of hepatocytes, radiating to the periphery of the central vein. In the liver slices positioned hepatic sinusoid (Fig. 1a). The guinea pig liver dystrophy protein observed cell necrosis in some of them. Enroll perivascular hemorrhage, resulting in some of the sinusoids are found white blood cells with dense nuclei and cell detritus. In sections visualized interstitial edema and infiltration poliekssudativnaya (Fig. 1b).



**Fig. 1 a, b - Sites of a liver: a) a pig of control group, b) the pig receiving combined dioxine in a dose 1/400 LD<sub>50</sub> and T-2 toxin in a dose 2 PDK (lens 20)**

Electronic and microscopic researches of samples of a liver of control pigs have revealed kernels of cages of rounded shape in the central part of a cage. Eukhromatin is evenly distributed on a kernel in the form of fibrillyarny and melkoglobulyarny substance (fig. 2). The condensed chromatin separate sites chaotically settles down in the central region of kernels. Kernels meet. The Perinukleary space isn't expanded, the intermembrane space with a large number of a time is accurately looked through. Granular endoplasmic reticulum in hepatocytes it is accurately expressed, settles down whatnots in cytoplasm, forms contacts of a speroksisomama, often surrounds mitochondrions. Mitochondrions are large, roundish, separate tubular Christa have mest a dense matriks. Cytoplasm of average electronic density, is filled with glycogen sockets, fragments of a smooth endoplasmic reticulum meet.



**Fig. 2 - Fragment of hepatocyte of a pig of control group**  
**Symbols: N-kernel, M – mitochondrions, ER – endoplasmic reticulum, Ps – peroxysom, gl – glycogen.**

In the majority of hepatocytes of pigs after the combined influence of dioxine and T-2 of toxin in doses of 1/400 LD<sub>50</sub> and 2 PDK pathological processes of the nuclear device are noted: chromatin consolidation, swelling of perinukleary space, reduction of amount of a nuclear time. The cytoplasm enlightenment, existence very large a vacuole (fig. 3), sharp reduction of a granular endoplasmic reticulum, lack of a glycogen is registered. Mitochondrions are observed in the form of the roundish kompartiment filled with a flaked matriks, many of them lose one of two membranes.

In liver samples, hepatocytes in which are found, it is visualized: emergence of a melkoglobulyarny eukhromatin in a kernel, is a lot of nuclear time, swelling of tanks of a granular endoplasmic reticulum (fig. 4), increase in quantity and the size of peroxysom and mitochondrions. Mitochondrions at the same time have flaked matrix with single crosses. In cytoplasm the small vakuolization is observed, there is no glycogen, lipidic inclusions aren't found. Gialoplazma has flaked structure. Golgi's device is visualized extremely seldom. The liver is «target organ» of any influence of toxic substances. In a liver, there is not only a concentration of toxins, but also their active metabolization. In our researches hepatocytes which are at different stages of apoptosis are found.

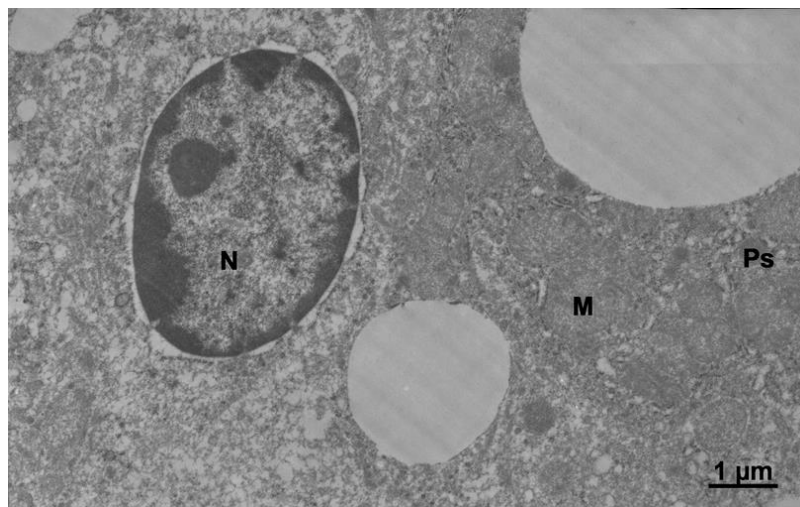
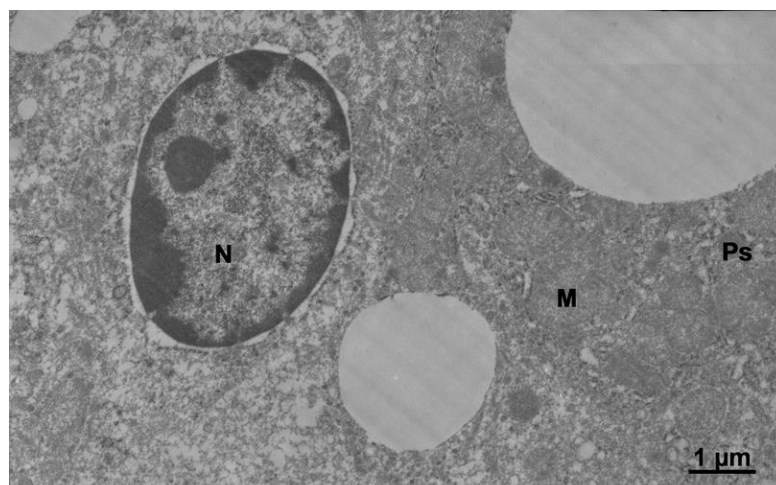
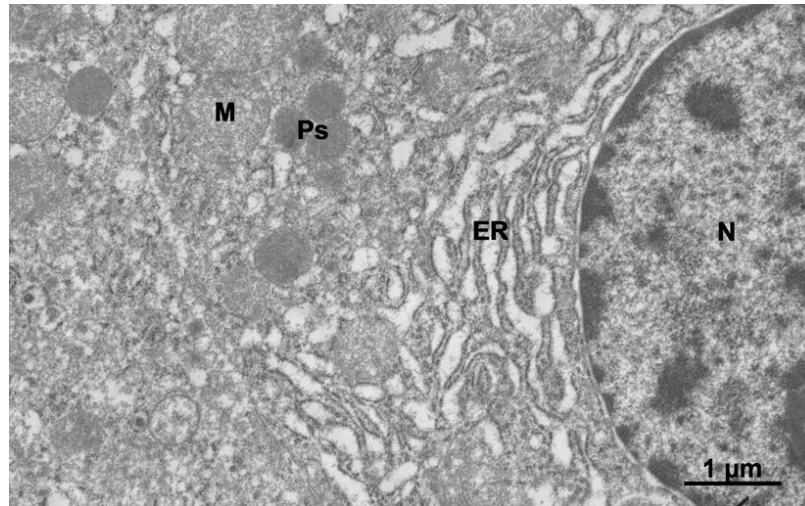


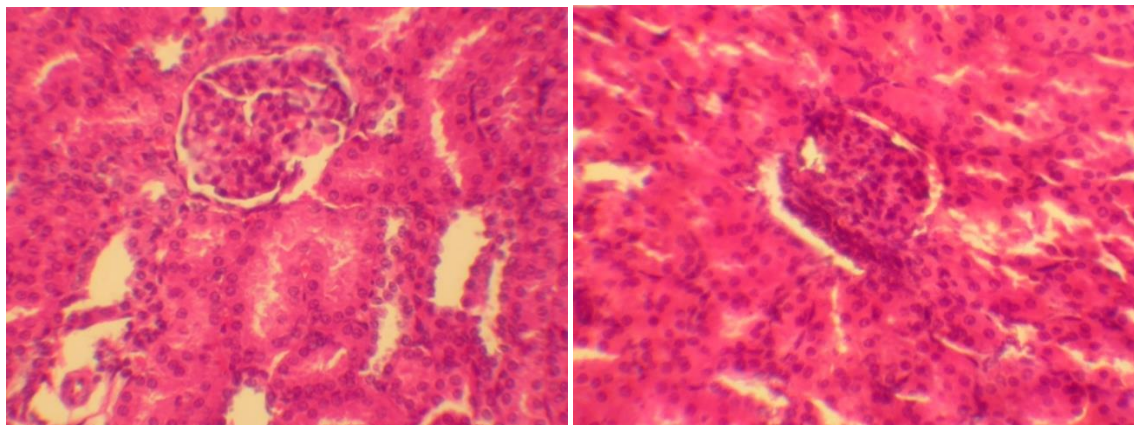
Fig. 3. Fragment of hepatocyte of the pig receiving combined dioxin in a dose 1/400 LD<sub>50</sub> and T-2 toxin in a dose of 2 PDK  
 Symbols: N – kernel, M – mitochondrions, ER – endoplasmic reticulum, Ps - peroxysom.





**Fig. 4 - Fragment of hepatocyte of the pig receiving combined dioxine in a dose 1/400 LD<sub>50</sub> and T-2 toxin in a dose of 2 PDK Symbols: N – kernel, M – mitochondrions, ER – endoplasmic reticulum, Ps - peroxysom.**

When studying histologic cuts of cortical substance of kidneys of control group of pigs, under a light microscope balls and wavy tubules are observed (fig. 5 a). In tests of cortical substance of kidneys of the pigs receiving combined dioxin in a dose 1/400 LD<sub>50</sub> and T-2 toxin in a dose of 2 PDK are noted dystrophic changes of an epithelium of wavy tubules of kidneys (in the form of proteinaceous dystrophy) with focal nekrobioza and a deskvamation of an epithelium (fig. 5 b).



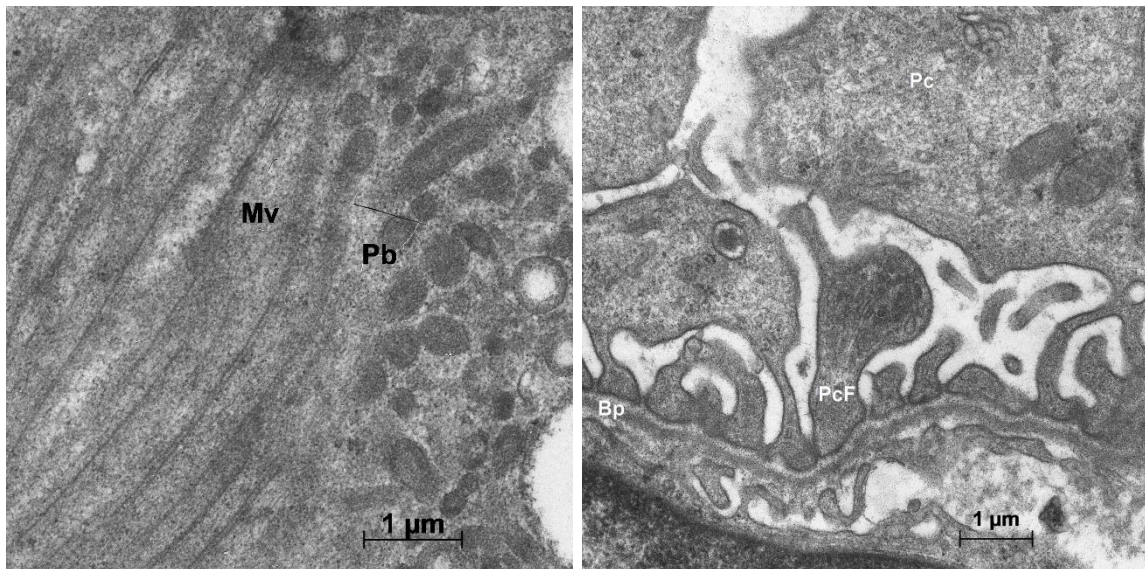
**Fig. 5 a, b - Sites of cortical substance of a kidney a) a control animal b) the pig receiving combined dioxin in a dose 1/400 LD<sub>50</sub> and T-2 toxin in a dose 2 PDK (lens 20)**

Epiteliotsita of proximal tubules of kidneys. A kernel of cages of proximal tubules of rounded shape with chromatin of average density. The condensed chromatin is localized on the periphery of a kernel. In a nuclear cover a nuclear time is looked through. On apikalny part of epitheliotsit there is a large number of microfibrs (fig. 6a). From the outer side of a mikrovilla electronic and dense material – glicocalics. Microfibrs considerably increase a surface of cellular membranes, strengthening thereby process of a reabsorption which happens in the epitheliotsitakh of a proximal tubule. The cytoplasm of epithelial saturated pinocytic vesicles and lysosomes may be contained in these amino acids, proteins, polysaccharides, hydrolases dehydrogenase, as occurs in the proximal reabsorption of amino acids, vitamins, glucose, and most of the water.

Filtrational barrier of kidney balls. On an ultrathin cut of a ball the congestion of capillaries of the podotsit surrounded with cages is looked through (fig. 6b). Everyone podotsit consists of three parts: cage "body", primary and secondary shoots. In the main part of a podotsit the kernel of rounded or irregular shape with chromatin of average density is visible. The condensed chromatin evenly settles down on all volume of a kernel. The kernel is surrounded with a nuclear cover with a nuclear time. Gialoplazmapodotsita fine-grained

with a low electronic density. In cytoplasm in small quantities mitochondrions of rounded shape meet a small amount a krist, certain canals of a rough endoplasmic retikulum, diktiosoma of the device of Golgi.

Legs of the next tsitopodiya form a slot-hole diaphragm through which there is a process of a filtration of plasma of blood, and formation of primary urine on a surface of a bazalny membrane of a capillary. Podocyte function as regulation of the extensibility of the glomerular capillary, preventing its excessive expansion under the influence of pressure transcapillary. Also limit the passing of negatively charged proteins which is carried out by an anion charge of a podotsit and a slot-hole diaphragm.

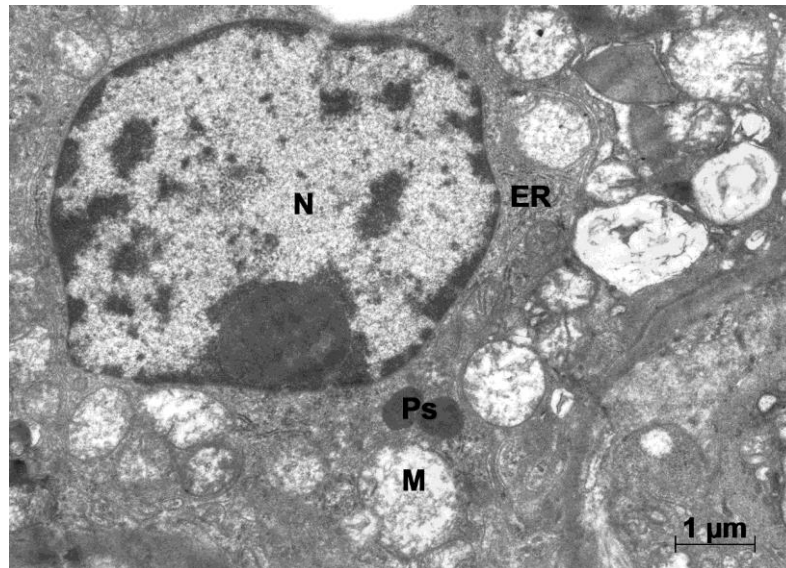


**Fig. 6 a, b - Sites of cells of cortical substance of a pig of control group:**  
**a) apikalny part of an epiteliotsit of a proximal tubule;**  
**b) site of a podotsit and filtrational barrier of a glomerula**  
**Symbols: Mv – microfibrils, Pb – pinocytotic bubbles,**  
**Bp – basalny plate, Pc - podotsita, PcF – leg of podotsit.**

Through a filtrational barrier of a kidney ball ultrafiltration process is carried out. It consists from the fenestrovannykh of capillaries, a bazalny plate an endoteliya and the slot-hole diaphragms which are formed between legs of podotsit. Cytoplasm an endoteliya average electronic density with melkovezikulyarny contents. On ultrathin cuts the three-layer bazalny membrane is looked through. Her external layers fine-grained electronic and light, and averages have electronic and dense contents. Average thickness of a bazalny plate filtrational a barrier of kidney balls of pigs has made 160-180 nanometers. It is noted accurately expressed filtrational cracks between tsitopodiya which densely adjoin to a bazalny plate.

Cages of a cortical layer of kidneys of pigs after the combined influence of dioxine and T-2 of toxin in doses of 1/400 LD<sub>50</sub> and 2 PDK. In the epiteliotsitakh a large number large and small is noted by a vacuole, some vacuoles have electronic and transparent contents surrounded with an unary membrane.

Polymorphism of mitochondrions is observed: roundish with brightened up matriksy and separate crosses; with a dense matriks and well developed lamellar crosses; mitochondrions with total loss a krist turning into vacuoles limited by a double membrane. One-membrane vacuoles meet fibrillyarno-globulyarny elements against electronic and transparent contents (fig. 7). In cytoplasm the peroxysom, separate tanks of granular EPS, the pinocytotnykh of bubbles is a lot of. It is normal of a microfibril. In kernels sites with melkogradulyarny chromatin are noted.



**Fig. 7 - Site of an epithelial cell of a proximal tubule of a pig skilled groups after the combined influence of dioxine and T-2 of toxin in doses of 1/400 LD<sub>50</sub> and 2 PDK**  
**Symbols: N – kernel, M – mitochondrions, ER – endoplasmic reticulum, Ps - peroxysom.**

A small amount of the condensed chromatin is chaotically distributed on the area of a kernel, some part holds pristenochny position. Kernels which central part is filled with contents homogeneous small-globulyarnym are observed and stands out against nuclear chromatin clearly. Insignificant increase in perinukleary space in cages of proximal tubules.

In lymphocytes of a capillary network of proximal tubules of kidneys the perinukleary space increases and chromatin of the nuclear device is sharply condensed.

In the podositakh change of a form of small tsitopodiya, disintegration of slot-hole diaphragms is noted. Loosening of a bazalny plate of a filtrational barrier of a glomerula.

### CONCLUSION

The combined impact of xenobiotics on an organism of pigs causes a complex of violations in the structural organization of hepatorenal system. Changes of microscopic and submicroscopic structures of the surveyed bodies can generally be considered as destructive, leading to development of apoptosis.

Histologic researches have revealed that at joint receipt (1/400 from LD<sub>50</sub>) and toxin T-2 (2 PDK) in a liver and kidneys develop in an organism of animals of dioxin dystrophic processes. Violation of ultrastructure of mitochondrions (increase in the sizes, flaked and bulked up matrices) confirms the granular dystrophy noted in histologic pictures.

Ultrastructural researches have shown that the combined poisoning of pigs with dioxin and T-2 with toxin in doses of 1/400 LD<sub>50</sub> and 2 PDK is characterized by essential violations of cellular structures in a liver and a cortical zone of kidneys: chromatin compaction, swelling of perinuclear space, reducing the number of nuclear pores, enlightenment cytoplasm vacuolization, a sharp decrease endoplasmic reticulum, the lack of glycogen, the destruction of mitochondrial cristae, changing the shape of small tsitopody and disintegration of slit diaphragms.

### REFERENCES

- [1] Kuznecov, A.F. Veterinarnaja mikologija // SPb.: Lan, 2001. – 416 s.
- [2] Osjanin K.A., Papunidi K.H., Saitov V.R., Sal'nikova M.M. Morfometricheskij analiz mitohondrij beloju pul'py selezhenki svinej i krolikov pri otravlenii toksikantami i na fone primenenija lekarstvennyh sredstv // Uchenye zapiski KGAVM, T. 217, Kazan. 2014. – S. 200–205.

- [3] Papunidi K.H., Ivanov A.V. i [dr.] Vlijanie dioksinov na okružhajushhuju sredu // Vtoroj sezid veterinarnyh farmakologov i toksikologov Rossii. Kazan 9–12 ijunja 2009 goda. Materialy sezida. – Kazan, 2009. – S. 25–31.
- [4] Sal'nikova M.M., Idijatov I.I., Saitov V.R., Kadikov I.R. Issledovanija ul'trastrukturny kletok kory golovnogo mozga svinej pri vozdeystvii dioksina, T-2 toksina i primenenii lekarstvennyh sredstv // Veterinarnyj vrach. –2015.–№ 9. –S.3–8.
- [5] Tutel'jan V.A., Kravchenko L.V. Mikotoksiny (medicinskie i biologicheskie aspekty) // M.: Medicina, AMN SSSR, 1985. – 319 s.
- [6] Uikli, B.S. Jelektronnaja mikroskopija dlja nachinajushhih // M.: Mir, 1975. – 324 s.
- [7] Fjodorov, L.A. Dioksiny kak jekologičeskaja opasnost': retrospektiva i perspektivy // M.: Nauka, 1993. – 266 s.
- [8] Alcock R.E., Sweetman A.J., Jones K.C. A congener specific PCDD/F emissions inventory for the UK: do current estimates account for the measured atmospheric burden // Chemosphere – 2001. – N. 43. – P. 183–194.
- [9] Bauer J. Disease and depression of productivity in raising swine caused by mycotoxins // TierarztlPrax Suppl. – 1988. V. 3. – P. 40–47.
- [10] Bechaux C., Zeilmaker M., Merlo M., Bokkers B., Crepet A. An integrative risk assessment approach for persistent chemicals: a case study on dioxins, furans and dioxin-like PCBs in France // RegulToxicolPharmacol. – 2014. V. 70. – N. 1 – P. 261–269.
- [11] Boverhof D.R., Tam E., Harney A.S., Crawford R.B., Kaminski N.E., Zacharewski T.R. 2,3,7,8-Tetrachlorodibenzo-p-dioxin induces suppressor of cytokine signaling 2 in murine B cells // MolPharmacol. – 2004. – V. 66. – N. 6. – P. 1662–1670.
- [12] Calkosinski I., Rosinczuk-Tonderys J., Bazan J., Dobrzynski M., Bronowicka-Szydelko A, Dzierzba K. Influence of dioxin intoxication on the human system and possibilities of limiting its negative effects on the environment and living organisms. Ann Agric Environ Med. 2014; 21(3):518-24.
- [13] Kovács, M. Effect of chronic T-2 toxin exposure in rabbit bucks, determination of the No Observed Adverse Effect Level (NOAEL) / M. Kovács, G. Tornyos, Z. Matics, M. Mézes, K. Balogh, V. Rajli, Z. Bloch-Bodnár, M. Rusvai, M. Mándoki, S. Cseh // AnimReprodSci. – 2013. – V. 137. – P. 245–252.
- [14] Mustafa A., Holladay S.D., Witonsky S., Zimmerman K., Reilly C.M., Sponenberg D.P., Weinstein D.A., Karpuzoglu E., Gogal R.M. Jr. Gestational exposure to 2,3,7,8-tetrachlorodibenzo-p-dioxin disrupts B-cell lymphopoiesis and exacerbates autoimmune disease in 24-week-old SNF1 mice // Toxicol Sci. – 2009. – N. 112 – N. 1. – P. 133–143.
- [15] Nygrea M., Hansson M., Sjoström M. et al. Development and validation of a method for determination of PCDDs and PCDFs in human blood plasma. A multivariate comparison of blood and adipose tissue levels between Vietnam veterans and controls // Chemosphere. – 1988. V. 17. – N.9. – P. 1663–1692.
- [16] Oswald, I.P. Immunotoxicity of mycotoxins / I.P. Oswald, C. Comera // Rev. med. vet. – 1998. – V. 149. – N 6. – P. 585–590.
- [17] Parent-Massin D. Haematotoxicity of trichothecenes. ToxicolLett // 2004 – V. 10. – N 153. – P. 75–81.
- [18] Poland, A. Knutson A. 2,3,7,8-Tetrachlorodibenzo-p-dioxin and related halogenated aromatic hydrocarbons: Examination of the mechanisms of toxicity // Annu. Rev. Pharmacol. Toxicol. – 1982. – V. 22. – P. 517–554.
- [19] Raju M.V., Devegowda G. Influence of esterified-glucomannan on performance and organ morphology, serum biochemistry and haematology in broilers exposed to individual and combined mycotoxicosis (aflatoxin, ochratoxin and T-2 toxin) // Br Poult Sci. – 2000/ – V. 41. N. 5. – P. 640–650.
- [20] Richard J.L. Some major mycotoxins and their mycotoxicoses – an overview // Int J Food Microbiol. – 2007. – V. 20. – N. 119. – P. 3–10.
- [21] Semenov E.I., Matrosova L.E., Tremasov M.Ya., Tarasova E.Yu., Kryuchkova M.A., Smolentsev S.Yu., Korosteleva V.P. Joint effect of the mycotoxins T-2 toxin, deoxynivalenol and zearalenone on the weaner pigs against a background of the infection load // Research Journal of Pharmaceutical, Biological and Chemical Sciences. 2016. T. 7. № 1. C. 1860-1868.
- [22] Sokolovic M., Garaj-Vrhovac V., Simpraga B. T-2 toxin: incidence and toxicity in poultry // Arh Hig Rada Toksikol. – 2008. – V. 59. – P. 43–52.