

Research Journal of Pharmaceutical, Biological and Chemical Sciences

Effect of the Antioxidant Power Integration of Vitamin E, Selenium and Fenugreek Seeds on Testis of Rat-Treated With Mercuric Chloride.

¹M Bassam Al-Salahy*, ¹Hanem S Abdel-Tawab, Ahmed Th. A. Ibrahim²
³Sobhy E Hassab El Naby, and ¹A Gubran AL-Shabahi.

¹Zoology Dept, Faculty of Science, Assiut University, Assiut, Egypt.

²Zoology Dept, Faculty of Science (New Valley), Assiut University, Assiut, Egypt.

³Zoology Dept, Faculty of Science, Menoufia University, Shibin el-Kom, Egypt.

ABSTRACT

This study was conducted to evaluate the integrative antioxidant potency of fenugreek seeds suspension powder (FSPS), vitamin E (Vit E), and sodium selenite (Se) against mercuric chloride toxicity (MC) induced oxidative stress in both erythrocytic lysate (EL) and testicular tissue (TT) in Albino male rats. MC was administered orally in drinking water (DW: 50 mg/L = 1/15 of LD₅₀). FSPS (100 g/L soaked for day), Se (2 mg/L) were administered in DW and vit E 150 (mg/100 g diet) mixed in the diet as. The rats were divided into six groups, ten rats each. The first group was control with normal diet and tap water. The second group, consider as positive control, DW containing MC. The third received Vit E (with diet) in addition to MC, the fourth group received MC + Se. The fifth one received MC and FSPS. Finally, the sixth group combination group (COMB group) received DW containing MC, Se in addition to Vit E. Glutathione, activities of catalase, superoxide dismutase, glutathione-S-transferase as antioxidants and lipid peroxidation level as oxidant were determined in both EL and TT. Besides, some hematological parameters were measured. H & E slides of testis were investigated. The results showed that all supplemented antioxidant nutrients have ameliorating effect on MC-induced toxicity in rats and the best improvement was obtained in COMB group. Also, all supplements improved histological alterations resulted from MC toxicity particularly spermatogenesis with the best result in COMB group. In conclusion, The result showed close relationship of oxidative damage between erythrocytes and testicular tissue in MC-treated rats.

Keywords: Fenugreek seeds; Vit E; Selenium; Testes, erythrocytes; rats; oxidative stress; histology.

**Corresponding author*

INTRODUCTION

Mercury is a well-known toxic heavy metal to animals as well as humans. It is widespread and distributed throughout the environment by countless processes such as volcanic activities, water movements and various biological activities. Mercury is one of the most common heavy metals, used for more than 3000 years in medicines (as disinfectants, vaccines), industries (fluorescent lamps, batteries, thermostats, thermometers), gold mining and therapeutically as a cathartic, diuretic, anti-inflammatory and in dental amalgams [1]. Industrial processes such as mining activities, combustion of fossil fuels, pesticides and medical wastes have also become significant contributors to the environmental distribution of mercury and its compounds [2]. Dental amalgams is widely used in Egypt probably exposing Egyptian people to daily trace doses of mercury which may form the long run serious symptoms. Also, many pesticides containing mercury are used in our country. Mercury manifests its toxicity by interacting with reactive oxygen species (ROS) and binding to thiol groups in several proteins such as glutathione (GSH) and many of the antioxidant enzymes [3]. It revealed that mercuric chloride (MC) is one of the most toxic forms of mercury because it easily forms organomercury complexes with proteins [4]. The authors added that there were degeneration of seminiferous tubules with partial loss of spermatogenic cells and degenerated epithelial cells into the lumen in mercury treated rats. Mercuric toxicity induces decrease mature spermatocytes, and edema in testis in rats [5]. Furthermore, testicular tissue is a major target for metal-induced oxidative damage because of its high content of polyunsaturated membrane lipids [6].

The mechanism of vit E restoration of liver injury in rats treated with MC, is through diminution of oxidative stress may lead to restoration of organ function in the victims of metal poisoning [7]. It is possible, however, that coadministration of HgCl_2 and vitamin E (Vit E) was protective due to impaired absorption of mercury in the presence of vit E in the gastrointestinal tract [8].

Sodium selenium (Se) is an essential element and well-establish antioxidant for all tissues of animals and human process [9,10]. It is reported that Se has anticarcinogenic, antimutagenic properties [11]. Se plays an important role in preventing hepatic cellular injury induced by hepatotoxic agent including arsenic [12]. Se is crucial in several enzymes with physiological antioxidant properties, including GSH-Px and thioredoxin [13]. Besides, the ability of Se to reduce Hg toxicity has been extensively investigated [14]. The interaction between mercury and Se in the body of mammals has been well reported [15]. Se has been proposed to sequentially bind to mercury and selenoprotein P in the bloodstream, to form a non-toxic complex [8,14].

There were many attempts for therapeutic effect of co-administration and combination of two or three nutrients or pure antioxidants, but these studies rarely focusing on fenugreek seeds (FS) which mostly used individually. Also, most of the combination among antioxidants used for curtailing metal toxicity consists of Se, Vit E and Vit C treatment of human erythrocytes with HgCl increased the levels of MDA in these cells and pretreatment with combination of Vit C+Vit E lowered LPO in HgCl_2 intoxicated blood cells [16]. Vit E and Se during the breeding season could improve semen characteristics and the overall reproductive performance of Ossimi rams [17]. Lower doses of vanadate could be used in combination with *Trigonella foenum graecum* seed powder to effectively counter diabetic alterations without any toxic effects [18]. Moreover, the antioxidant vit C and vit E exert significant protection against histological damage of testes induced by MC and provide a strong evidence for the beneficial role of antioxidant vit in prevention of mercury toxicity [19].

It was showed that supplementation of sodium selenite and/or vit E to mercury-treated rats declined lipid peroxidation, increased SOD, CAT and GPx activities along with milder histopathological lesions in testis tissues [20]. Se and/or vit E protect various tissues against damages induced by heavy metals [7, 14,20].

FS rich in bioactive antioxidant substances are used extensively as an important ingredient in daily food preparations and herbal formulations [21]. A recent study on the steroidal saponins of FS showed anti-inflammatory and anti-melanogenic activities [22]. FS possess antioxidant activity which increase the stability of RBC membranes through the formation of fatty complexes in the cell membranes that prevent or reduce the Free radicals effects [23]. The antioxidant activity could be correlated with the polyphenolic components present in the FS extract [24]. FS extract (0.4 g/kg body weight) led to an improvement in the histological and ultrastructural pictures of the testis together with reduction in the level of serum MDA and increase in the activities of serum SOD and CAT in mice treated with Cyclophosphamide-induced toxicity [10]. In addition, the

FS contain lysine and L-tryptophan rich proteins, mucilaginous fiber and other rare chemical constituents such as saponins, coumarin, fenugreekine, nicotinic acid, saponin, phytic acid, scopoletin and trigonelline, which are thought to account for many of its presumed therapeutic effects, may inhibit cholesterol absorption and thought to help lower sugar levels [25]. Trigonelline (TRIG), major alkaloid of FS, was reported to have a hypoglycemic effect in normal and in alloxan induced diabetes in mice and in rabbits [26]. In diabetic rat, *Trigonella foenum graecum* seed powder could counteract the alterations of oxidant antioxidants status in brains [18].

To our knowledge, there is no literature concerning study of antioxidant potency of FS individually or in combination with other antioxidants against MC toxicity on any organs including testes of rats. This study aims to evaluate the effect of vit E, Se and FS and their combination in rats-treated with sublethal dose of mercuric chloride. Also, this work aims to test the mixing between the different mechanisms of the antioxidant powers of these antioxidants and their integrative role looking for further mechanistic understand.

MATERIALS AND METHODS

Chemicals: sodium dodecyl sulfate, epinephrine, potassium dibasic, trichloroacetic acid, EDTA, DTNB (5,5-dithiobis-2-nitrobenzoic acid), 1-chloro-2-dinitrobenzene (CDNB), sodium selenite, vitamin E, hydrogen peroxide, sulfosalicylic acid, were purchased from Sigma-Aldrich (St Louis, MO, USA) and Fluka companies. All other chemicals were of highest quality available.

Fenugreek seed powder preparation:

After grinding of fenugreek seeds, the powder was soaked in water (aqueous suspension) for 24 h before using as drinking water (DW) by rats. The oral fenugreek aqueous extract (4% in drinking water) ameliorated the detrimental effects of CCl_4 in rats and corrected all examined biomarkers toward the control values [27]. Selenium (Se; 200 $\mu\text{g}/\text{kg}$ BW) could curtail lipid peroxidation in rats treated with diazinon [28]. Each rat consumed drinking water of average 10 ml/100g BW, so the dose of sodium selenite (Se) of 2 mg/ L drinking water was equivalent 200 $\mu\text{g}/\text{kg}$ BW.

Animals and experimental design:

Sixty Male Wister Albino rats weighting 120 - 200 g. were used. They were purchased from Assiut University Joint Animal Breeding Unit and were kept there for complete care during the period of the experiment. The animals were kept in a controlled light room with normal photoperiod (dark light cycle 12:12) at a temperature of 23 ± 2 C°. Mercuric chloride (MC: HgCl_2) was added to drinking water DW (50 mg/L) which calculated to be represent as 1/15 of LD_{50} (equivalent 75 mg/kg BW) according to previous finding [29]. Also, Selenium was added in DW as 2 mg/ L which nearly equivalent 200 $\mu\text{g}/\text{kg}$ Bw. aqueous fenugreek seed powder suspension FSPS was added as 100 g/L after soaking for day. These nutrients were available in DW *ad libitum*. Vit E was the only added in the normal diet 150 mg/100 g according to previous study [30]. Rats were divided into six groups, 10 each. The first group was control with normal diet and tap water. The second group, considered as positive control, DW *ad libitum* containing MC. The third, fourth, fifth and sixth groups received the same dose of MC in addition to the therapeutic antioxidants. The third group received MC + Vit E, the fourth group received MC + Se, Fifth one received MC + FSPS and sixth group received MC, Se, FSPS and vit E. The period of the experiment extended for 30 days. All experimental protocols held on animals were done according to regulations set by the Institutional Animal Care and approved by Assiut University.

Sample collection:

At the end of experiment 30 days (all period of the experiment), the animals were deprived of food and the drinking water become devoid of MC for one day, Animals were anesthetized with ether, then killed for collection of blood it divided into parts, one part was heparinized and the remainder non-heparinized. The non-heparinized blood was used for prepare hemolysate. Testes were excised immediately, washed in ice cold saline. A 10% homogenate of testes were prepared in phosphate buffer (0.1M, pH 7.2). Small pieces of histological study and were fixed in formal alcohols for 24 hour then dehydrated, cleared and embedded in paraffin. Samples were sectioned and stained with haematoxylin and eosin (H&E) [31]. Sections were selected

for photographed, (The sections were examined and photographed using an OPTIKA light microscope (OPTIKA ITAL. B500 Ti) with an attached digital photograph machine (OPTIKA 4083.B9) Microscope in Zoology. Dept., Faculty . Science., Assiut University Egypt.

Biochemical assays:

GSH was determined [32].as well as, SOD and CAT activities were measured [33, 34]. Glutathione S-transferase (GST) activity was determined with some modification [35]. Also, Lipid peroxidation (LPO) and total protein in the tissue homogenates were measured [36,37].

TSI : Testicular somatic index (TSI) =100 (weight of the two testes / rat body weight).

Hematological analysis:

Values of hemoglobin content (Hb), hematocrit (HCT), RBCs count, mean corpuscular hemoglobin (MCH) , mean corpuscular volume (MCV), mean corpuscular hemoglobin concentration (MCHC) and platelets count (PLT) were determined by using automated technical analyzer (Mindray Bc-2800) in veterinary medicine, Assiut university.

RESULTS

Testicular tissues:

The administration of mercuric chloride (MC) in rats led to significantly drop by -55.3% glutathione (tGSH). This was improved to -41.8, -36.2, -34.6 and -23.7% after supplementation of vit E, selenium (Se), fenugreek seed powder suspension (FSPS) and their combination group (COMB), compared with control values in MC-treated rats, respectively. Testicular antioxidants: Fig.1(a) shows that the administration of MC in rats led to significant decrease by - 59.1% catalase activity (tCAT) . This extent was improved to -39.1, - 25.6, -11.3 and -6.3% after supplementation of vit E, Se, FSPS and COMB compared with control values in MC-treated rats, respectively (Fig.1:b). Also, the administration of MC in rats led to significant decrease by - 53.9% superoxide dismutase activity (SOD). This alteration was improved by - 28.4, - 33.7, -36.3 and -23.7% after supplementation of vit E, Se, FSPS and COMB, compared with control values in MC-treated rats, respectively(Fig.1:c). Similarly, the administration of MC in rats led to significantly drop by - 47.8 % glutathione-s-transferase (tGST). This perturbation was improved to - 22.2, -11.2, -26.5 and -4.8 % after supplementation of vit E, Se, FSPS and COMB compared with control values in MC-treated rats, respectively (Fig.1:d).

Erythrocytic lysate:

Erythrocytic lysate antioxidants: The administration of MC in rats led to significant drops by - 62.4 and - 52.0 % CAT and SOD activities, respectively. These extents of disturbances were ameliorated to - 39.5, - 40.0, -27.9 and - 22.1% (eCAT) and - 30.2, -52.9, -33.4, -19.8 % (eSOD) after supplementation of vit E, Se, FSPS and COMB, compared with control values in MC-treated rats, respectively (Fig 2). Also, The administration of MC in rats led to significant decrease GSH and GST activities by -48.2 and -32.2 % , respectively. These extents of disturbances were ameliorated to - 16.9, -17.3, -22.5 and -23.3 % (eGSH) and - 9.7, -14.3, -13.2, + 4.0 % (eGST) after supplementation of vit E, Se, FSPS and COMB compared with control values in MC-treated rats, respectively (Fig 2) .

Testicular and erythrocytic lysate lipid peroxidation (tLPO and eLPO):

Testicular oxidative stress: Fig.3(a) shows a significant rise in tLPO by **85.4** %. This rise was improved with better extent after treatment with vit E by **6.40** followed by Se by **32.9**, followed by COMB by 34.2 % and later fenugreek by **41.9** % in MC-treated rats. Fig (3:b) shows significant rise in eLPO by 250.2 %. This rise was improved with better extent after treatment with COMB by 84.1 % followed by Se by 99.6 % followed by FSPS by 100.4 % and finally vit E by 111.7 % in MC-treated rats.

Fig (4) shows that there was significant low of testicular somatic index (TSI) in MC treated-rats, this was normalized after treatment with Se, FSPS and COPB compared with control. Fig (5).

The data obtained here shows that there was significant negative correlation between erythrocytic lipid peroxidation (eLPO) and each of tCAT, tSOD activities and tGSH(Fig 5:a,b and c). In turn, it was found a significant positive correlation between eLPO (erythrocytic) and testicular lipid peroxidation tLPO in MC treated group (Fig 5:d).

Hematology:

Table (1) shows that RBCs count, hematocrit (HCT), and blood hemoglobin (Hb) were significantly decreased in rat-treated with MC by -50.1, -33.2, -45.6%, respectively. Also these parameters mostly were relatively normalized (by -33.5, -28.5, -38.34, -19.95% in RBCs count, -25.7, -18.9, -26.8, -8.9% in HCT% and -20.7, -30.8, -29.4, -16.9 in Hb% in groups of MC+ VitE, MC+ Se, MC+ FSPS and MC+ COMB showing and the better restoration was in COMB group. Table 1. Shows significant rise in mean corpuscular volume (MCV), and mean corpuscular hemoglobin (MCH) by 14.1 and 11.2%, respectively accompanied with significant decrease in mean corpuscular concentration (MCHC) by -17.7% and platelets count by -51.0% in rats-treated with MC. MCHC and platelets count showed significant recovery in all therapeutical groups with the best result in MC+ Se (-0.4%) and in MC+ Vit E by 1.7%. Regarding MCV and MCH, there were relative significant improvement compared with control showing the best result in groups MC+ VitE by 2.7% and MC+ COMB by 7.4% respectively (table 1).

Table (1): Effect of vitamin E, selenium (Se), fenugreek (FSPS) and their combination on hematological parameters in rat-treated with mercuric chloride(MC).

Hematological parameters	Control	HgCl ₂ (M)	% Of change	M+ VitE	% Of change	M+ Se	% Of change	M+ F	% Of change	M+Combination	% Of change
Hb (g/dl)	14.38±0.88 ^A	7.83±0.29 ^D	-45.5	11.40±0.45 ^B	-20.7	9.95±1.27 ^C	-30.8	10.15±0.07 ^C	-29.4	11.95±0.47 ^B	-16.9
HCT (%)	38.25±1.40 ^A	25.55±0.87 ^D	-33.2	28.43±0.59 ^C	-25.7	31.00±0.62 ^B	-18.9	28.00±0.70 ^C	-26.8	34.85±0.60 ^A	-8.9
RBCs (10 ¹² /l)	10.55±0.26 ^A	5.27±0.33 ^E	-50.1	7.01±0.08 ^C	-33.5	7.55±0.49 ^C	-28.5	6.51±0.33 ^D	-38.34	8.45±0.16 ^B	-19.95
MCV (fl)	37.83±0.71 ^A	43.18±0.63 ^C	14.1	38.86±0.94 ^A	2.7	38.92±1.68 ^A	2.9	40.40±0.88 ^B	6.8	39.85±0.49 ^{AB}	5.5
MCH (pg)	13.59±0.62 ^A	15.12±1.03 ^C	11.2	15.80±0.73 ^C	16.2	14.77±0.48 ^B	8.8	15.79±0.94 ^C	16.2	14.58±0.53 ^B	7.4
MCHC (%)	37.51±1.48 ^A	30.86±1.79 ^B	-17.7	38.58±0.97 ^A	2.9	37.36±1.54 ^A	-0.4	36.69±1.24 ^A	-2.2	37.68±1.65 ^A	-10.2
PLT (x10 ⁹ /L)	575.75±18.21 ^A	282.00±10.78 ^B	-51.0	585.25±44.78 ^A	1.7	590.50±17.03 ^A	2.6	580.00±1.79 ^A	0.7	599.00±34.72 ^A	4.0

Haemoglobin (Hb) content, haematocrit (HCT) value, red-blood-cells (RBCs) count, mean corpuscular value (MCV), mean corpuscular haemoglobin (MCH), mean corpuscular haemoglobin concentration (MCHC) and Platelets count (PLT). Values in the same row with unlike descriptive superscript letters are significantly different (P < 0.05).

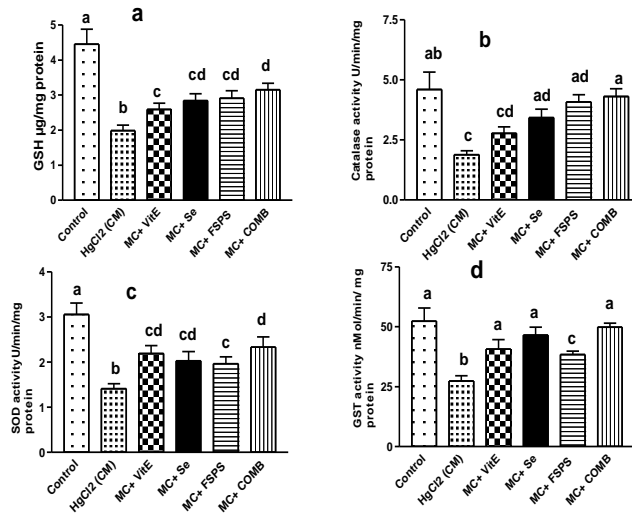


Fig.1 : Effect of vitamin E, selenium, fenugreek and their combination on testicular antioxidants glutathione (a), and enzymatic activities of Catalase CAT (b), superoxide dismutase SOD (c) and glutathione-s-transferase (d) in rat-treated with mercuric chloride (Se= selenium, FSP = fenugreek seed powder suspension and MC = mercuric chloride). Columns with different superscript are significantly different at P <0.05. n=10.

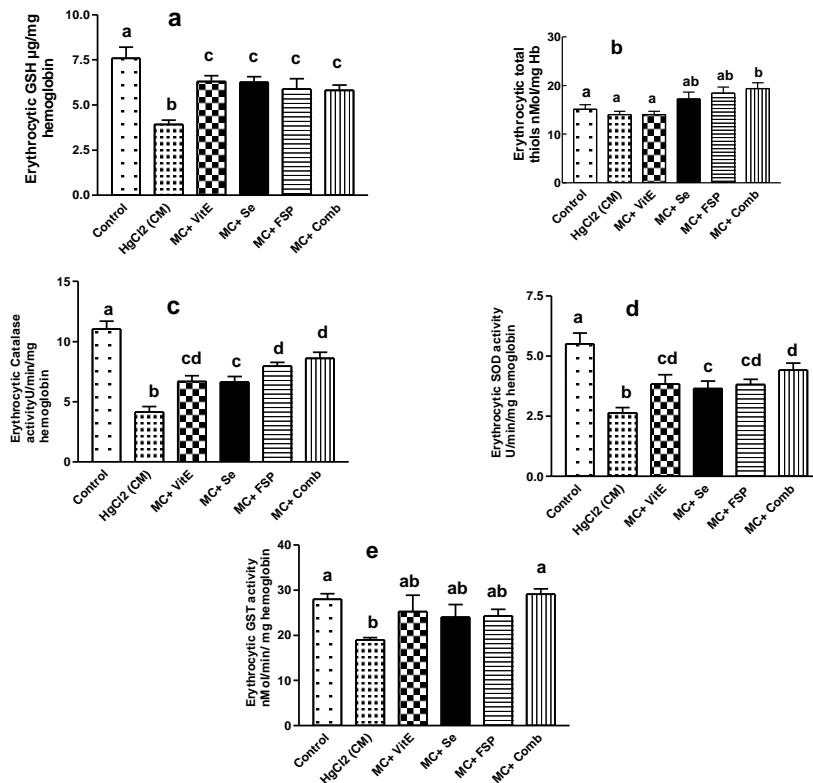


Fig.2 : Effect of vitamin E, selenium, fenugreek and their combination on erythrocytic hemolysate antioxidants contents of glutathione (a), total thiols (b) and enzymatic activities of Catalase CAT (c), superoxide dismutase SOD (d) and glutathione-s-transferase (e) in rat-treated with mercuric chloride (Se= selenium, FSP = fenugreek suspension powder and MC= mercuric chloride). Columns with different superscript are significantly different at P <0.05. n=10.

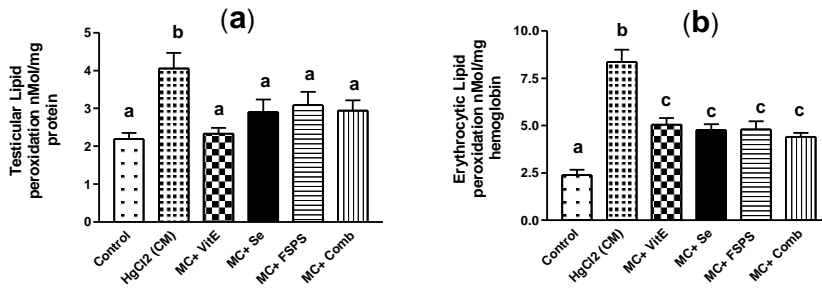


Fig.3: Effect of vitamin E, selenium, fenugreek and their combination on oxidative stress parameters: lipid peroxidation in testes (a) and in erythrocytic hemolysate (b) in rat-treated with mercuric chloride (Se= selenium, FSPS = fenugreek seed powder suspension and MC = mercuric chloride). Columns with different superscript are significantly different at P < 0.05. n=10.

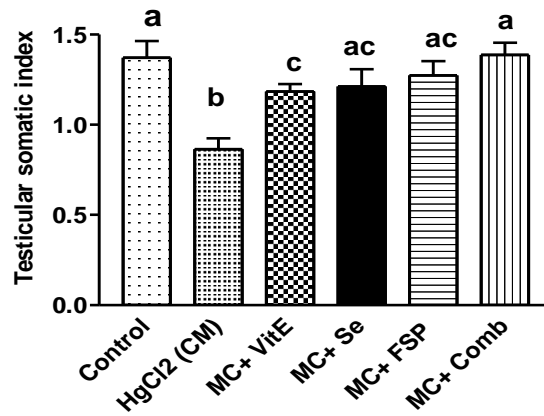


Fig.4: Effect of vitamin E, selenium, fenugreek and their combination on testicular somatic index in rat-treated with mercuric chloride MC (Se= selenium and FSPS = fenugreek suspension powder). Columns with different superscript are significantly different at P < 0.05. n=10.

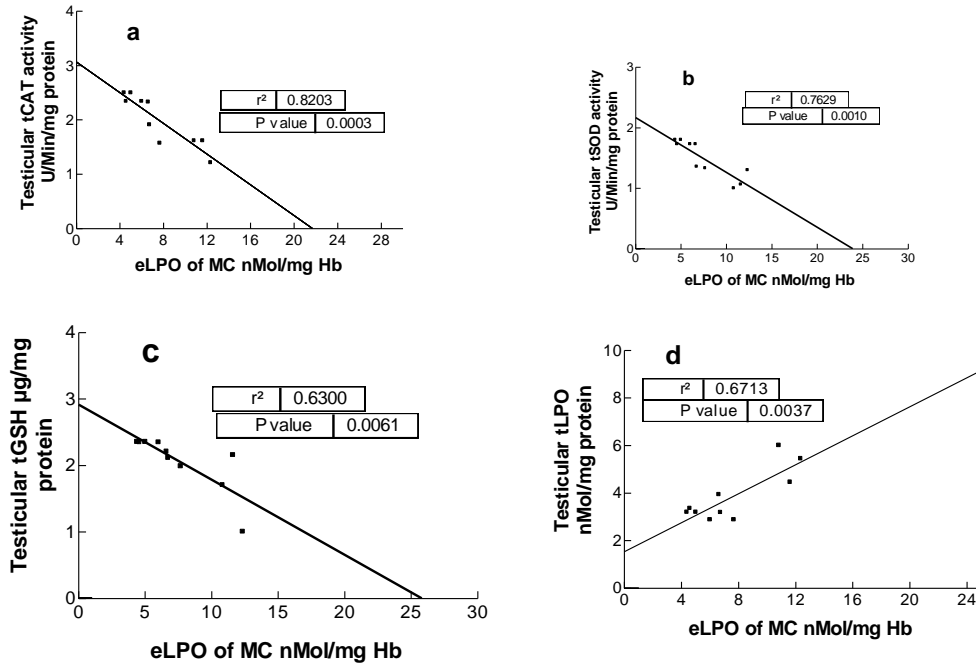
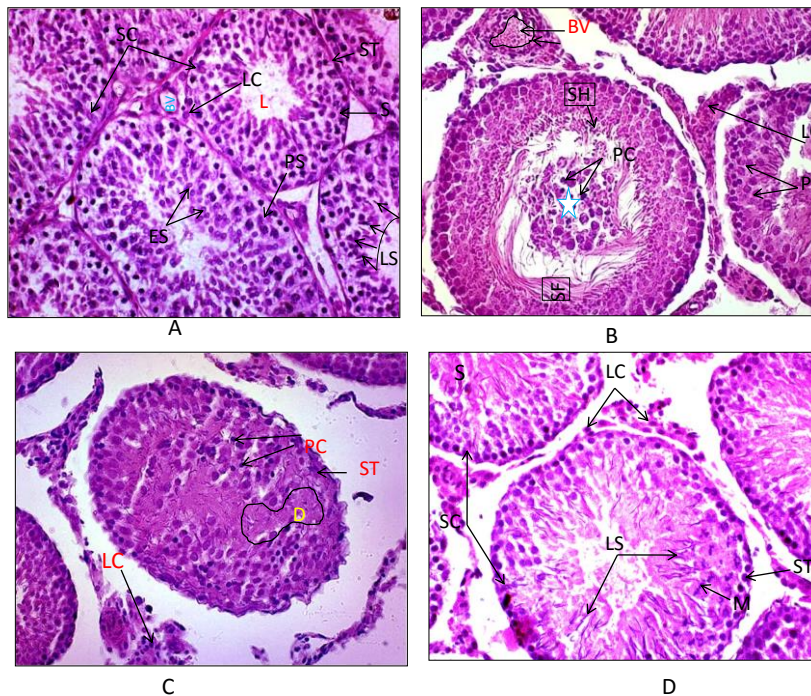


Fig. 5: Linear regression (R2) analysis (of paired data of mercuric chloride (MC treated rats), n = 10) of erythrocytic lipid peroxidation eLPO with testicular contents of catalase activity tCAT (A), superoxide dismutase activity tSOD (B), reduced glutathione tGSH (C) and lipid peroxidation tLPO (D).



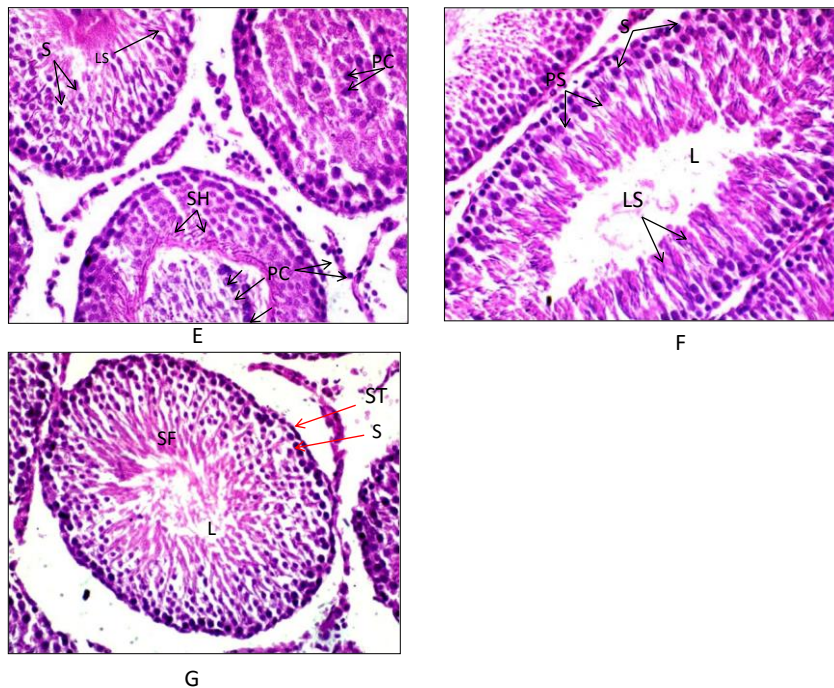


Fig (6). Sections of rat testes stained by H&E :Control group(G1) showed normal arrangements of spermatogenic stages in regular sominiferous tubules(A) . Positive control (G2)(B-D): Mercury treated groups showed Debris (stair) located in the center of seminiferous tubule surrounded by spermatozoa flagella(SF) Notice: Deeply stained pyknosed nuclei (PC), Intertubular debris (d) and congested blood vessel(BV)(B). Irregular rim of tubule (ST). Notice: Disorganization in arrangements of all stages of spermatogenesis and pyknosed nuclei (PC) Edema and necrosis (N)were seen(C). Marked degenerative changes in subscapular tubules.Notice the complete distortion of spermatogenic cells (D).Vit E +MC (G3) showed ,normal appearance of seminiferous tubules with all spermatogenic stages Notice: vacuolated basal lyaer(E) .Se+MC (G4) showed great diversity of seminiferotic tubulests changes ,regular spermatogenic stages, Other tubules showed both debris (stair)in their center ,or deformation and lost of most stages Note:Deeply stained nuclei(PC) were noticed (F).FSP+MC G5 revealed healthy spermatogenic stages. Notice: large number of waves of late spermatids (LS) and spermatozoa (SC)(G). COMB (G6) showed a great extent of amelioration of all spermatogenic stages were present and huge number of Luminal late permatids (LS)Notice :Vacuolated spermatogenic cells and edema were noticed(H).(X-400).

Results Histology

Fig.(6)Section of rat testes in experimental animals stained by H&E. Control groups, showed regular seminiferous tubules delimited by regular basement membrane and Presence of all stages of spermatogenesis . Germinative epithelium and all stages of spermatogonia were noticed. Primary and secondary spermatogonia in dividing stages ,early and late spermatids were shown. Interstitial ledge cells were located around intact blood vessels in interstitial tubular space (A). Positive control showed, irrgrular boundaries of seminiferous tubules, and large number of these tubules contains debris or detached cells in their lumina with deeply stained pyknotic nuclei surrounded by wavy circle of sperm flagella (B). Edema and atrophy of tubules ,disorganization of of spermatogenic stages , lost of regular stages of spermiogenesis and luminal mature sperm , necrotic area with deeply stained pyknotic nuclei were noticed (C) . Vit. E +MC showed regular rim of seminiferous tubules with development of all spermatogenic stages .Basal layer of epithelium were presents and few detached cells were noticed. Primary spermatocytes were arrest at metaphase, and their cytoplasm appeared highly basophilic . Intertubular connective tissues containing debris and Ledge cells with acidophilic cytoplasm and edema were observed(D). In Se + MC Showed regular appearance of some tubules containing, spermatogenic stages and luminal late spermatids and Vacuolated cytoplasm were observed. Few tubules contains debris in their lumen with deeply stained pyknotic nuclei and surrounded by degenerated spermiogenic stages. Disorganization& lost of spermatogenic stages were seen in other tubules .Intertubular edema were noticed (E). In (FSP + MC), showed maximum protection and restoration of the normal structure of the somniferous tubules with all spermatogenic stages were seen. Large number of late spermatids and spermatozoa were located at their Lumina (F) . COMB groups Showed intertubular edema and restoration of all spermatogenic stages up to their lumina were engorged by

spermatozoa, whole cells appears vacuolated. Widening of Intertubular space and connective tissues containing cells with deeply stained basophilic cytoplasm with few deeply stained nuclei were noticed(G).

DISCUSSION

Testicular tissues: mercury only showed a histological evidence of testicular damage, necrosis of seminiferous tubules and interstitial tissues, loss of spermatid and presence of multinucleated giant cells with sperm cell depletion [38]. The authors added that mercury chloride (MC) may led to high rate of infertility to the population. Mercury proved to be a potent oxidant in the category of environmental factors affecting bull spermatozoa [39]. Mercury exposure may render testis more susceptible to oxidative damage leading to their functional inactivation. Also, Increased separation between the vasculature and the tubules leads to edematous testes [4]. Proliferation activity was arrest in the spermatogonial cells of cadmium treated testis. While treatment with antioxidants leads to pronounced increase in proliferation activity [40]. The present study pointed out that MC significantly increased LPO in both testes and erythrocytic lysate (tLPO & eLPO). some studies [41] revealed that the activity of superoxide dismutase, glutathione peroxidase and glutathione reductase of sperm incubated in mercury decreased while thiobarbituric reactive substances levels and H_2O_2 generation were increased $HgCl_2$ exposure induced histopathological changes to the testis including morphological alterations of the seminiferous tubules, degeneration and dissociation of spermatogenic cells [42]. The authors added that $HgCl_2$ -induced inhibition in enzymatic activities of antioxidant biomarkers (SOD, CAT and GPx) back to control levels as well as it decreases the weight of accessory sex organs. The present study showed that the administration of MC in rats led to significant decrease in both erythrocytic lysate and testicular antioxidants: catalase activity (CAT), superoxide dismutase activity (SOD), glutathione-s-transferase (GST) and glutathione (GSH).

The current data revealed that MC toxicity led to a significant rise in tLPO by only 85% in testicular tissue while it enhanced eLPO by 250% in erythrocytic lysate, this may be associated with pronounced decrease in RBCs count by 50%. On the other hand, there were significant negative correlations between eLPO and levels of tGSH and activities of tCAT and tSOD, while it correlated positively with tLPO. This finding which accompanied with high percentage of eLPO may participate in magnification of the MC toxicity of different tissues including testes when peroxidated RBCs eventually exploded and leaving its oxidized contents near tissues. reactive oxygen species (ROS) in RBCs can diffuse to endothelial cells of adjoining blood vessels [43]. Also, the authors pointed out the transfer of RBC content of ROS to lung microvascular endothelium and transfer the inflammation. Exposure of rats to MC led to promote copper and zinc excretion [44]. Consequently, SOD depletion in both testes and erythrocytic lysate of the present study may be attributed to the lack of copper and zinc required for activity of SOD as well as the overproduction of ROS in response to the MC.

In addition, hyperglycemia induced by MC treatment (in previous study) [45] may play an important role in further production of ROS. MC ($HgCl_2$, 5 mg/kg) can cause pancreatic islets dysfunction and decreases insulin secretions [46]. It could suggest that the main cause of MC toxicity may be the accompanied persistent hyperglycemia and perturbation in electron transport chain of mitochondria leading to overproduction of reactive oxygen substances (ROS). Also, the pronounced decreases of blood hemoglobin by 45.5%, hematocrit by 33% and RBCs count by 50% observed in the present study, were probably associated with anemia relative poor oxygen in blood following by testicular tissue anoxia which may cause exacerbation of ROS release. This result suggests that MC toxicity associates with hypoxemia. This concept based on many studies. Some authors [46] showed that hypoxia increases production of mitochondrial ROS, which activate endothelial secretion of leukocyte adhesion receptors, thereby promoting the inflammatory response. In addition, the inorganic ionic mercury has great affinity for SH groups of biomolecules, such as glutathione (GSH) and sulfhydryl proteins, which may contribute to its toxicity [48]. This finding is in harmony with the significant drops in testicular total thiols and pronounced decrease in both eGSH and tGSH. RBCs contribute to hypoxia-induced inflammation [43]. The authors added that in hypoxia, red blood cells (RBCs) produces ROS that diffuse to endothelial cells of adjoining blood vessels. hyperglycemia leads to significant testicular dysfunction associated with decreased fertility potential [49]. hyperglycemia is an important factor which facilitates overproduction of oxygen free radicals [49]. Also, acute hyperglycemia induced by glucose infusion, significantly increased MDA release and depleted total glutathione in liver but not in muscle [51]. Moreover, Some studies [52] recorded Severe interstitial pneumonia and hypoxemia developed in human exposed to mercuric vapor. Histologically, the present study showed administration of MC led to irregular boundaries as well as degeneration of seminiferous tubules, large number of these tubules contains debris or detached

cells in their Lumina with pyknotic nuclei of sperm flagella, oedema and atrophy of tubules and disorganization of spermatogenic stages. This result was in harmony with the reported by other authors [4], who showed alteration in testes-histoarchitecture in MC-treated rats. Also, other studies showed testicular damage, necrosis of seminiferous tubules and interstitial tissues, loss of spermatid and presence of multinucleated giant cells with sperm cell depletion in MC-treated rats [38].

In the current work, testicular and hematological alterations resulted from MC toxicity were improved with different extents after administration of vit E, sodium selenite (Se), aqueous suspension of fenugreek seed powder (FS) and their combination. The present results showed that the effect of the combination of these nutrients was the best probably due to many reasons such as their integrative antioxidant powers (FS, Se and vit E), increasing of some enzyme activity (Se), curtailing hyperglycemia by FS and vit E, formation of non-toxic complex between mercury and Se, counteracting of MC-induced damaging effect on pancreas, in addition to obstruction of intestinal absorption of MC by vit E. Consequently, these supplementation may improve the insulin release, curtailing hyperglycemia leading to decrease the ROS generation and increase of antioxidants in both testes and erythrocytic lysate. This finding based on many studies. vit E is protective against mercuric toxicity due to impairment of intestinal absorption of mercury [36]. Major alkaloid of fenugreek seeds, was reported to have a hypoglycemic effect in diabetic mice and in rabbits [53]. FS can regenerate beta cells in pancreas; further studies would be done in mammals [53] and stimulates insulin secretion from pancreas [55]. Vit E impairs absorption of mercury in the gastrointestinal tract in addition to its antioxidant effects [8]. Also, Se reduces the absorption of mercury [9]. Vitamin C and vitamin E exert significant protection against histological damage of testes induced by mercury and provide a strong evidence for the beneficial role of antioxidant vitamins in prevention of mercury toxicity [19]. However, the present study showed that the combination of vit E with Se and FS was more efficient in counteracting the MC toxicity than each of these supplementations. In the present study, the severe decrease in the testicular somatic index in response to MC toxicity may be related to inhibitory effect of mercury on anabolic metabolism particularly protein synthesis. This based on the finding of some authors [56] who reported that heavy metals inhibits the synthesis of proteins and nucleic acids. Also, the probable damaging effect of MC on pancreas and insulin secretion may affect the testicular uptaking of required metabolites from circulation. Supporting biochemical hematological assays in the current study, the histological alteration showed that all deteriorated damage of testicular tissue such as edema, degeneration of seminiferous tubules, disturbances of spermatogenesis were relatively improved after treatments of FS, Se and vit E and COMB in MC-treated rats. The best response was in combination group as evidenced with other data of the present study. Thus, the effect of these combination led to restoration of all spermatogenic stages up to their lumina were engorged by spermatozoa, whole cells appears vacuolated. Widening of Intertubular space and connective tissues containing cells with deeply stained basophilic cytoplasm with few deeply stained nuclei were noticed. Up to the best of knowledge that there is no literature published used this combination of Vit E, Se and FS in recovery either histological or biochemical damage in erythrocytes and testis against metal toxicity.

We concluded that the main cause of MC toxicity in testes may be strongly associated with perturbation in mitochondrial electron transport chains. In addition, the severe erythrocytic peroxidation may participate in increasing the oxidative damage of testes in MC-treated rats. In addition, the combination of Vit E, Se, FS, is more efficient than that of each one alone and it has testicular and erythrocytic protective properties against heavy metal like mercuric chloride which induced nephrotoxicity and hepatotoxicity in experimental rats in biochemical and histopathological studies.

In conclusion, biochemical, histological and hematological alterations resulted from MC toxicity were improved with different extents after administration of vit E, Se, FS and their combination. The combination of these nutrients was the best probably due to many reasons such as their integrative antioxidant powers (FSPS, Se and vit E), increasing of some enzyme activity by Se, curtailing hyperglycemia by FS and vit E, formation of non-toxic complex between mercury and Se, counteracting MC toxicity on pancreas, in addition to obstruction of intestinal absorption of MC by vit E. Seminiferous tubules MC showed.

REFERENCES

- [1] Clarkson TW, Magos L, Myers G J. *N Engl J Med.* 2003; 349: 1731–1737.
- [2] Clarkson TW. *Crit Rev Clin Lab Sci.* 1997; 34: 369-403.
- [3] Zhao J Q, Wen YF, Bhadauria M, et al. *Ind J Exp Biol.* 2009; 47(4): 264-269.
- [4] Boujbiha MA, Hamdena K, Guermazib F, et al. *ReprToxicol.* 2009; 28: 81–89.

- [5] Sheikh T J, Patel BJ, Joshi DV, et al. *Vet World*. 2013; 6(8): 563-567, doi:10.5455/vetworld.
- [6] Acharya UR, Mishra M, Mishra I, et al. *Environ Toxicol Pharmacol*. 2004; 15: 53–59.
- [7] Rana SVS, Singh R, Verma S. *Ind J Exp Biol*. 1996; 34(2): 177-179.
- [8] Karaboduk H, Uzunhisarcikli M, Kalender Y. *Braz arch biol technol*. 2015; 58(2): 229-238.
- [9] Su L, Wabg M, Yin ST, et al. *Ecotoxicol Environ Saf*. 2008; 70: 483–489.
- [10] Sakr S A, Mahran H A, Abo-El-Yazid S M. *Toxicol Ind Health*. 2012; 28(3): 276-288.
- [11] Geyikoglu F, Türkez H. *Braz arch biol technol*. 2005; 48(6): 905-910.
- [12] Zhao X, Zhou W, Jian-jun L, et al. *Food Chem Toxicol*. 2013; 58: 1–7.
- [13] Xia L, Nordman T, Olsson J M, et al. *J Biol Chem* 2003; **278**: 2141-2146.
- [14] Perottoni J, Rodrigues OED, Paixão MW, et al. *Food Chem Toxicol*. 2004; 42: 17–28.
- [15] Jureša D, Blanuša M, Kostial K. *Toxicol Lett*. 2005; 155: 97-102.
- [16] Durak D, Kalender S, Uzun FG, et al. *J Biotechnol*. 2010; 9 (4): 488-495.
- [17] Mahmoud GB, Abdel-Raheem SM, Hussein HA. *Small Rumin Res*. 2013; 113:103-108.
- [18] Siddiqui MR, Taha A, Moorthy K, et al. *J Biosci*. 2005; 30(4): 483-490.
- [19] Sharma DN, Bhattacharya L. *Ind J Sci Res*. 2010; 1(2): 19-25.
- [20] Kalender S, Uzun FG, Demir F, Uzunhisarcikli M, et al. *Food Chem Toxicol*. 2013; 55: 456-462.
- [21] Khole S, Chatterjee S, Variyar P, et al. *J FUN Foods*. 2014; 6: 270 –279.
- [22] Kawabata T, Cui MY, Hasegawa T, et al. 2011; 77:705–710.
- [23] Taha AT. The role of vitamins A ,C and fenugreek seeds in lowering oxidative stress effect on physiological and reproductive performance of males broiler breeder. PhD. Thesis, College Agriculture and forestry, University of Mosul, Iraq 2008.
- [24] Bukhari SB, Bhangar M I, Memon S, et al. *Anal Environ Chem*. 2008; 9 (2): 78-83.
- [25] Sauvaire Y, Ribes G, Baccou JC, et al. *Lipids*. 1991; 26(3):191-197.
- [26] Shah SN, Bodhankar SL, Bhonde R, et al. *Pharmacol online*. 2006; 1: 65–82.
- [27] Al-Sultan S I, El-Bahr SM. *Int J Pharm*. 2015; 11: 43-49. DOI: 10.3923/ijp.2015.43.49.
- [28] El-Demerdash FM, Nasr HM. *J Trace Elem Med Biol*. 2014; 28: 89– 93.
- [29] Oriquat G A, Saleem TH, Naik RR, et al. *Jord J Biol Sci*. 2012; 5: 141-146.
- [30] Jaarin K, Gapor MT, Nafeeza MI, et al. *Int J Exp Pathol*. 2002; 83(6): 295–301.
- [31] Drury RA B, Wallington EA. *Carleton histological technique*. 5th ed, Oxford University Press. London, New York Toronto.1980; 1:653-661.
- [32] Ellman GL. *Arch Biochem Biophys*. 1959; 82: 70-77.
- [33] Misra HP, Fridovich I. *J Biol Chem*. 1972; 247: 3170-3175.
- [34] Beers B, Sizer I. *J Biochem*. 1952; 159: 133.
- [35] Habig WH, Pabst M J, Jakoby B. *J Biol. Chem*. 1974; 249 (22):7130–7139.
- [36] Ohkawa H, Ohishi N, Yagi N, et al. 1979; 95: 351-358.
- [37] Lowry, O. H, Rosenbrough, N.G., Farr, et al. *J Bio* 1951; 193: 265-275.
- [38] Asomugha AL, Ezejindu DN, Nwabekee PO. *J Preclin Pharmaceut Res*. 2015; 6(1): 1-6.
- [39] Arabi M. *Asian-Aust J Anim Sci*. 2006; 19(3): 335-340.
- [40] Koyuturk M, Yanardag R, Bolkent S, et al. *Environ Toxicol Pharmacol*. 2006; 21 235–240.
- [41] Rao M V, Sharma P S N. *Reprod Toxicol*. 2001; 15(6): 705–712.
- [42] El-Desoky G E, Bashandy SA, Alhazza IM, et al. *PLoS One*. 2013; 8(3): e59177.
- [43] Kiefimann R, Rifkind JM, Nagababu E, et al. *Blood*. 2008; 111: 5205-5214.
- [44] Liu X, Nordberg GF, Jin T. *BioMetals*. 1992; 5(1):17-22.
- [45] Al-Salahy MB, Abdel-Tawab HS, Hassab El Naby SE. et al. Eighth International Conference on Environment and Development in the Arab World., 2016; March. p: 51-75.
- [46] Chen K, Liu S, Su C, et al. *Int J Mol Sci*. 2012; 13: 12349-12366. doi:10.3390/ijms131012349.
- [47] Ichimura H, Parthasarathi K, Quadri S, et al. *J Clin Invest*. 2003; 111:691–699.
- [48] Hansen JM, Zhang H, Hones DP. *Free Radic Biol Med*. 2006; 565(40):138–145.
- [49] Cameron D F, Rountree J, Schultz R E, et al. *Am I Physiol*. 1990; 259 (6 Pt 1): E881-889.
- [50] Allen DA, Harwood S, Varagunam M, et al. *Faseb J*. 2003; 17: 908-911.
- [51] Ling PR, Mueller C, Smith R J, et al. *Metabolism*. 2003; 52(7): 868 – 874.
- [52] Hallee T J. *Am Rev Res Dis*. 1969; 99(3): 430- 436.
- [53] Marzouk M, Soliman AM, Omar TY. *Eur Rev Med Pharmacol Sci*. 2013;17(4):559-565.
- [54] Khalil EAM. *The Egypt J Hospit Med*. 2004; 15 :83 – 94.
- [55] Al-Habori M, Raman A. [Review]. *Phytother Res*. 1998; 12,233-242.
- [56] Dieuga G, Penni K. *Biol Chem, Mir, Moscow*. 1989; p. 512.