

Research Journal of Pharmaceutical, Biological and Chemical Sciences

A Comprehensive Study on the Diagnosis Methods of Neuroblastoma.

F Li Lly Hebsiba, V Meenal, and V Rajalakshmi*.

Department of Information Technology, Sathyabama University, Jeppiaar Nagar, Chennai-119. India

ABSTRACT

Detection methods of Neuroblastoma include radiologic testing, bone marrow analysis, physical examination, and measurement of urinary catecholamine metabolites. Immunocytologic analysis of blood for the detection of circulating tumor cells is a highly specific and sensitive method, which may prove useful in monitoring patients with neuroblastoma. By regular checkups and detecting the malignant tumor cells at earlier stage is one of the methods for curing. New clinical test like targeted therapy, vaccine therapy, and other drug therapy are available. Reverse transcriptase-polymerase chain reaction amplification of TH mRNA was a sensitive and specific method of detecting occult neuroblastoma cells .could be detected by this method in some BM samples that had no cytological evidence of tumor cells at the time of diagnosis.

Keywords: Neuroblastoma, tumour cells, Clinical tests, Symptoms

**Corresponding author*

INTRODUCTION

Neuroblastoma is a disease in which malignant (cancer) cells form in nerve tissue of the adrenal gland, neck, chest, or spinal cord. Neuroblastoma is sometimes caused by a gene mutation (change) passed from the parent to the child. It rarely happens in children older than 10 years of age. This type of cancer sometimes forms before birth. But it is usually found later, when the tumor begins to grow and cause symptoms. Neuroblastoma often does not cause early symptoms. Symptoms may not appear until the cancer has spread. **Neuroblastoma (NB)** is the most common extra cranial solid cancer in childhood and the most common cancer in infancy, with an incidence of about 650 cases per year in the U.S., and 100 cases per year in the UK. Nearly half of neuroblastoma cases occur in children younger than two years. It is a neuroendocrine tumor, arising from any neural crest element of the sympathetic nervous system (SNS). It most frequently originates in one of the adrenal glands, but can also develop in nerve tissues in the neck, chest, abdomen, or pelvis.

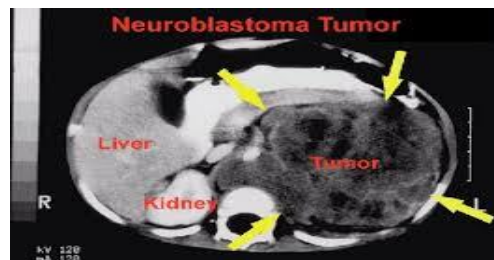


Figure 1: A tumor of Neuroblastoma

Neuroblastoma is one of the few human malignancies known to demonstrate spontaneous regression from an undifferentiated state to a completely benign cellular appearance. It is a disease exhibiting extreme heterogeneity, and is stratified into three risk categories: low, intermediate, and high risk. Low-risk disease is most common in infants and good outcomes are common with observation only or surgery, whereas high-risk disease is difficult to treat successfully even with the most intensive multi-modal therapies available. Esthesioneuroblastoma, also known as olfactory neuroblastoma, is believed to arise from the olfactory epithelium and its classification remains controversial. However, since it is not a sympathetic nervous system malignancy, esthesioneuroblastoma is a distinct clinical entity and is not to be confused with neuroblastoma. The great majority of cases are sporadic and non-familial. About 1–2% of cases run in families and have been linked to specific gene mutations. Familial neuroblastoma in some cases is caused by rare germline mutations in the anaplastic lymphoma kinase (ALK) gene. Germline mutations in the PHOX2A or KIF1B gene have been implicated in familial neuroblastoma as well. Neuroblastoma is also a feature of neurofibromatosis type 1 and the Beckwith-Wiedemann syndrome.

In a retrospective study of 28 patients with neuroblastoma, PET/CT was found to be superior to I-MIBG (iodine-131 metaiodobenzylguanidine) scintigraphy in detecting lymph node and bone/bone marrow lesions. Sensitivity, specificity, positive-predictive value, negative-predictive value and accuracy of F-FDG PET/CT were 100%, 60%, 92%, 100%, and 92.80%, respectively; and those of I-MIBG were 95.65%, 60%, 91.67%, 75%, and 89.20%, respectively. In these patients, PET/CT detected 107 lesions, and I-MIBG scintigraphy detected 74 lesions.

The children's less than 5 years are affected badly by neuroblastoma. A favorable tumor biology means there is a better chance of recovery. In some children who are 6 months old and younger, neuroblastoma may disappear without treatment. The child is closely watched for signs or symptoms of neuroblastoma. If signs or symptoms occur, treatment may be needed. The observed 3- and 5-year survival rates were lowest among adult patients (45.9% and 36.3%, respectively), whereas infants fared best with 86.0% 3-year and 84.6% 5-year overall survival. There was a steady decline in the incidence of adult neuroblastoma from 0.47 cases per million per year in 1973-1977 to 0.12 cases per million per year in 1998-2002. When the long-term adult neuroblastoma survival was examined in detail for 1-, 3-, 5-, 7-, and 10-year follow-up periods, there was continuous decrease in survival during the first 7 years after the diagnosis with subsequent stabilization for both observed (OS) and relative survival (RS) rates.

There was a notable trend towards improved outcome over the past three decades. The prognostic factors of neuroblastoma is shown below, the neuroblastoma is favorable for the children’s under 2 years old and it is unfavorable for the children’s above 2 years old. The neuroblastoma stages 1, 2 and 4s are favorable and the stages 3 and 4 are unfavorable.

Table 1: Results of Blood tests in various stages

TESTS	FAVORABLE	UNFAVORABLE
Ferritin	<143ng/ml	>143 ng/ml
NSE	<100	>100
DNA Index	>1.1	1
IP deletion	No ip deletion	Ip deletion

MYCN oncogene amplification within the tumor is a common finding in neuroblastoma. The degree of amplification shows a bimodal distribution: either 3- to 10-fold, or 100- to 300-fold. The presence of this mutation is highly correlated to advanced stages of disease. Duplicated segments of the LMO1 gene within neuroblastoma tumor cells have been shown to increase the risk of developing an aggressive form of the cancer. Neuroblastoma has been linked to copy-number variation within the NBPF10 gene, which results in the 1q21.1 deletion syndrome or 1q21.1 duplication syndrome. Several risk factors have been proposed and are the subject of ongoing research. Due to characteristic early onset many studies have focused on parental factors around conception and during gestation.

Factors investigated have included occupation (i.e. exposure to chemicals in specific industries), smoking, alcohol consumption, use of medicinal drugs during pregnancy and birth factors; however, results have been inconclusive. Between 20% and 50% of high-risk cases do not respond adequately to induction high-dose chemotherapy and are progressive or refractory. Relapse after completion of frontline therapy is also common. Further treatment is available in phase I and phase II clinical trials that test new agents and combinations of agents against neuroblastoma, but the outcome remains very poor for relapsed high-risk disease.

Most long-term survivors alive today had low or intermediate risk disease and milder courses of treatment compared to high-risk disease. The majority of survivors have long-term effects from the treatment. Survivors of intermediate and high-risk treatment often experience hearing loss. Growth reduction, thyroid function disorders, learning difficulties, and greater risk of secondary cancers affect survivors of high-risk disease. An estimated two of three survivors of childhood cancer will ultimately develop at least one chronic and sometimes life-threatening health problem within 20 to 30 years after the cancer diagnosis. **Neuroblastoma is a disease in which malignant (cancer) cells form in nerve tissue of the adrenal gland, neck, chest, or spinal cord.**

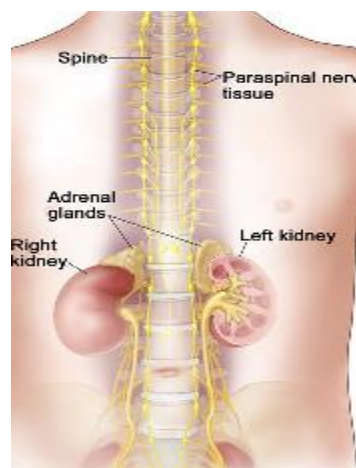


Figure 2: Regions affected by the tumor cells

STAGES

The process used to find out the extent or spread of cancer is called staging. The following stages are used for neuroblastoma:

Stage 1: the tumor that can be seen is completely removed during surgery

Stage 2: divided into stages 2A and 2B. 2A: the tumor that can be seen cannot be completely removed during surgery. 2B: the tumor that can be seen *may* be completely removed during surgery.

Stage 3: the tumor cannot be completely removed during surgery and has spread from one side of the body to the other side.

Stage 4: the tumor has spread to distant lymph nodes or other parts of the body.

Recurrent neuroblastoma is a cancer that has recurred (come back) after it has been treated. The cancer may come back in the same place or in other parts of the body.

RELATED WORKS

Neuroblastoma comprises 6–10% of all childhood cancers, and 15% of cancer deaths in children. The annual mortality rate is 10 per million children in the 0- to 4-year-old age group, and 4 per million in the 4- to 9-year old age group. The highest incidence is in the first year of life, and some cases are congenital. The age range is broad, including older children and adults, but only 10% of cases occur in people older than 5 years of age. A large European study reported less than 2% of over 4000 neuroblastoma cases were over 18 years old. By contrast, focus the past 20 years or more has been to intensify treatment for high-risk neuroblastoma. Chemotherapy induction variations, timing of surgery, stem cell transplant regimens, various delivery schemes for radiation, and use of monoclonal antibodies and retinoid to treat minimal residual disease continue to be examined. Recent phase III clinical trials with randomization have been carried out to answer these questions to improve survival of high-risk disease.

1. It occurs in one in 100,000 children and is diagnosed in 650 children each year in the United States. It accounts for 7-8% of children. It is an extracranial pediatric tumor and occurs where immature nerve cells become abnormal and multiply uncontrollably to form a tumor.
2. Once the diagnosis is made, staging, grading, and risk assessment are determined. Staging includes an MRI of the entire spine, a lumbar puncture for CSF cytology, and a postoperative MRI to assess for any residual tumor. The WHO has created a commonly used grading system. Risk assessment is based on age, degree of residual tumor, and evidence of spread of disease.
3. Nearly 6% of patients died more than 5 years after diagnosis, usually from disease recurrence or second malignant neoplasm. Neuroblastoma survivors were eight times more likely than the sibling cohort to have chronic health conditions, and by 20 years, nearly a third would develop neurological complications and about 8% each would develop endocrine, sensory, and musculoskeletal complications. Those who received multimodality therapy were more than twice as likely to develop a chronic health condition as those treated by surgery alone.
4. Esthesioneuroblastoma (ENB), also known as olfactory neuroblastoma, is a rare neoplasm originating from olfactory neuroepithelium. Approximately 1,000 cases have been identified. These tumors often display varying biologic activity ranging from indolent growth, with patient survival exceeding 20 years, to a highly aggressive neoplasm capable of rapid widespread metastasis, with survival limited to a few months.
5. Best response according to the International Neuroblastoma Response Criteria was analyzed in a two-stage sequential design. In the calculation of time to progressive disease, patients taken off study for stem cell transplant, refusal, or unrelated death were censored at that time.
6. Modern treatment strategies for neuroblastoma (NB) are tailored according to patient risk. However, it is not currently possible to compare the results of clinical studies conducted around the globe because the criteria used to define risk are not uniform.

A committee of international investigators with expertise in NB has worked during the past 2 years to develop a uniform International NB Risk Group (INRG) Classification System for pre-treatment stratification.

DIAGNOSIS OF NEUROBLASTOMA

Symptoms

The most common signs and symptoms of neuroblastoma are caused by the tumor pressing on nearby tissues as it grows or by cancer spreading to the bone. These and other signs and symptoms may be caused by neuroblastoma or by other conditions.

Check with your child's doctor if your child has any of the following:

- Lump in the abdomen, neck, or chest.
- Bulging eyes.
- Dark circles around the eyes ("black eyes").
- Bone pain.
- Swollen stomach and trouble breathing (in infants).
- Painless, bluish lumps under the skin (in infants).
- Weakness or paralysis (loss of ability to move a body part).
- Fever.
- Shortness of breath.
- Feeling tired.

Physical Test

An exam of the body to check general signs of health, including checking for signs of disease, such as lumps or anything else that seems unusual. A history of the patient's health habits and past illnesses and treatments will also be taken.

Blood Test

- **Hormone test:** A procedure in which a blood sample is checked to measure the amount of hormones released into the blood by the adrenal medulla. A higher than normal amount of the hormones dopamine and norepinephrine may be a sign of neuroblastoma.
- **Bone marrow aspiration and biopsy :** The removal of bone marrow, blood, and a small piece of bone by inserting a hollow needle into the hipbone or breastbone. A pathologist views the bone marrow, blood, and bone under a microscope to look for signs
- **X-ray :** An x-ray is a type of energy beam that can go through the body and onto film, making a picture of areas inside the body.
- **CT scan (CAT scan):** A procedure that makes a series of detailed pictures of areas inside the body, taken from different angles. The pictures are made by a computer linked to an x-ray machine. A dye may be injected into a vein or swallowed to help the organs or tissues show up more clearly. This procedure is also called computed tomography, computerized tomography, or computerized axial tomography.

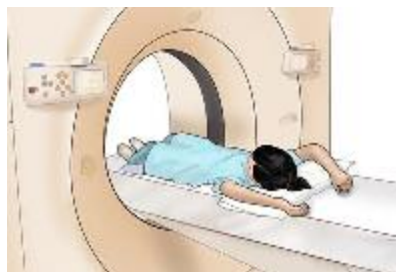

Figure 3: CT scan Procedure

- **MRI (magnetic resonance imaging) with gadolinium :** A procedure that uses a magnet, radio waves, and a computer to make a series of detailed pictures of areas inside the body. A substance called gadolinium is injected into a vein. The gadolinium collects around the cancer cells so they

show up brighter in the picture. This procedure is also called nuclear magnetic resonance imaging (NMRI). **ENLARGE**

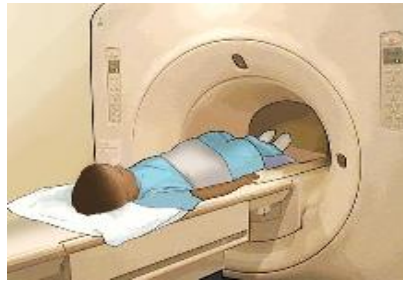

Figure 4: MRI Scan Procedure

- **Ultrasound exam:** A procedure in which high-energy sound waves (ultrasound) are bounced off internal tissues or organs and make echoes. The echoes form a picture of body tissues called a sonogram.

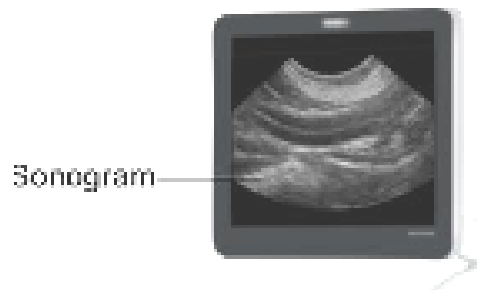


Figure 5: Sonogram Image

CONCLUSION

Thus a study of symptoms and methods for diagnosing neuroblastoma is produced. It includes the current information about diagnosing of neuroblastoma which is very crucial for the people to gain its knowledge. It is meant to inform and help patients, families, and caregivers. It does not give formal guidelines or recommendations for making decisions about health care [1-6].

REFERENCES

- [1] J. Foo and K. Leder, "Dynamics of cancer recurrence," *Annals of Applied Probability*, vol. 23, no. 4, pp. 1437–1468, 2013.
- [2] N. Bellomo and M. Delitala, "From the mathematical kinetic, and stochastic game theory to modelling mutations, onset, progression and immune competition of cancer cells," *Physics of Life Reviews*, vol. 5, no. 4, pp. 183–206, 2008.
- [3] C. Bianca and M. Delitala, "On the modelling of genetic mutations and immune system competition," *Computers & Mathematics with Applications*, vol. 61, no. 9, pp. 2362–2375, 2011.
- [4] C. Bianca and M. Pennisi, "Immune systems modelling by top-down and bottom-up approaches," *International Mathematical Forum*, vol. 7, no. 3, pp. 109–128, 2012.
- [5] C. Cattani and A. Ciancio, "Separable transition density in the hybrid model for tumor-immune system competition," *Computational and Mathematical Methods in Medicine*, vol. 2012, Article ID 610124, 6 pages, 2012.
- [6] C. Cattani, A. Ciancio, and A. d'Onofrio, "Metamodeling the learning-hiding competition between tumours and the immune system: a kinematic approach," *Mathematical and Computer Modelling*, vol. 52, no. 1-2, pp. 62–69, 2010.