

Research Journal of Pharmaceutical, Biological and Chemical Sciences

Effect of Lead Acetate on the Productivity of the Seminal Glands of Male Albino Rats.

Olga Sergeevna Shubina* and Natalia Anatolievna Dudenkova.

Federal State Budgetary Educational Institution of Higher Professional Education "M. E. Evseev Mordovian State Pedagogical Institute", Mordovia, 430007, Saransk, Studencheskaya Street, 11A

ABSTRACT

The effect of lead acetate on the morphology and productivity of the seminal glands of male albino rats was studied using histological, morphometric and statistical methods of research. Investigations were carried out using a digital microscope Axio Imager.M2 with AxioVision SE64 Rel. 4.8.3 and ZEN 2011 software for image analysis and the automatic cell counter Countess™. The data obtained indicate that the most vulnerable link in the process of gametogenesis is the stage of formation of spermatids and spermatozoa. It was also established that lead acetate reduces the productivity of the seminal glands, which displays itself in decreasing the concentration of spermatozoa in the suspension, as well as their viability.

Keywords. Seminal glands, epididymis, spermatogenesis, spermatozoa, lead acetate.

**Corresponding author*

INTRODUCTION

The development of approaches to issues of fertility control of human and animal requires in-depth knowledge of the process of differentiation of germ cells during spermatogenesis and the effect of various agents on its implementation [1, 2, 3]. Available data indicate that the male sex cells are sensitive to the damaging effect of the chemical nature, including the effects of heavy metals [4, 5, 6]. However, there is only a few experimental works studying the effect of lead salts on the seminal glands, and the available data are controversial [7, 8], and there is no information regarding the productivity of the seminal glands.

The objective of this study was to investigate the effect of lead acetate on morphological changes in the convoluted seminiferous tubules of the seminal glands of male albino rats, as well as their productivity.

TECHNIQUE

The adult male of outbred albino rats aged 18-20 months, weighing 200-250 g were used as a biological test object in the study in summer season. Total 50 animals used.

The animals were divided into two groups according to the objectives stated. The control group consisted of 20 male albino rats kept on a common regimen of vivarium. The experimental group consisted of 30 male albino rats receiving orally lead acetate $Pb(CH_3COO)_2 \cdot 3H_2O$ in a moderately toxic dose - 45 mg/kg/day (based on lead) for 7 days.

The animals were sacrificed by decapitation under anesthesia with ether chloroform (1:1) in compliance with the principles of humanity, specified in the directives of the European Community (86/609/EEC) and the Declaration of Helsinki, and in compliance with the requirements of rules of works using experimental animals.

For histological examination, the tissue samples of seminal glands were fixed in 10% neutral formalin solution. The fixed samples were dehydrated after rinsing in running water by placing them into alcohols of increasing concentration and embedding in paraffin by the established procedure. Histological cross-sections of seminal glands with thickness of 10-15 microns were prepared and stained with hematoxylin-eosin by the established procedure.

Histological preparations of seminal glands were studied using a digital microscope Axio Imager.M2 (ZEISS, Japan) with AxioVision SE64 Rel. 4.8.3 software for image analysis and ZEN 2011. The preparations were photographed using a digital camera AxioCam MRc5 (ZEISS, Japan). Resolution of images is 1300×1030 pixels.

The effect of lead acetate on the productivity of the seminal glands of male albino rats was assessed on the following parameters:

- 1) the total concentration of spermatozoa;
- 2) concentration of live spermatozoa;
- 3) concentration of dead spermatozoa;
- 4) viability of spermatozoa (live cells % of their total number) [9].

To determine the above parameters, the mixture of sperm suspension and saline (1:4) was stained with trypan blue on the object glass and examined by an automatic cell counter Countess™ (Invitrogen, USA) at a magnification of 100×2.3.

Trypan blue stains only the edges in live cells and an entire dead cell uniformly [10].

Spermatozoa suspension was prepared from the tail of the longitudinally dissected and fat-free epididymis.

To analyze the quality of the spermatozoa, a suspension swab was investigated using a digital microscope Axio Imager.M2 (ZEISS, Japan) at a magnification of 40×10, and the following morphometric parameters were further determined:

- 1) the area of the spermatozoid head;
- 2) the length of the spermatozoid tail;
- 3) the width of the spermatozoid neck.

The preparations were photographed using a digital camera AxioCam MRc5 (ZEISS, Japan) followed by image processing with Adobe Photoshop Elements 11.

Statistical processing of digital data was performed with FStat and Excel programs. Testing of statistical hypothesis was performed by Student t-test. In evaluating the statistical hypotheses the following significance levels were taken: $p \leq 0.05$

MAIN PART

Histological studies of seminal glands of male albino rats showed that their bulk is formed by round or elliptical convoluted seminiferous tubules. Convoluted seminiferous tubules are separated by a thin shell of interstitial connective tissue, with a thick wall of the seminiferous epithelium at different development stages thereunder.

The first outer layer of seminiferous epithelium in the convoluted seminiferous tubules consists of the spermatogonia with dark optically dense core and a thin rim of cytoplasm lying on the basement membrane.

Spermatocytes are located closer to the center of the tubule. These are large rounded cells with a large nucleus and a wide rim of cytoplasm.

The innermost layer of convoluted tubule consists of spermatids - small cells with bright nucleus lying in several rows. Early spermatids of round shape with a spherical nucleus are in the middle layers of the seminiferous epithelium. Late spermatids of elongated shape are in the layer adjacent to the lumen of the tubule. Some of late spermatids have a flagellum detected.

Already formed spermatozoa are found in some tubules. Their dark elongated heads are directed towards the periphery of the tubule, tails hang into the lumen of the tubule. Spermatozoa are located in the lumen of the convoluted seminiferous tubule in groups in an amount of 6-8 over the entire contour of the lumen (Fig. 1A).

A more detailed examination of spermatozoa with a digital microscope Axio Imager.M2 at a magnification of 40×10 revealed that their head is hook-shaped (Fig. 2A).

After sampling the suspension it was revealed that it has cloudy or milky white color, and a stiff consistency in the control group of animals. A high concentration of spermatozoa was observed in a mixture (Fig. 3A).

Histological studies of testes preparations of white rats after 7 days of exposure of lead acetate showed that convoluted tubules become of irregular polyhedral shape and are arranged at a distance from each other. The boundary between the spermatogenic epithelium and the lumen of the tubule is poorly visible and with indistinct contours. The proper shell of the tubules shows dissociation and disorganization of basement membranes.

Spermatogonia in convoluted seminiferous tubules are smaller in size, compared with the control group. Spermatocytes become oval, rarely spherical. Early and late oval spermatids do not differ virtually, their nuclei are moved to the center of the cell (Fig. 1B). A chaotic arrangement of spermatozoa was observed in the lumen of the tubule. Convoluted seminiferous tubules were found, with the lumen free of spermatozoa. The shape of the spermatozoid head changes. It becomes more rounded. Histological preparations show breakages of tails and agglutination of spermatozoa (Fig. 2B).

After 7 days of lead acetate exposure it was observed that the sperm suspension sampled becomes more transparent color and less viscous (Fig. 3B).

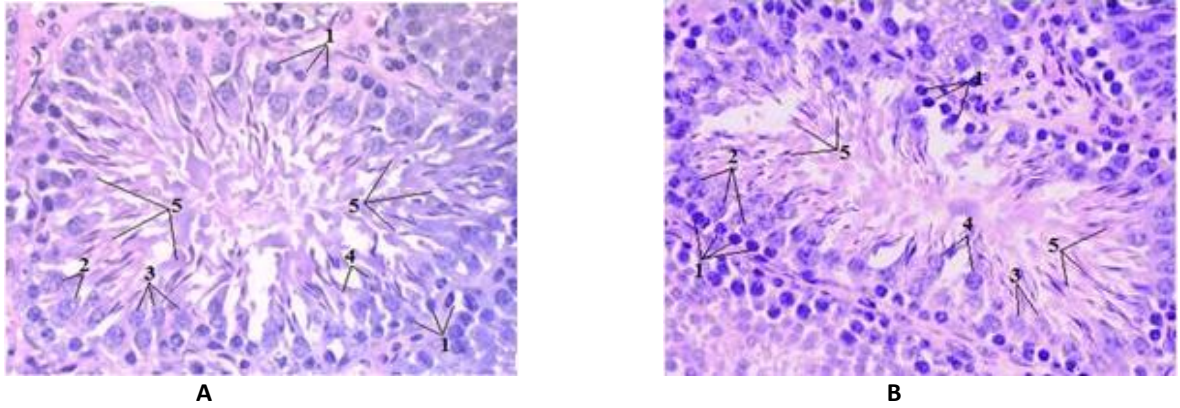


Figure 1: Convoluted seminiferous tubules. Haematoxylin and eosin stained. 40x10 magnification: A - control, B - experience 1 - spermatogonia, 2 - spermatocytes, 3 - early spermatids, 4 - late spermatids, 5 - spermatozoa.

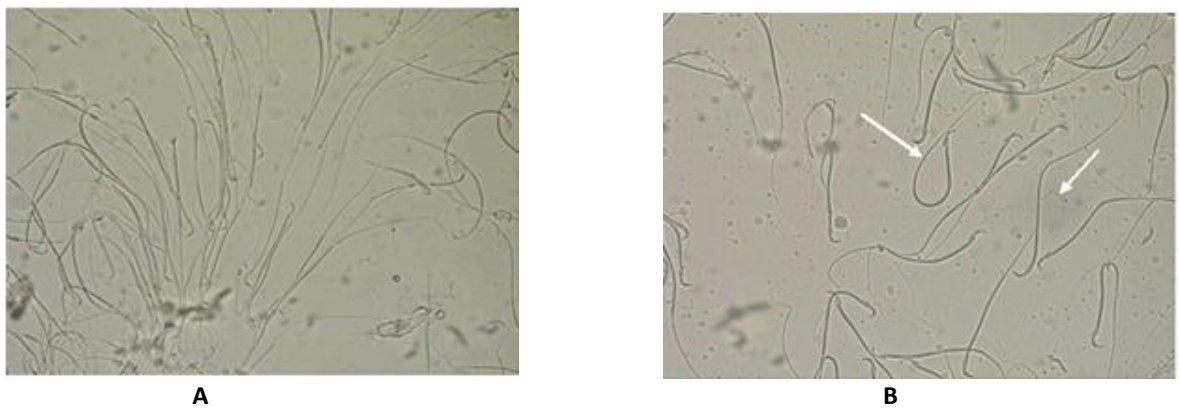


Figure 2: Spermatozoa of male albino rats. 40x10 magnification: A - control, B - experience (arrows show breakages of tails and agglutination of spermatozoa).




Figure 3: Spermatozoa of male albino rats under an automatic cell counter Countess™ (Invitrogen, USA). Trypan blue stained. 100x2.3 magnification: A - control, B - experience (arrows show breakages of tails and agglutination of spermatozoa).

The performed studies on sperm viability showed that animals in the experimental group have a decrease in the total concentration of spermatozoa in 1 ml of a suspension, live sperm concentration and their viability, compared to the control, respectively, by 50.63% ($R \leq 0.001$) 77.41% ($R \leq 0.001$) and 53.05% ($R \leq 0.001$). Simultaneously there is an increase of concentration of dead spermatozoa by 60.68% ($R \leq 0.001$) (Table 1, Fig. 4).

Table 1: Quantitative and qualitative characteristics of productivity of the seminal glands of male albino rats

No	Parameters	Control	Test
1	The total concentration of spermatozoa, $\times 10^7/\text{ml}$	7.96 \pm 0.45	3.93 \pm 0.11*
2	Concentration of live spermatozoa, $\times 10^7/\text{ml}$	7.04 \pm 0.12	1.59 \pm 0.09*
3	Concentration of dead spermatozoa, $\times 10^7/\text{ml}$	0.92 \pm 0.07	2.34 \pm 0.14*
4	Spermatozoa viability, %	88.62 \pm 3.48	35.57 \pm 2.75*

Note: * – $P \leq 0.001$ compared to control animals.

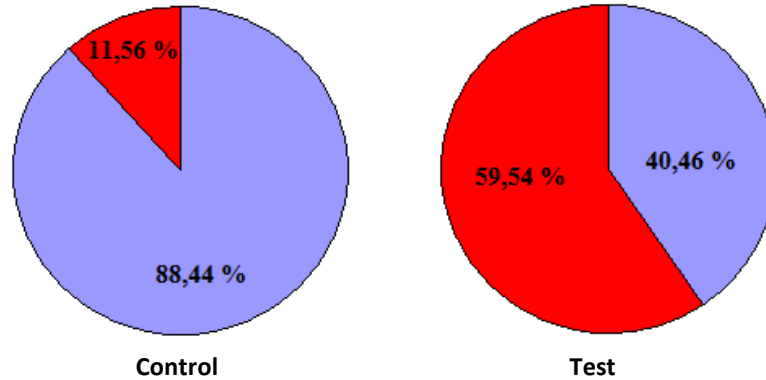


Figure 4: Percentage of spermatozoa in the suspension: ■ - live spermatozoa; ■ - dead spermatozoa.

The morphometric studies of spermatozoa showed that animals in the experimental group have a decrease in the area of spermatozoa head and width of its neck, compared to the control, respectively, by 16.99% ($R \leq 0.001$) and 13.60% ($R \leq 0.05$). At the same time, its tail part increases by 9.39% ($P \leq 0.05$) (Table 2).

Table 2: Morphometric parameters of spermatozoa of male albino rats.

No	Parameters	Control	Test
1	The area of the spermatozoid head, μm^2	185.86 \pm 6.49	158.86 \pm 2.93**
2	The length of the spermatozoid tail, μm	300.64 \pm 11.18	328.86 \pm 8.95*
3	The width of the spermatozoid neck, μm	6.60 \pm 0.68	5.81 \pm 0.28*

Note: * – $P \leq 0.05$ compared to control animals;

** – $P \leq 0.001$ compared to control animals.

CONCLUSION

The seminal glands of mature male rats, when exposed to lead acetate, show pathological changes, which manifest themselves in:

- Change of rounded shape of the convoluted seminiferous tubules to irregular polyhedral;
- Dissociation and disorganization of basement membranes in the proper shell of the tubules;
- Change of form of all kinds of spermatogenic cells;
- A chaotic arrangement of spermatozoa in the lumen of the tubule;
- Detection of convoluted seminiferous tubules with the lumen free of spermatozoa.
- Reduction of productivity of seminal glands, as well as the viability of spermatozoa;
- The absence of heads in the majority of spermatozoa;
- Agglutination of spermatozoa in the preparations.

ACKNOWLEDGEMENT

The work was supported by the Ministry of Education of the Russian Federation within the framework of the Strategic Development Program "Pedagogical Personnel for Innovative Russia" (a state task # 2 of 16.03.2013).

REFERENCES

- [1] Malyshki I.N., 2000. The dispersion analysis of vascular and testicular germ system integration in the pathogenesis of infertility. *Medical practice*, 3: 77-80.
- [2] Hess, R.A. and R.L. Franca, 2008. *Spermatogenesis and cycle of the seminiferous epithelium. Molecular mechanisms in spermatogenesis*. Austin. TX: Landes Bioscience / Springer Science, pp: 1-15.
- [3] Liu, H.X. W. H. Qin and G. R. Wang, 1995. Some altered concentrations of elements in semen of workers exposed to trinitrotoluene. *Occup Environ Med*, 52: 842-845.
- [4] Kulibin A.Yu., 2005. Cytogenetic changes in spermatogenic cells in SAMP1 mice (Senescence-accelerated mouse prone) under the influence of dipin - chemical mutagen. Abstracts of All-Russian Conference of Young Researchers "Physiology and Medicine", p. 61.
- [5] Dmitruha N.M., 2004. Experimental study of the effect of heavy metals (lead and cadmium) on non-specific resistance of the organism of white mice. *Modern Toxicology Problems*, 4: 27-30.
- [6] Arbuckle, T.E., S.M. Scharader and D. Cole, 1999. 2,4-Dichlorophenoxyacetic acid residues in semen of Ontario farmers. *Reprod Toxicol*, 13: 421-429.
- [7] Lutsky D.L., Vybornov S.V., Lutskaya A.M., Goncharova L.A. and Mahmoudov R.M., 2009. Influence of chemical factors on the male reproductive system (literature review). *Problems of reproduction*, 6: 48-64.
- [8] Shubina, O.S. and N.A. Dudenkova, 2013. Morphological and functional changes in seminal glands of albino rats exposed to lead acetate. *World Applied Sciences Journal*, 25(6): 886-891.
- [9] Sheiko L.D., 1998. The effect of small doses of hexavalent chromium on the reproduction of small mammals: Model experiment, Ural Scientific Research Institute of Maternity and Infancy, Ekaterinburg.
- [10] Nikolaev V.V., Stroev V.A. and Astrakhantsev A.F., 1993. Biochemical studies of seminal plasma in case of male infertility. *Urology and Nephrology*, 3: 33-36.