

# Research Journal of Pharmaceutical, Biological and Chemical Sciences

## Lateral Medullary Syndrome: A Rare Case of Vertebral Aplasia.

B Ramkumar\*<sup>1</sup>, and Sankara Narayanan<sup>2</sup>.

<sup>1</sup>Department of Anatomy, Sree Balaji Medical college, Bharath University, Chennai 44, Tamil Nadu, India.

<sup>2</sup>Department of Pharmacology, Sree Balaji Medical College, Bharath University, Chennai 44, Tamil Nadu, India.

### ABSTRACT

Lateral medullary syndrome, also known as wallenberg syndrome is characterized by series of neurological deficit due to occlusion of the vertebral artery or the posterior inferior cerebellar artery. The clinical signs and symptoms depend on the size of the stroke and the affected nerve tracts involving the lateral aspect of the medulla, cerebellum and the sympathetic fibers (le roux de 1999)<sup>1</sup>. 71 year old male patient with the complaints of early morning giddiness, domestic fall, paresthesia over left side of the body and imbalance while standing up. He is clinically and radiologically diagnosed as a case of lateral medullary syndrome due to right sided vertebral artery aplasia. We present this case of LMS due to vertebral artery aplasia which is a rare case of posterior circulation stroke and obtaining proper permission from the patient for scientific research purpose.

**Keywords:** Lateral medullary syndrome, trigeminal nerve, Horner syndrome.

*\*Corresponding author*

## INTRODUCTION

Gaspard Vieusseux of Geneva first described lateral medullary syndrome in 1810 and Adolf Wallenberg published the first case report in 1895 [2]. The lateral medullary syndrome is most often caused by occlusion of the vertebral artery or its branch posterior inferior cerebellar artery. The syndrome is characterized by sensory deficit and loss of pain and temperature over the contralateral side of the lesion and over the face on the ipsilateral side of the lesion. This is characteristic feature of lateral medullary syndrome. This is due to the involvement of spinothalamic tract and spinal trigeminal nucleus for the body and face respectively. Other features include 1) dysphagia and dysarthria due to involvement of nucleus ambiguus, 2) ataxia due to the involvement of the inferior cerebellar peduncle, 3) nystagmus, vertigo due to the involvement of vestibular nuclei, 4) features of Horner syndrome due to damage to the hypothalamo- spinal fibers.

## CASE REPORT

Mr. Rajan, 71 yr old male patient, smoker, occasional alcoholic, non-diabetic from tambaram was admitted on 04-07-2013 with the complaints of early morning giddiness and domestic fall and after that weakness over the left half of the body. On examination, patient was conscious, well oriented, co-operative, afebrile, speech-normal, no features of horner syndrome. Imbalance was present when patient was asked to walk a few steps. His vital signs showed elevated blood pressure of 190/110, random sugar was normal, Cardiorespiratory and abdomen system was normal, no carotid bruit, Central nervous system examination showed loss of pain and temperature over his left half of his body and loss of pain and temperature over right half of his face. Deep tendon reflex was elicited and normal. No tremors, dysdiadokinesia. On investigation; Mri revealed right sided vertebral artery aplasia and an infarct over right side of medulla, CXR: normal with hazy lung fields, ECG: normal. His lab results showed normal serum urea, creatinine and elevated triglyceride and serum cholesterol level. He was treated with heparin and long term warfarin with physical and occupational therapy.

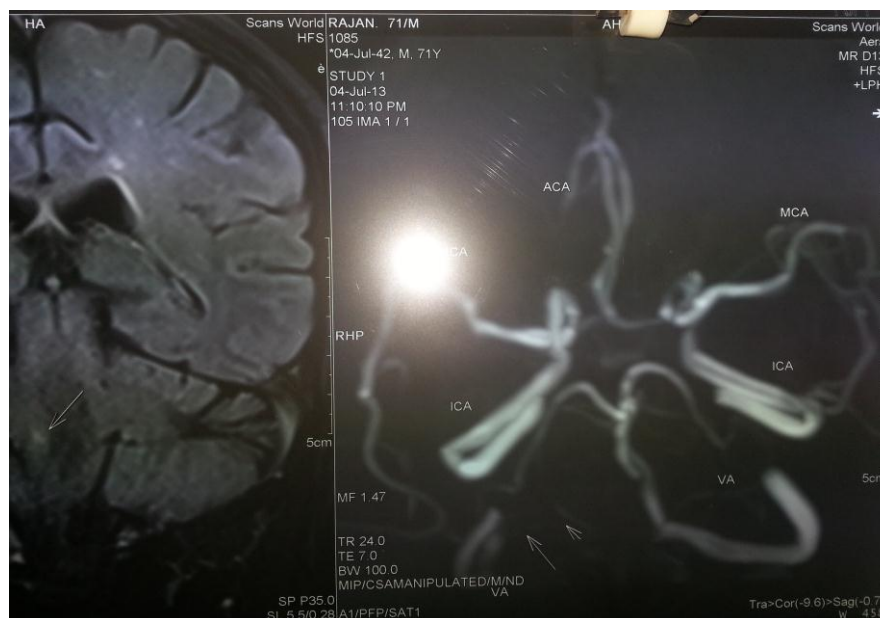


Figure showing right sided vertebral aplasia.

## DISCUSSION

Lateral medullary syndrome is commonly caused by thrombosis or emboli involving the vertebral or the posterior inferior cerebellar artery [3]. The region of medulla is tightly packed with multiple cranial nerve and nuclei like dorsal nucleus of vagus, spinal trigeminal nerve, vestibular nucleus. It is also packed with

ascending tracts like spinothalamic, spinocerebellar tract and descending tracts like hypothalamo spinal fibres [4]. Any involvement of vertebral artery or its branches will cause variety of signs and symptoms. The blood supply to medulla includes the vertebral artery, anterior spinal artery and the posterior inferior cerebellar artery [5]. According to Roger M.Lee et al, the anterior spinal artery supplies the medial aspect of the medulla, the PICA supplies the postero-lateral region and the main vertebral artery supplies the rest of the medulla. Wallenberg stated that lateral medullary syndrome occurs due to the infarction of the posterior inferior cerebellar artery. However recent studies states that involvement of vertebral artery is much greater when compared to PICA [6].

### CONCLUSION

Lateral medullary syndrome due to vertebral artery aplasia is rarely reported as an cause of posterior circulation stroke. Dysphagia is reported as the most common symptom with 51%-94% of all cases [7]. In this case, patient presented with paresthesia involving the contralateral side of the body and ipsilateral side of the face showing involvement of spinothalamic tract and spinal trigeminal nerve nucleus. Symptoms of imbalance, vertigo shows cerebellar involvement. But other signs and symptoms are absent in this patient. This patient had right sided vertebral aplasia which has not caused any symptoms until now which clearly states that the left side vertebral artery and the basilar artery would have compensated on the right side. CT scan/MRI of the brain can diagnose lateral medullary syndrome and angiography can depict abnormalities in the vascular system of the brain [8]. Most of the time, lateral medullary syndrome shows good prognosis [9] and after anti-clotting treatment patient can resume back to near normal life after life style modification along with medical and occupational therapy.

### REFERENCES

- [1] Le Roux D. 1999;3(1):16-20
- [2] Pearce JM. J Neurol 2000;68(5):570.
- [3] Zivin JA. Ischemic Cerebrovascular disease. In Goldman L, Schafer. 24<sup>th</sup> edition 2012.
- [4] Kim YK, Schulman S. Thromb Res 2009;123(6):810-21.
- [5] Thanvi B, Munshi SK, Dawson SL, Robinson TG. Postgrad Med J 2005;81(956):383-8.
- [6] Haldeman S, Kohlbeck FJ, McGregor M. Spine 1999;24(8):785-94.
- [7] Michaud TC. J Manipulative Physiol Ther 2002;25(7):472-83.
- [8] Fassett DR, Dailey AT, Vaccaro AR. J Spinal Disord Tech 2008;21(4):252-8.
- [9] Nelles G, Contois KA, Valente SL, Higgins JL, Jacobs DH, Kaplan JD, Pessin MS. Neurol 1998;50(5):1418-22.
- [10] Sacco RL, Freddo L, Bello JA, Odel JG, Onesti ST, Mohr JP. Arch Neurol 1993;50(6):609-14.