

# Research Journal of Pharmaceutical, Biological and Chemical Sciences

## Role of Immuno - Histochemical Stains in Prostatic Neoplasms: A Hospital Based Study.

**BO Parijatham, Ranjitham P, Poorana Priya P, and Subhashree AR.**

Department of Pathology, Sree Balaji Medical College and Hospital, Bharath University, #7, Works Road, New Colony Chromepet, Chennai – 600044, Tamil Nadu, India.

### ABSTRACT

Prostatic gland neoplasm increases with increasing age in male population. Currently Serum Prostate specific antigen is the most commonly used biomarker for the diagnosis and the prediction of prognosis of prostate cancer, however Serum PSA is not a cancer specific marker. Serum PSA levels are elevated in benign conditions such as benign nodular hyperplasia, Prostatitis in addition to prostatic carcinoma. p63 nuclear immuno stain is a sensitive and specific stain for prostate basal cells of benign glands with no staining evident in malignant glands. Hence, we attempted to evaluate the role of immunohistochemical stains in Prostatic neoplasms. 106 Trans urethral resection of Prostate (TURP) biopsy specimens received in the year 2013 at Department of Pathology, Sree Balaji medical college and hospital, Chennai were thoroughly examined and processed. The clinical data, Digital rectal examination and serum PSA levels were analyzed along with H&E sections of the specimens. Cases with Serum PSA >14ng/ml were taken up for p63 immuno staining and its expression was noted irrespective of their histopathological diagnosis. Among 106 cases, benign nodular hyperplasia was most commonly encountered (88.67%) followed by carcinoma of prostate 11 cases (10.4%). p63 immuno staining was carried out in 20cases. Out of those 20 cases, 9 showed p63 positivity in benign nodular hyperplasia and low-grade prostate intraepithelial neoplasia and 11 cases of adenocarcinoma prostate showed p63 negativity. p63 is a nuclear stain co-expressed with 34  $\beta$ E12 in prostate basal cells, so patients with elevated serum PSA (Prostate Specific Antigen) levels must undergo a biopsy to confirm or exclude the presence of prostate cancer. The availability of prostate cancer and associated basal cell markers has been a valuable addition to diagnostic surgical pathology.

**Keywords:** TURP biopsies, Serum PSA, p63 immunostain.

*\*Corresponding author*

## INTRODUCTION

Prostate gland occupies center stage in the lives of many elderly males. Incidence of prostatic disease, Benign Nodular Hyperplasia (BNH) and carcinoma prostate increases with age [1,2]. A recent American Urological Association (AUA) guidelines (2010) suggest an increase in the incidence of Benign Nodular Hyperplasia worldwide and predicts by the age of 60yrs, more than 50% of men will have microscopic evidence of disease [1] few studies conducted in India suggests BNH as the most common pathological condition with an incidence of 92.97%(2,3) Prostatic carcinoma is more common in India compared to other Asian Countries and its incidence is increasing by 3.5% every year due to the westernization [3]. The combination of Digital rectal examination (DRE), Trans rectal Ultra sonogram, Serum Prostate Specific Antigen (S.PSA) estimation, supplemented with biopsy procedures represents a powerful diagnostic tool in the diagnosis of various prostatic lesions [4]. Histo-pathological examination of prostatic biopsy remains the gold standard for diagnosing all lesions including benign and malignant conditions. The unrelenting challenge encountered when differentiating limited-volume prostate carcinoma and sometimes subtle variants from its many morphologic mimics has increased the use of ancillary immunohistochemistry in prostate biopsies., 34  $\beta$ E12 a high molecular weight cytokeratin(HMWK)is a cytoplasmic basal cell marker.p63 a nuclear stain is co-expressed with 34  $\beta$ E12 in normal prostate basal cells and benign glands.

## MATERIALS AND METHODS

During the 1 year period, 106 TURP specimens were received in the department of Pathology, Sree Balaji Medical college and hospital, Bharath university. Relevant clinical data including age, the presenting complaints, digital rectal examination and Serum PSA values were recorded. Every tissue was carefully examined. Fixation was done by neutral buffered 10% formalin for 12 hrs and then the specimen was submitted for processing. After processing, 4-5 $\mu$  sections were cut and Hematoxylin and Eosin staining was done. Every slide was examined thoroughly for the presence of benign, premalignant and malignant features. The cases of prostatic adenocarcinoma were graded using Gleason microscopic grading. Other special stains like Alcian blue pH 1, Periodic Acid Schiff (PAS) were performed wherever necessary. Immuno staining with basal cell marker-p63 was done for 20 cases in whom Serum PSA>14ng/ml and their immuno expression was noted. The clinical and histological data so obtained were analyzed.

## RESULTS

Among the 106 cases of prostatic biopsies, there were 94(88.61%) cases of Benign Nodular Hyperplasia, 1(0.94%) case of low grade Prostatic Intraepithelial Neoplasia and 11(10.4%) cases of Carcinoma Prostate observed. Benign Nodular Hyperplasia (BNH) was the most common histological lesion encountered (94cases – 88.61%) (Table 1) with maximum incidence in VI decade. Carcinoma of Prostate was the second most common type of lesion encountered (11 cases – 10.4%).The mean age and median age of the patients with benign prostatic disorder was 62.6 and 62.5 years , whereas the mean age and median age of patients with malignant neoplasm of prostate was 70.5 and 70 years.Fig 1 shows the comparison of p63 immunostaining with serum PSA values of >14 ng / dl. All cases of Adenocarcinoma of Prostate show an increases serum PSA levels, but, 12 out of 94 cases of BNH also PSA positivity, thus showing a low specificity for prostatic malignancy. All eleven cases of Adeno carcinoma shows negativity of immunostaining for p63 . Eight out of 12 high PSA BNH show positivity for p63.

## DISCUSSION

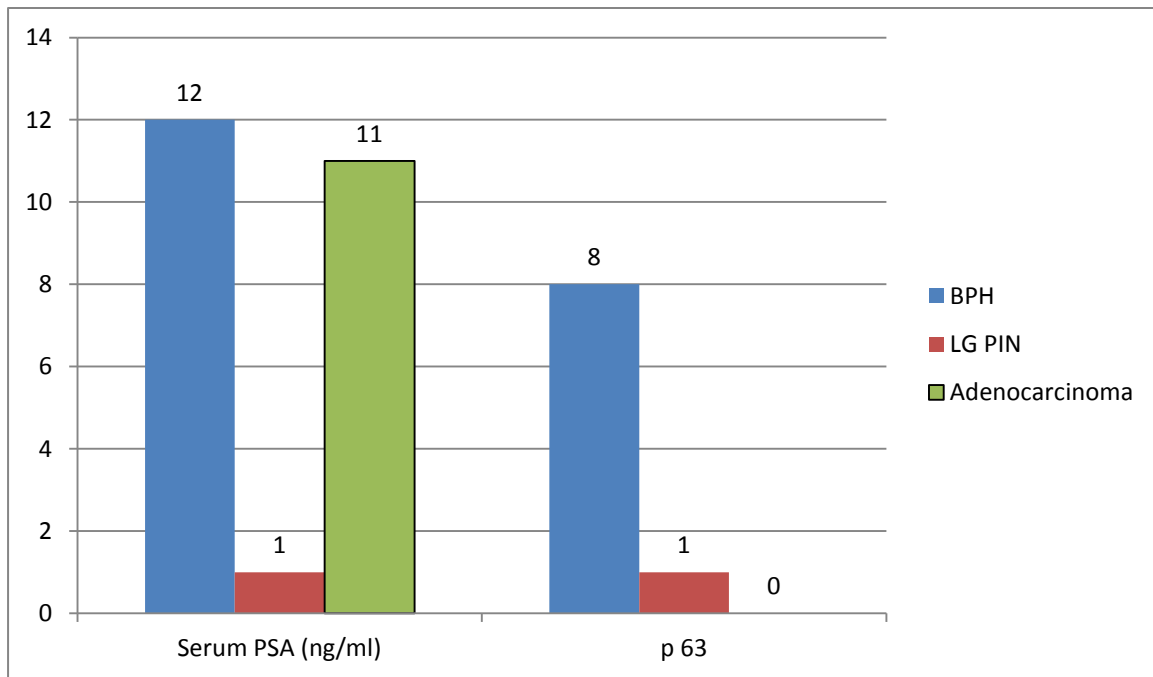
Benign nodular hyperplasia and Carcinoma of the prostate are more frequent after 40 years of age. In India the incidence of benign prostatic hyperplasia in all prostatic lesions is estimated to be around 93% [5]. Incidence of prostatic carcinoma is around 8/100,000 persons [5]. Our study also showed an incidence of 94% of BNH of all the Prostatic neoplasms which is in accordance with other studies(5). Screening for Prostatic carcinoma is usually done by serum PSA testing [6,7]. Role of Immuno staining with p63 gained awareness when studies proved that p63 immunostaining was diagnostically reliable and is sensitive in identifying basal cells in prostatic needle biopsies and TURP specimens [6]. Antibodies against intermediate sized keratin filaments cytokeratin 5 and 6 (CK 5/6) are also excellent markers of prostatic basal cells [7-10] but cautery artifact can impair the ability to detect high molecular weight cytokeratinstaining and so p63 appears superior [11,12].

Our study evaluated p63 expression in prostatic neoplasm in comparison with elevated serum PSA levels. We observed p63 to be specific in differentiating benign from malignant lesions of Prostate in comparison to the serum PSA levels (Fig 1). Fig 2 and Fig 3 show H&E pictures of Benign Prostatic Hyperplasia and Prostatic Adeno carcinoma. Fig 4,5 and 6 show immuno staining with p63 in BNH, PIN and in Prostatic Adeno carcinoma.

**Table 1: Incidence of Prostatic Neoplasms**

S.No.	Type of Lesions	Total Number (%)
1	Total number of Prostatic biopsies	106
2	Benign Nodular hyperplasia	94 (88.67%)
3	Prostatic Intraepithelial Neoplasia (PIN)	1 (0.94%)
4	Carcinoma of Prostate	11(10.4%)

**Figure 1: Serum PSA levels of >14ng/dl versus Immuno staining positivity for p63**



**Figure 2: Nodular hyperplasia showing hyperplastic glandular and stromal components (H&E, 100x)**

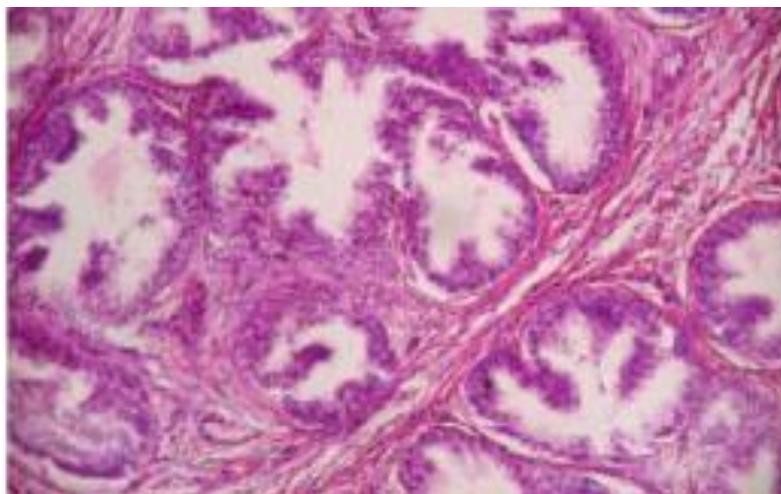


Figure 3: Prostatic adenocarcinoma Gleason's score 3+4=7 (H&E, 100 xs)

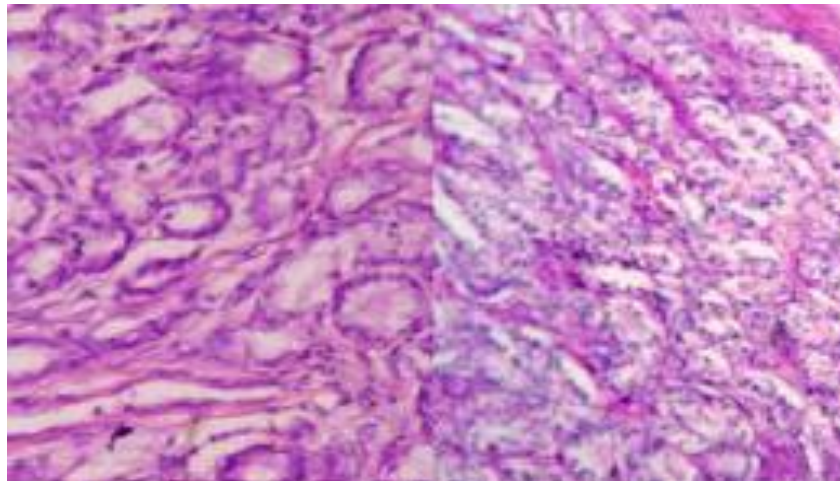


Figure 4: p63 positivity in benign nodular hyperplasia: (IHC 100x)

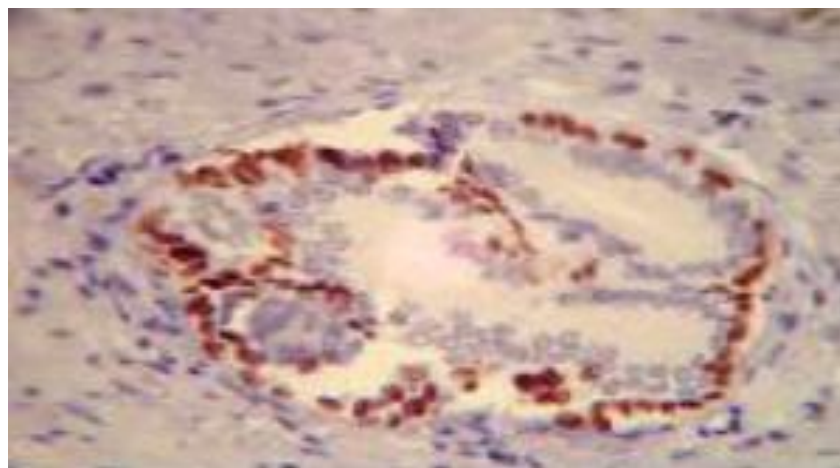


Figure 5: p63 positivity in low grade prostate intraepithelial neoplasm (IHC 100x)

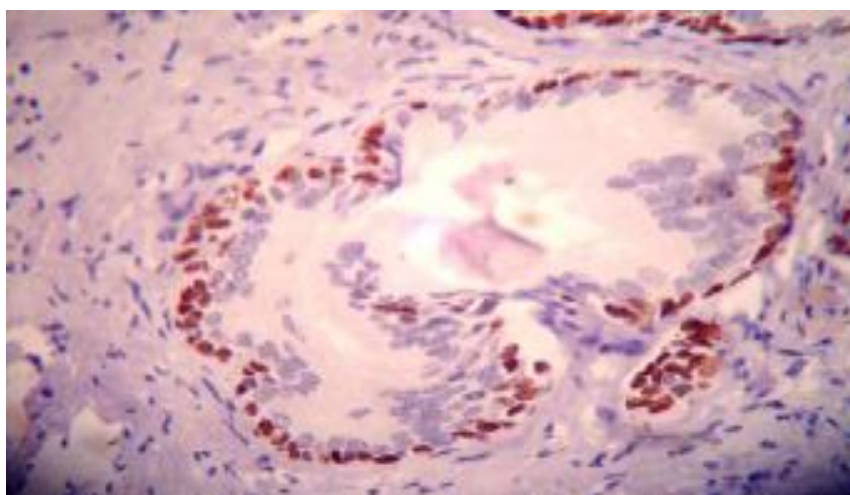
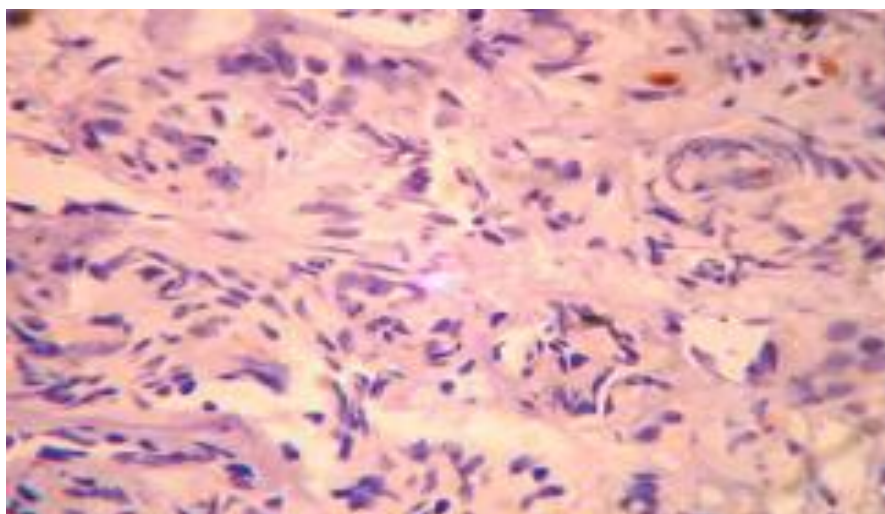


Figure 6: p63 negativity in prostatic carcinoma (IHC 100x)



### CONCLUSION

Benign nodular hyperplasia and Prostatic Adenocarcinoma are diseases of Prostate encountered in the aging population. Screening protocols and awareness programs are important to reduce the morbidity and mortality. p63 immunostaining is very sensitive and specific for the identification of prostatic basal cells of benign glands, with no staining evident in malignant glands. Immunostaining in prostatic biopsy specimens may be more useful in deciding the treatment protocols in all cases with elevated serum PSA levels.

### REFERENCES

- [1] Kumar VL, Majumder PK. *Int Urol Nephrol* 1997;27(3):221-43.
- [2] Bid HK, Konwar R, Singh V. *Indian J Med Sci* 2008; 62:373-4.
- [3] Robbins and Cotran *Pathologic Basis of Disease*, 2010; 8th edition; p.996-1002.
- [4] Manna AK, Pathak S, Gayen P, Sarkar DK, Kundu AK. *Indian J Surg* 2011;73(2):101-6.
- [5] Robert H Young, John R Srigley, Mahul B Arvin, Thomas M Ulbright, Antonio L Cubilla – *Tumours of the prostate gland, seminal vesicles, male urethra and penis*, Armed forces institute of pathology, *Atlas of tumour pathology*, Third series, Fascicle 28.1998; p.289-345.
- [6] Parkin DM, Bray F. *Cancer J Clin* 2005; 55: 747.
- [7] Subathra K, and Sangeetha N. *Int Jf Pharma Bio Sci* 2014;5(2):2014.
- [8] Hameed O, Humphrey PA. *Semin Diagn Pathol* 2005;22(1):88-104.
- [9] Varma M, Jasani B. *Histopathol* 2005;47:1-16.
- [10] Jiang Z, Wuc LC, Woda BA, Iczkowski KA, Chu PG, Tretiakova MS, Young RH, et al . *Histopathol* 2004;45:218-22
- [11] Reiter ER, Dekernion BJ. *Epidemiology, etiology, and prevention of prostate cancer*. In: Walsh, Retik, Vaughan, Wein editors. *Campbell's urology*. 8<sup>th</sup> ed., Philadelphia: WB Saunder's , 2002;p.3003-3024.
- [12] Gritsenko V, Ruban O, Kovalevskaya I, and Pulyaev D. *Res J Pharm Biol Chem Sci* 2013;4(4):683-685.