

# Research Journal of Pharmaceutical, Biological and Chemical Sciences

## A Case Report of Mixed Solid and Cystic Variety of Aneurysmal Bone Cyst of Lateral End of Clavicle

S Kumaravel\*, Joseph Victor<sup>2</sup>, and Ashok Parameshwaran<sup>3</sup>

<sup>1</sup>Professor , Department of Orthopaedic Surgery, Government Thanjavur Medical College, Medical College Road, Thanjavur 613004, Tamil Nadu, India. Orthopedic Surgeon, National Pharma Hospital and Research Institute , Thanjavur 613004, Tamil Nadu, India.

<sup>2</sup>Senior Plastic Surgeon, National Pharma Hospital and Research Institute, Thanjavur 613004, Tamil Nadu, India. Formerly Professor, Department of Plastic surgery, Government Thanjavur Medical College, Medical College Road, Thanjavur 613004

<sup>3</sup>Chief of Laboratory Services Apollo Hospitals, Chennai, Tamil Nadu, India.

### ABSTRACT

In general one percent of tumors of bone occur in the clavicle bone. Uniquely primary benign tumor of this bone is rare and is less common than malignant. Even among malignant tumors occurring in clavicle, only secondaries from other sites of primary malignancies (metastases) are more common. Among bones that are affected by aneurysmal bone cyst (ABC) only 3% occur in clavicle. 4% of Ewing's sarcoma and 2% of hemangiopericytoma occur primarily in the clavicle. ABC is a blood filled multiloculated benign lesion of the bone that is locally destructive. Most (80%) of them occur under age 20 years before physal fusion in both sexes. The tubular long bones and spine are the more affected areas. In literature only 26 cases of ABC of clavicle are reported. We present another case of aneurysmal bone cyst of the clavicle.

**Keywords:** aneurysmal bone, cyst, clavicle

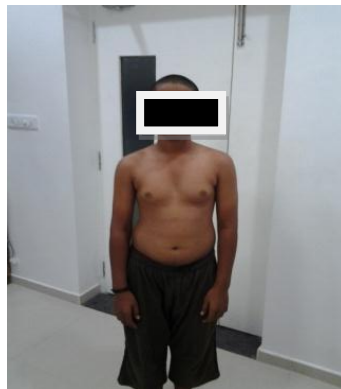*\*Corresponding author*

Email: drskumaravel@gmail.com

## CASE STUDY

A 12 year old male, son of a police man, presented with complaint of sudden pain in the right shoulder 14 days. There was no history of trauma, fall, constitutional symptoms and any other similar swelling in the body. The boy was a known epileptic and had skipped his regular anti epileptic medications for 3 weeks. His father denied any history of recent seizures. His examination revealed that in the lateral third of right clavicle there was an oval; 6 x 4 cm well circumscribed smooth non pulsatile hard swelling felt. The skin over the swelling was normal and free from underlying swelling. (Figures 1 and 2) There was tenderness over the swelling. He did not have any neurological and vascular deficit. Right shoulder movement was normal except restricted at the extremes. His radiograph showed a well defined radiolucent, expansile lesion with thin cortical margins in lateral third of clavicle region. The margins of the swelling were continuous with adjacent normal bone. The central part of the swelling was with visible septa with multiple loculated appearances.

Figure 3. An MRI scan showed an expansible lesion filled with blood. In some sections there was thickening outer end of clavicle to an extent that could be easily mistaken for an acromion. (Figure 4). An FNAC was done but it turned to be inconclusive. Patient was put on anti epileptic medication and assessed for surgery. At operation, the lateral 1/3<sup>rd</sup> of clavicle along with the tumor in toto was excised with adjacent normal bone. The excised specimen was similar in appearance to an acromion. Histopathological examination confirmed our diagnosis as Aneurysmal bone cyst. A cut section revealed the blood filled cavity. Figure 5. Two years after the surgery, the boy had no complaints; he had complete healing of the operated wound with a non tender, smooth, healed scar. (figures 6 and 7) He was able to do all range of movements of his right shoulder (figures 8-10). There was no evidence of a clinical or radiological recurrence. (Figure 11).



**Figure .1 Preoperative clinical photograph showing the swelling in the right clavicular region in its lateral half.**

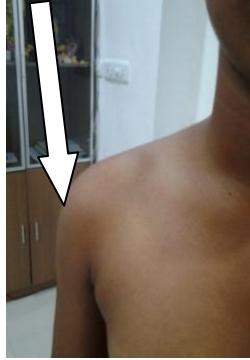

Figure 2. A closer view of the patient with swelling seen at the lateral end of the right clavicle.(marked by arrow)

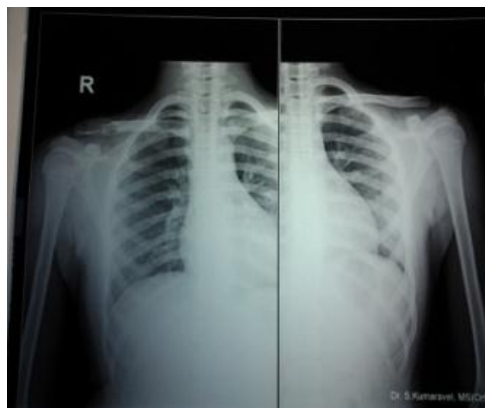

Figure 3. Radiograph showing a lesion involving the lateral aspect of the right clavicle with expansion of the cortex. The unaffected left clavicle is also shown for comparison.

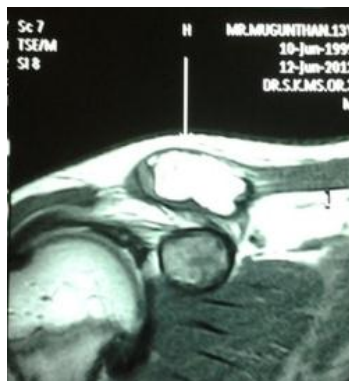

Figure 4. Magnetic Resonance Imaging (MRI) an expansile lesion with intact cortex of the clavicle.

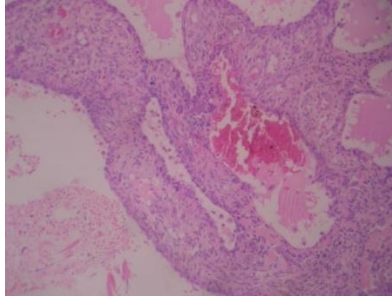


Figure 5. Photomicrograph showed cartilage, trabeculae of bone, bone marrow along with a lesion exhibiting cystic as well as solid areas. The cystic areas show blood in the lumen with no specific lining. The solid areas are composed of oval to spindle shaped bland cells with osteoclasts with reactive osteoid formation.

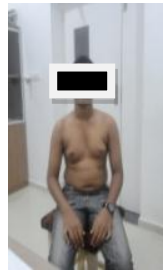

Figure 6. Patient sitting after 2 year of surgery.

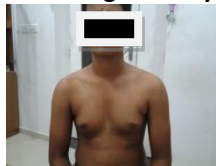

Figure 7 A closer view showing the completely healed scar in his right clavicular region



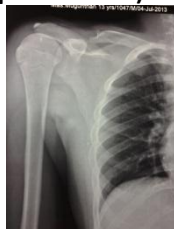Figure 8. Patient doing extension of both shoulders comfortably after two years of surgery.



Figure 9. Patient doing abduction of both shoulders comfortably after 2 years of surgery.



**Figure 10. Patient doing flexion of the right (operated side) shoulder comfortably after two years of surgery.**



**Figure 11. Radiograph of the right shoulder after two years of surgery showing no recurrence.**

### DISCUSSION

The other areas where ABC can occur are tibia (15%), spine (14%), femur (13%), humerus (9%), pelvis (8%), ulna (4%), while bones like the ribs, scapula and skull (2%) accounting for less than two percentage. <sup>1</sup> Both the ends of clavicle can be involved in ABC. it presents under 20 years as a gradually enlarging painless bony swelling with eccentric position in the bone [1]. It can sometimes produce painful swelling and can compress the nearby structures. Radiologically they are seen with dilated shell of sub-periosteal bone. Hence only the name (local dilatation) 'aneurysmal' MRI in these cases shows the expansile-aneurysmal nature of the bone cortex [2]. Histologically, ABCs are characterized by cavernous blood - filled cysts. Though non-neoplastic, it is fast growing tumor, damage of bone cortex with expansion into the soft tissue. These point to the necessity for a radical therapy. ABC is an uncommon benign tumor for clavicle. Clavicle accounts for 3% of all aneurysmal bone cyst in series of 465 cases [3].

In contrast to the regular blood filled variety, Pamechaetal reported a rare solid variety of Aneurysmal bone cyst also called as extragnathic giant cell reparative granuloma with good prognosis [3] Our case had both cystic and solid areas. The absence of Giant cells in our patient's histopathology rules out a primary giant cell tumour with secondary formation of ABC [4].

In general the accepted treatment is wide excision. This is because the recurrence rate at 5 year period is 42% if curettage is used [1]. Such recurrences usually happen within six months of surgery and not usual after 2 years [2] our patient had no recurrence at two years follow up and hence from available data is expected not to recur. If the tumour is in inaccessible areas then radiotherapy is used. [3] A certain differential diagnoses must be borne in mind in dealing with an ABC; they are the giant cell tumor, chondromyxoid fibroma and telangiectatic osteosarcoma. The giant cell tumour occur after physeal closure is less polycystic and is less destructive than ABC <sup>2</sup> In case of telangiectatic osteosarcoma and Chondromyxoid fibroma, the clinical and radiological features are the same . Hence only a histopathology can differentiate



them. [2] Smith et al reported 58 clavicle tumours (30 malignant and 28 benign) over a period of 50 years. Six (10%) of them had aneurysmal bone cysts of the clavicle. [2]

Histologically, aneurysmal bone cysts are characterized by cavernous blood - filled cysts. They do not metastasize. They grow rapidly destroying the bone and invade the soft tissue. Thus, in spite of them being non neoplastic, they should be treated aggressively. As already told simple curettage and grafting results in a high recurrence and hence a wide excision is preferred especially when the host bone is dispensable like fibula or clavicle. [1, 2] In surgically inaccessible places adjuvant radiotherapy is useful [2, 3] sometimes as in centres with interventional radiologist, embolization of the feeding vessel can reduce the vascularity of the ABC. This is especially when the ABC is in spine or pelvis. In a rare case report, a large ABC was treated with total claviclectomy with good result. [2]

### CONCLUSION

Thus when one confronts a clavicular mass, the message is careful examination and radiological assessment with X-rays and MRI should be done. The examination should end with a careful histopathology. This is because secondaries are more common than primary and in primary malignant tumours are more common.

### REFERENCES

- [1] Resnick D. Diagnosis of bone and Joint disorders 4th edition, W.B. Saunders com. 4037-4049
- [2] Chadha M, Singh AP. Can J Surg 2008; 51(2): E32–E33.
- [3] Pamecha C, Patel JG, Patel LN, Patel PR. Indian J Radiol Imaging 2004;14:179-80.
- [4] Gilbert NF, Deavers MT, Madewell JE, Lewis VO. Clin Orthop Relat Res 2008;466(12): 3158–3162.