

Research Journal of Pharmaceutical, Biological and Chemical Sciences

A Method of Treating Chronic Limb Ischemia Mononuclear Fraction of Autologous Bone Marrow in the Experiment.

Anzhelika Orlova*, Elena Artyushkova , and Boris Sukovatyh.

Kursk State Medical University, Russian Federation, Kursk, Karl-Marks, 3, 305041.

ABSTRACT

The article presents the results of autologous mononuclear fraction of bone marrow in laboratory Wistar rats on a background of creating chronic limb ischemia by excision of the main vessel, including the femoral artery, popliteal artery and initial parts of the leg arteries. Sampling was carried out from the bone marrow of the femur of the animal. Effusion double subjected to centrifugation, followed by isolation of the mononuclear fraction of bone marrow by the method of Boyum. The mononuclear fraction of bone marrow autologous 4×10^6 cells in a volume of 200 microliter were injected into the ischemic limb of the two points, in each of which 100 microliter: 1) paravazalno directly below the inguinal ligament at the level of the sacroiliac joint in the area of the anatomical location of collaterals in the projection of the internal iliac artery and its branches; 2) intramuscularly in gastrocnemius muscle anterior-lateral surface of the middle third of the leg. Assessment of the level of microcirculation in experimental animals after treatment of limb ischemia the bone marrow mononuclear fraction showed a significant increase in blood flow compared with the control. Proposed method of treating pathogenically justified and can be recommended for use in clinical practice in the treatment of patients with chronic obliterating diseases of lower limb arteries.

Keywords: chronic limb ischemia, transplantation of autologous mononuclear fraction of bone marrow cell therapy, angiogenesis, chronic obliterating diseases of lower limb arteries.

**Corresponding author*

INTRODUCTION

Chronic obliterating diseases of lower limb arteries occur at an average of 2-3% of the population, and the frequency of their age increases, reaching the seventh decade of life 5-7% [1]. Disease steadily progresses, worsening the results of conservative and surgical treatment, leading to early disability. The frequency of amputations at chronic obliterating diseases of lower limb arteries caused by ischemia ranges from 16-46 per 100,000 population per year. Treatment of chronic obliterating diseases of lower limb arteries today is one of the most difficult issues of angiology [2]. According to domestic and foreign authors 40% of patients suffering from vascular disease are peripheral lesions form of the main arteries [3, 4]. At the moment patients with chronic obliterating diseases of lower limb arteries preferred revascularization direct methods, which include various types of prosthetic bypass or peripheral arteries. Simultaneously with the development of methods and reconstructive surgery on the arteries, attention has been paid to the development of ways to improve microcirculation in ischemic tissues by stimulating neoangiogenesis [5, 6]. In regenerative cell therapy using bone marrow stem cells by virtue of their pluripotent. However, methods for isolating a pool of pure bone marrow stem cells are too expensive. Stem cells (hematopoietic and mesenchyme) contained the mononuclear cell fraction in bone marrow. With multipotent properties of these cells can contribute to the replacement of tissue defects and neoangiogenesis. In addition, lymphoid cells of this fraction due to their morphogenetic abilities can participate in the process of reducing the regeneration of damaged organs and tissues [7, 8]. This makes the demand for bone marrow mononuclear cells in clinical medicine.

The aim of the work is the experimental evaluation of the effectiveness of using autologous mononuclear fraction of bone marrow for the treatment of chronic limb ischemia.

METHODS

Experiments were carried out on white male rats of Wistar weighing 300-350g.

Chronic limb ischemia simulated under anesthesia (chloralhydrate 300 mg / kg) by ligation of the femoral artery in the place of its origin (under the inguinal ligament) to remove the section of the main vessel, including the femoral, popliteal artery and the initial parts of the leg arteries [9]. The animals were evaluated microcirculation level in the muscles right lower hind limb using a laser Doppler flowmeter Biopac-systems MP-100 sensor and TSD-144 (USA), as well as the dynamics of these indicators at 10, 21 and 28 days after the operation simulation of chronic ischemia limb. Recording was carried out in the microcirculatory level at five points (the middle length of the muscle, at the point 3-5 mm above and below the first lateral and medial). From these five values gives averages, which were added to the protocol and was taken as the level of the microcirculation in the shin muscles in the animal. 10 of these values shall be averaged, which was taken as the level of the microcirculation in the group of animals in this study period. General view of the microcirculation level recorded curve is shown in Fig. 1.

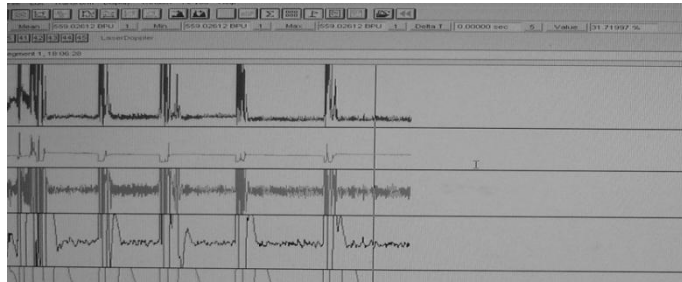


Figure 1: General view curve microcirculation level recorded at five points. Sharp graphics amplitude between points associated with the "Scan air" as they move from one point to another.

Registration microcirculation level performed in intact rats in groups with modeling limb ischemia and in groups during the treatment of limb ischemia autologous bone marrow mononuclear fraction. Last prepared immediately before the introduction of the following technologies: on the seventh day after the operation simulation of limb ischemia in rats anesthetized with chloralhydrate on the contralateral limb palpated femoral-tibial joint is formed by the lateral and medial condyle of the femur and tibia, fixed it with one hand in the position of flexion, and on the other hand take the needle with diameter of 20G, connected to a syringe containing 2500 U heparin, diluted with 0.9% NaCl at a ratio of 1:1 in 1 ml volume and after readjustment 70% ethanol percutaneously through the articular cartilage underneath the patella meniscus performed puncture medullary cavity. Bone marrow was aspirated into the syringe through the needle into translational movements back and forth of the cavity in a volume of 1 to 1.5 ml. Then autologous mononuclear fraction of bone marrow were isolated by the method of Boyum [10] at a dose of 4×10^6 cells in a volume of 200 microliter and injected into the ischemic limb of the two points, in each of which 100 microliter: 1) paravazalno directly below the inguinal ligament at the level of the sacroiliac joint in the area of the anatomical location of collaterals in the projection of the internal iliac artery and its branches; 2) intramuscularly in gastrocnemius muscle at anterior-lateral surface of the middle third of the tibia.

Statistical processing of data was calculated averages of the values obtained (M), the arithmetic mean error (m). To assess the significance of differences was used Student's t-test. Differences were considered significant at $p < 0.05$. Statistical calculations were performed using the program Microsoft Excel 7.0, Statistic (v.6.0).

The Main Part

The animals were divided into three groups: intact, control and experimental, each of which included 30 rats. In the control group of animals after modeling limb ischemia no treatment. In the experimental group of rats was performed cell therapy mononuclear fraction of autologous bone marrow after the establishment of limb ischemia.

In intact animals assessed level of microcirculation in the shin muscles of the right hind limb 10, 21 and 28 days by laser Doppler flowmetry (LDF). The calculated mean value of the microcirculation level in this group of animals was taken as the "norm" and amounted to $535, 22 \pm 37, 1$ perfusion units (p.u.). Error of the mean (37.1) does not exceed 10% of the absolute values (53, 52), indicating that sufficient number of observation units in the group.

In rats, the experimental group treated mononuclear fraction of autologous bone marrow starts on the seventh day after surgery. According to F. Judah (1998) morphological compensation mechanisms limb ischemia - angiogenesis - included an average of 7 days after surgery simulation. Over this period, mobilized all preexisting compensatory reserves of the animal; further changes in the state of blood circulation in the limbs can occur only through the intervention of outside [11, 12].

In our experiment, the animals were derived by an overdose of chloral hydrate anesthesia on 10, 21 and 28 days. Before breeding of experimental rats control and experimental groups evaluated the dynamics of clinical and microcirculatory parameters in the simulation of limb ischemia at different stages.

Despite a fairly aggressive model of experimental pathology and development of acute severe limb ischemia, after 3-4 days was observed relative compensation arterial insufficiency: limb movement included in the act, disappear or decrease ischemic edema. In parallel with the passage of time, there are signs emerging chronic limb ischemia, which was characterized by the presence of pathognomonic symptoms as intermittent claudication, trophic disorders in the distal parts of the limbs - arterial sores. In some cases a dry gangrene of the toes, which is characteristic for the syndrome of chronic arterial insufficiency. In some cases, we observed amputation of limb (obviously developed dry gangrene with clear demarcation and subsequent rejection of necrotic areas). Thus, in rats on a background of experimental pathology formed signs of chronic limb ischemia similar to those observed in patients with chronic obliterating diseases of lower limb arteries (Table 1).

Table 1: The frequency of symptoms of experimental limb ischemia 5-7 days after surgery

Symptoms experimental limb ischemia	Absolute number	Percentage (%)
Pain (indirect signs)	59	98
Limited participation limb in moving	54	90
"Intermittent claudication"	53	88
Hyperemia skin limb	39	65
Dry gangrene of fingers, the foot	3	5
Arterial sores	2	3,3
ischemic edema	2	3,3
Dry gangrene of leg, amputation	4	6,6

The table shows that examination of the majority of animals reported the presence of pain, flushing of the skin of leg and foot, a symptom of "intermittent claudication" limited participation in the movement of limbs.

The results of assessing the level of microcirculation in rats intact, the control and experimental groups with modeling ischemia right hind limb are presented in the table (Table 2).

Table 2: Evolution of the microcirculation in the experimental groups of animals (M + m in absolute units perfusion, n = 10)

Groups of animals	10 day	21 day	28 day
Intact	541,23±18,41	546,22±16,83	555,24±19,73
Control	209,20±6,45*	312,08±14,03*	369,56±14,64*
Experimental group	441,28±23,10#	579.56±38.83#	728,32±36,43#

Note: * - with p <0, 05 as compared to the intact group (normal);

- When p <0, 05 compared with the control group

The table shows that compared with the group of intact animals, the level of microcirculation after surgery simulation of limb ischemia in the control group decreased sharply and quickly, and then slowly reduced, however, up to 28 days inclusive remains significantly below the normal values.

In the experimental group of rats treated with autologous mononuclear fraction of bone marrow, the level of microcirculation compared with the intact group of animals on day 21 was higher than 6.1% by Day 28 - 31.2%; compared with the control group - day 10 increased by 111% at day 21, 85.7% on day 28 - 97%.

Clear positive trend can be traced to differences at all stages compared with the control. As seen from table 2, against the background of cellular therapy differences between experimental and control groups appear even on day 10 and on day 21 and 28 become higher than even the group of intact rats, indicating that early disclosure previously operating under the influence of mononuclear collaterals fraction of autologous bone marrow and increased blood flow to them from the proximal to the distal extremity.

CONCLUSION

Thus, the results of the experimental study indicate that the administration of autologous mononuclear fraction of bone marrow in a dose of 4×10^6 cells in a volume of 200 microliter in the ischemic limb of two points, each of which 100 microliter : paravazalno directly below the inguinal ligament at the level of the sacroiliac joint in the area of the anatomical location of collaterals in the projection of the internal iliac artery and its branches and intramuscularly in gastrocnemius muscle at anterior-lateral surface of the middle third of the tibia allows to activate the correction of chronic limb ischemia , which is detected by laser Doppler flowmetry.

Findings

- Developed a method of introducing the resulting mononuclear fraction of bone marrow autologous 4×10^6 cells in a volume of 200 microliter in the ischemic limb of the two points, in each of which 100 microliter: 1) paravazalno directly below the inguinal ligament on the level of sacro - iliac joint in the zone of anatomical location of the collateral in the projection of the internal iliac artery and its branches; 2) intramuscularly in the gastrocnemius muscle at anterior-lateral surface of the middle third of the tibia allows activating the collateral circulation through the provision of

spare functional collateral arteries and increase blood flow from the proximal to the distal extremity.

- When treating experimental chronic limb ischemia mononuclear fraction of autologous bone marrow microcirculation level, estimated by laser Doppler flowmetry, compared with a group of intact animals increased by 21 days to 6.1% at 28 days - 31.2%; compared with the control group - day 10 increased by 111% at day 21- 85.7%, on day 28 - 97%.
- Data obtained during the experimental studies in rats, allow us to hope that the method of stimulation of collateral circulation of the mononuclear fraction of autologous bone marrow in the future take its permanent place in the complex treatment of angiosurgical patients.

REFERENCES

- [1] Shevchenko YL. Medico-biological and physiological bases of cellular technology in cardiovascular surgery /Y.L. Shevchenko.- St. Petersburg.: Nauka, 2006. – 287 pp.
- [2] Savelyev VS, VM Koshkin. Medical, 1997. – 160 pp.
- [3] Davydenko VV. J Surgery 2000;4:117-120.
- [4] Arshinov AV. Angiol Vasc Surg 2011;1:35-41.
- [5] Al-Khaldi A. Ann Thorac Surg 2003;75(1):204-209.
- [6] Boqueria LA. Thoracic Cardiovas Surg 2000;2:57-61.
- [7] T Asahara. EMBO J 1999;18:3964-3972.
- [8] Sugano C. Circulation 2004;109:797-802.
- [9] BS Sukovatykh, AY Orlova, MV Pokrovsky, EB Artyushkova. Disc Invent 2010;18:35.
- [10] Boyum A. Scand J Clin Lab Investig 1968;21(Suppl.97):1-9
- [11] Folkman J. Circulation 1998;97:1108-1110.
- [12] Iba O. Circulation 2002;106:2019-2025.